

# Månedens case

Sjællands Universitetshospital Patologiafdelingen - Næstved

**Klinisk info:**

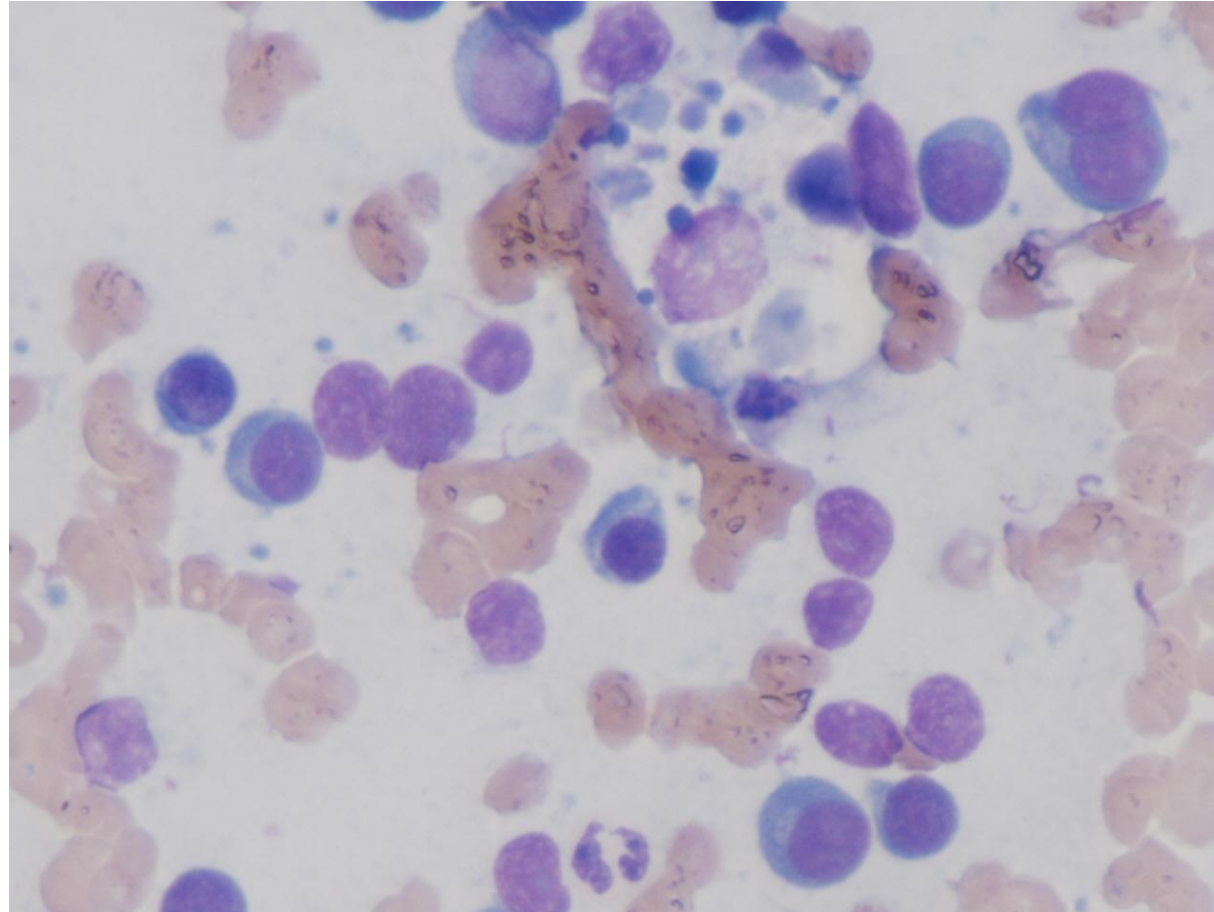
52 årig mand med 20 cm infiltrat i venstre overlap. Dialyse behandlet.

**Bronkoskopi:**

Materiale fra EBUS, bronkialsekret og TTNA ve. overlap

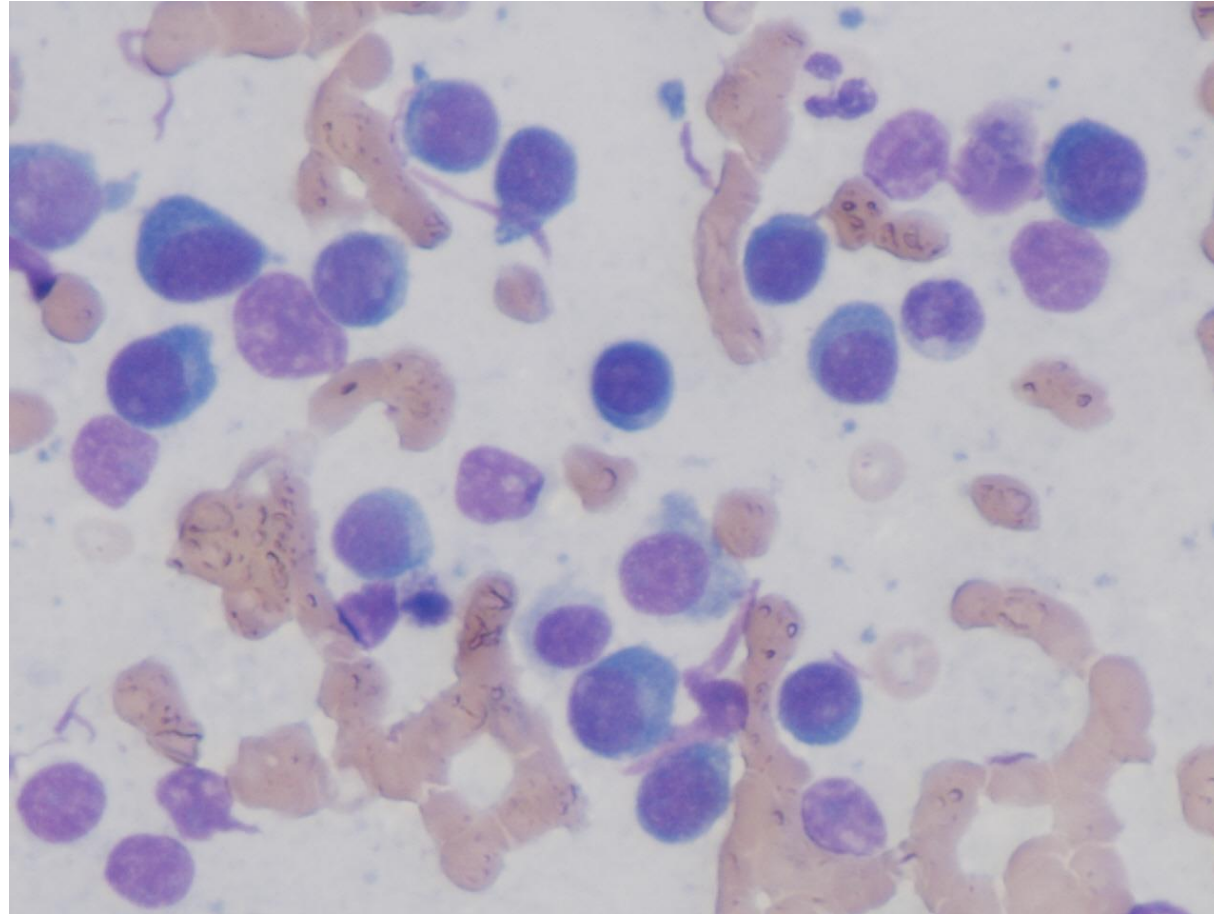
# TTNA-rtg venstre overlap

MGG udstrykning 600 x forstr.



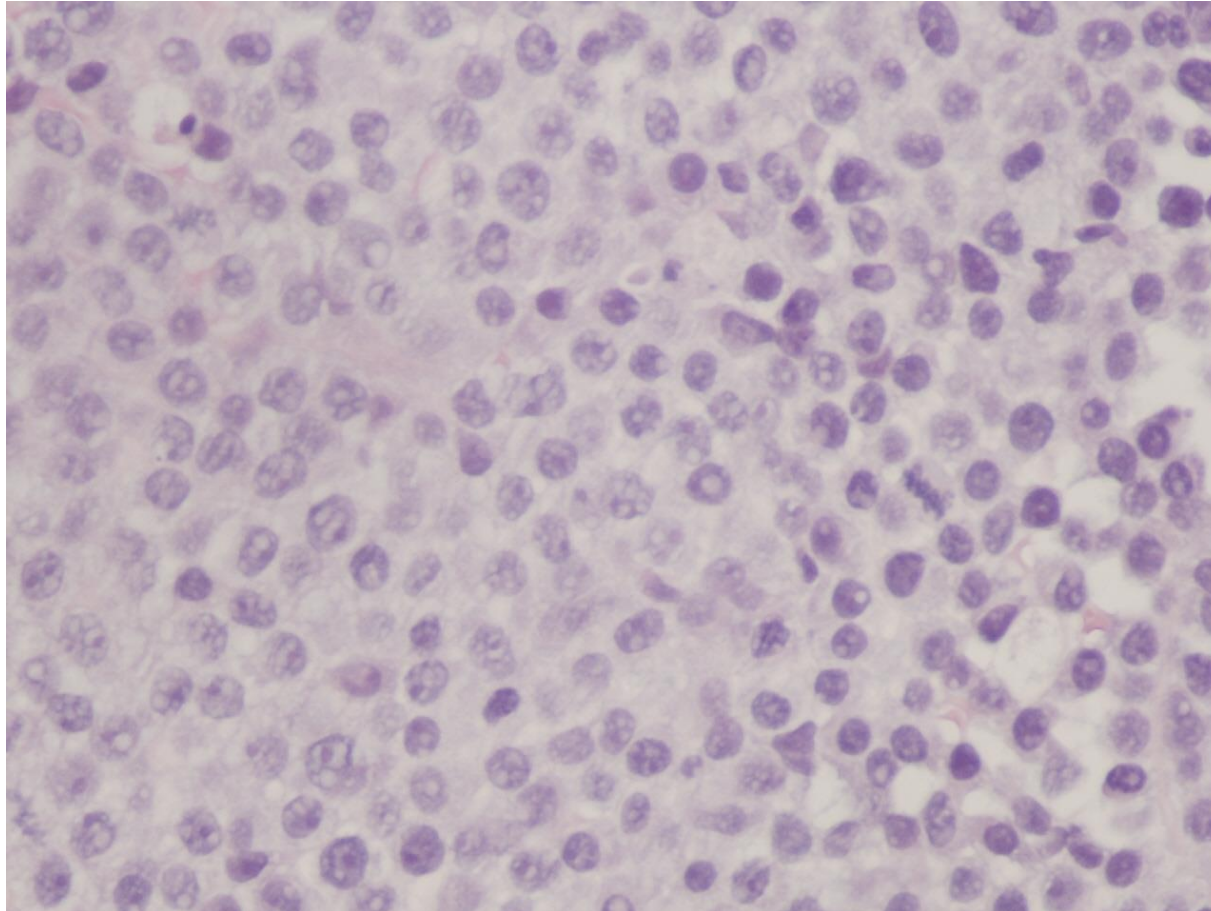
# TTNA-rtg venstre overlap

MGG udstrygning 600 x forstr.



# TTNA-rtg venstre overlap

Koagel HE 600 x forstr.

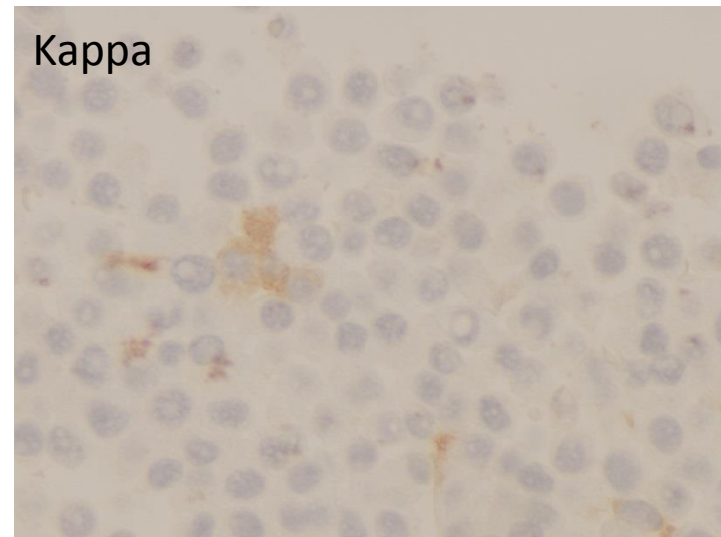
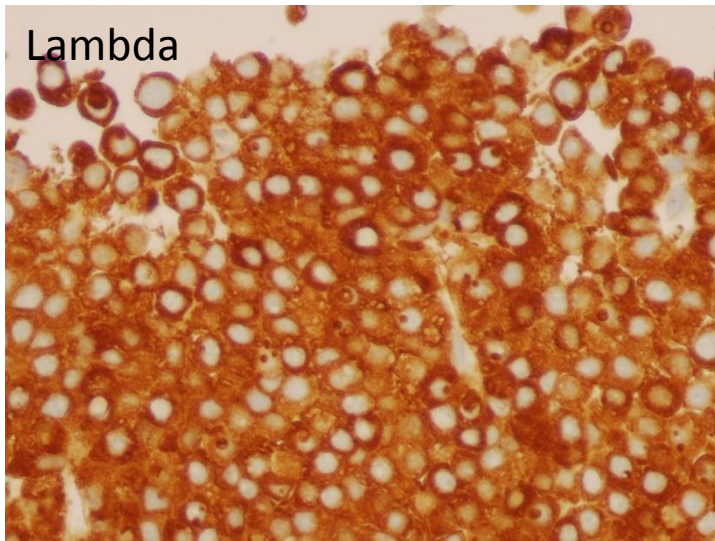
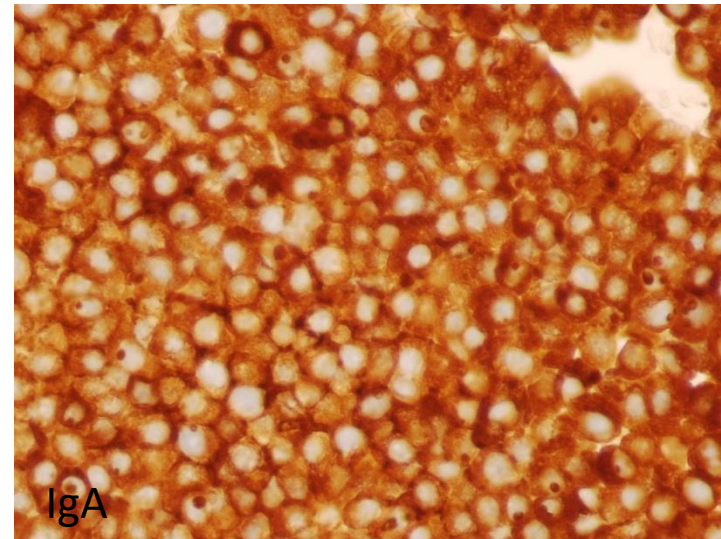
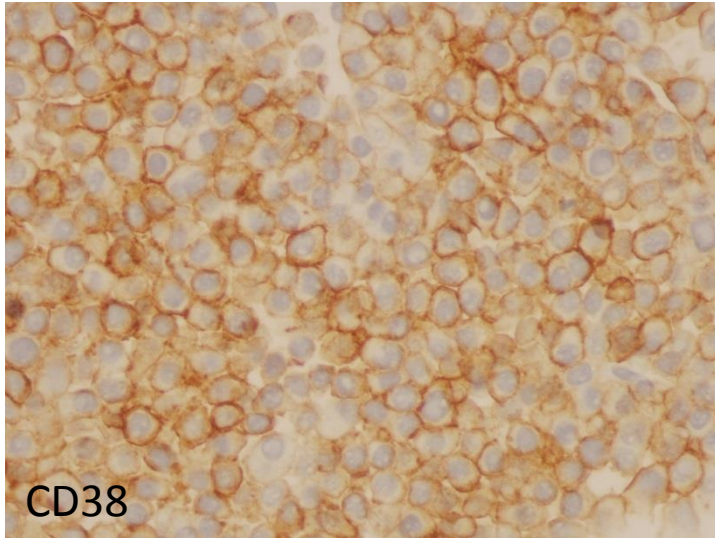


Diagnose?

# Immunpanel:

Positiv: LCA, CD138, CD38, Lambda, IgA

Negativ: Kappa, IgG, IgM, CD19, CD20, CD5, CD10 og CD23



# Diagnose med opfølgning

Ekstraossøst plasmacytom:

- Mikroskopi giver mistanke om malignt lymfom eller plasmocytom og patient bør undersøges for om der tillige er myelomatose.

Opfølgning:

- Myelomatose: FISH har påvist gain af 1q og del 13q14