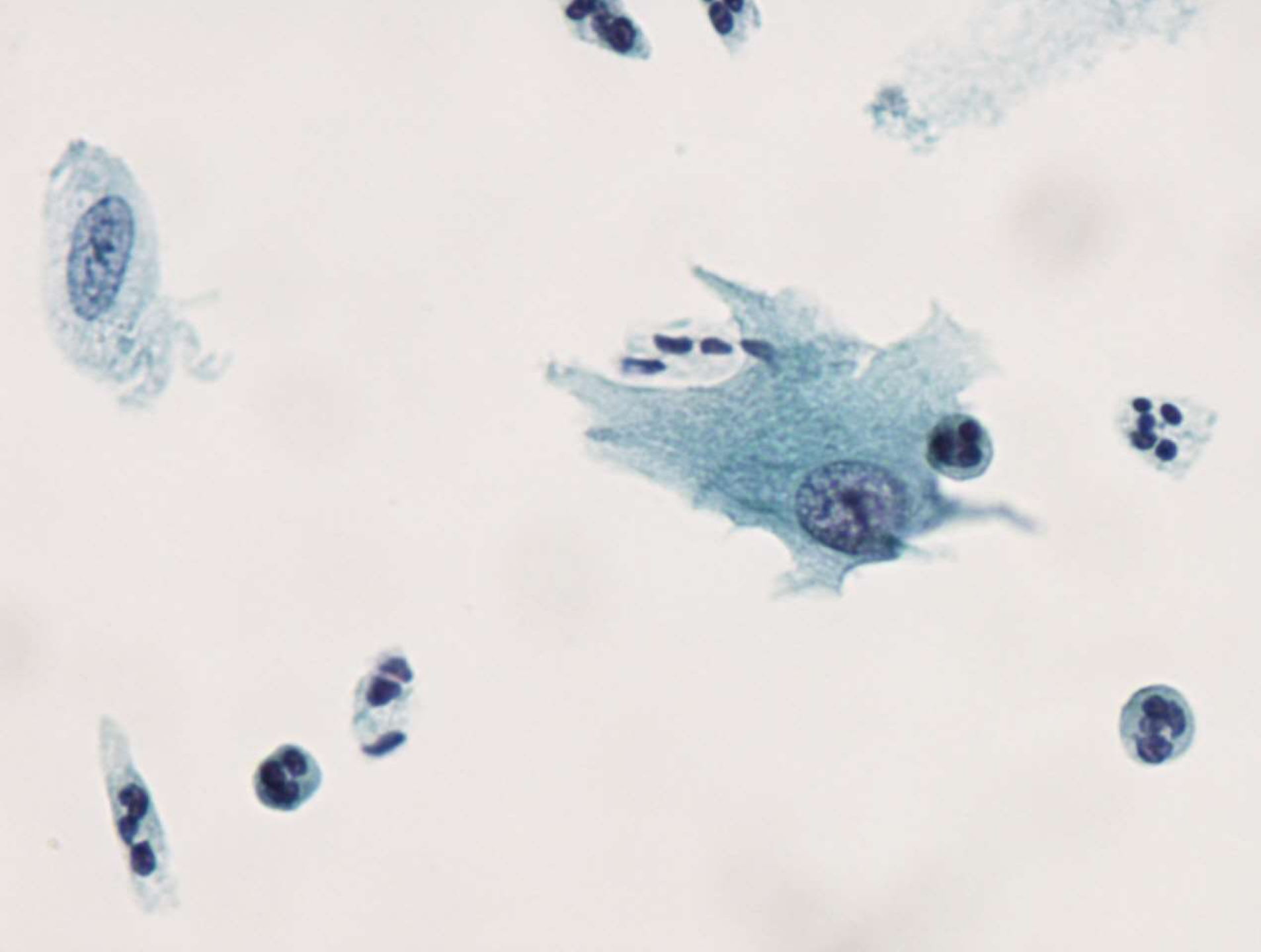


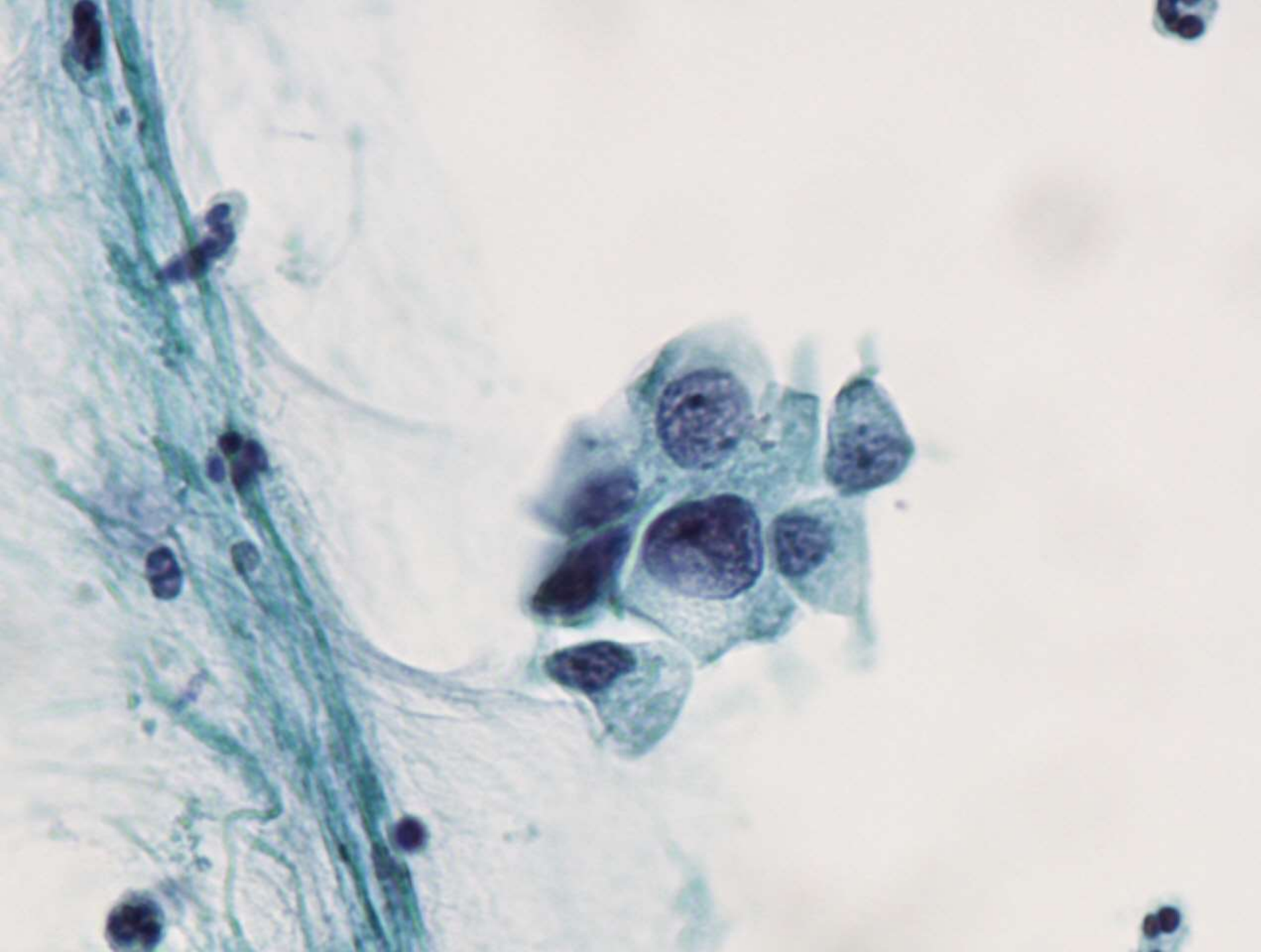
# Cervixcytologi case

Kliniske oplysninger:

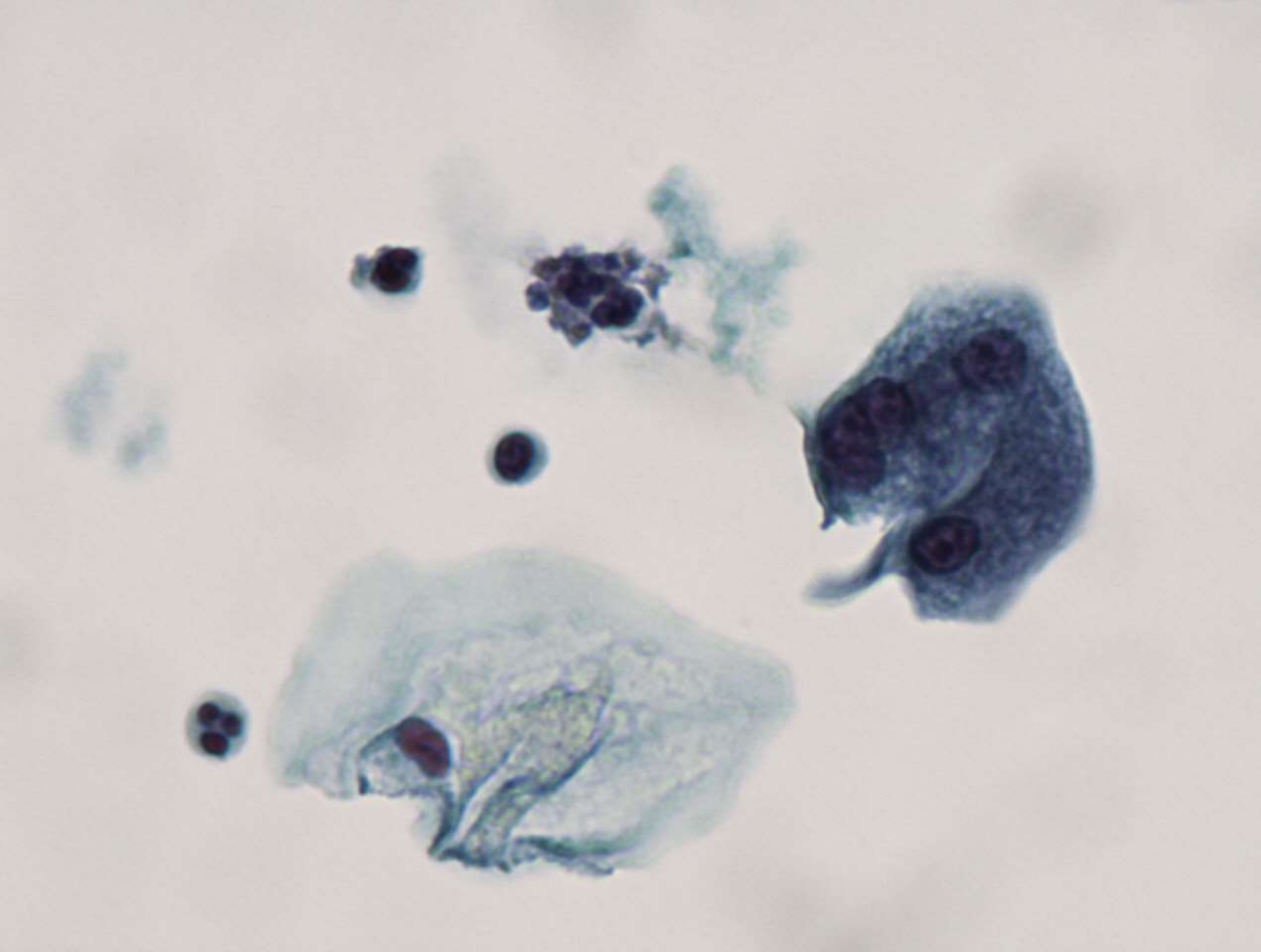
30 årig kvinde gravid uge 14, med polypos, let blødende portio



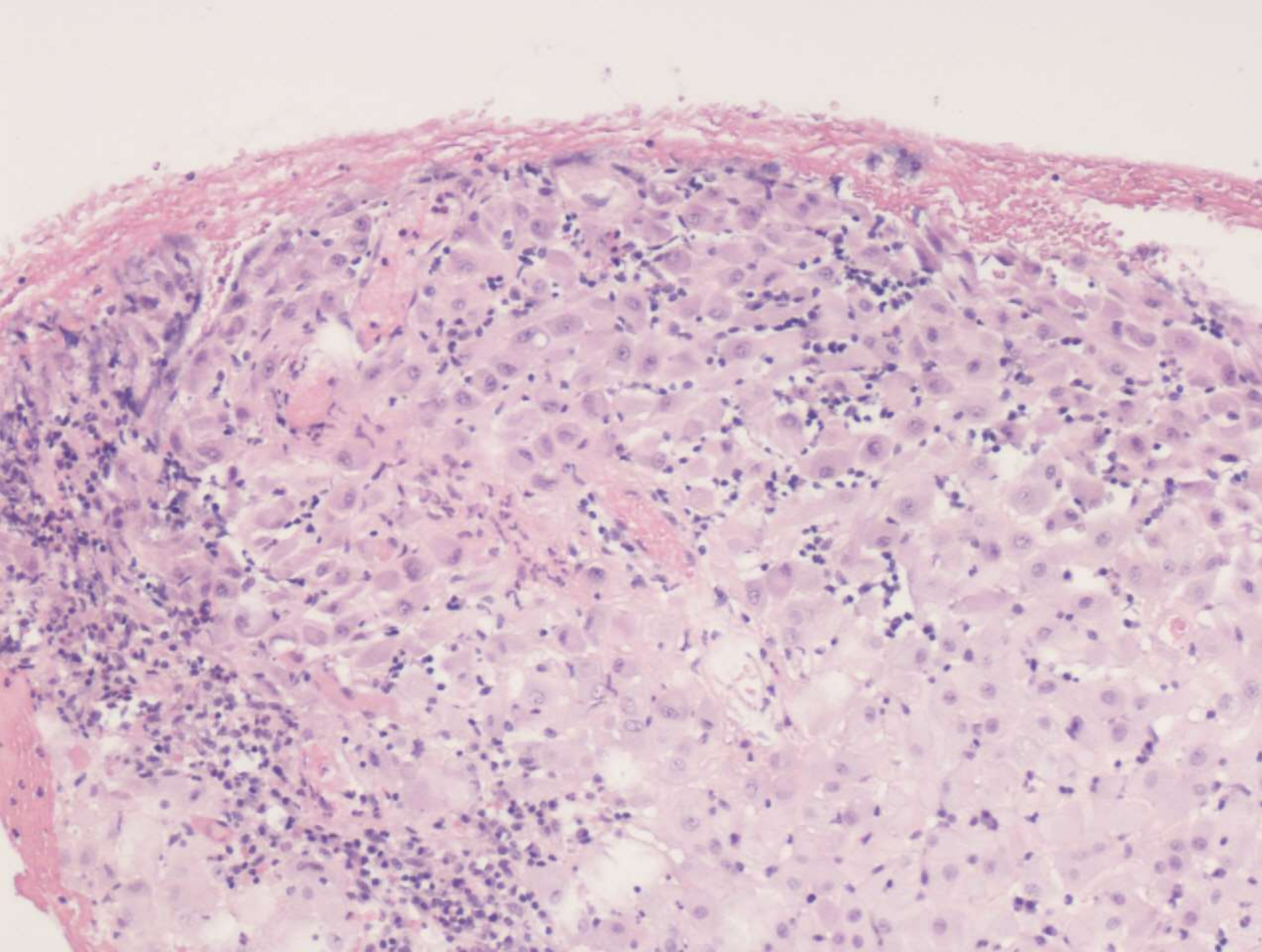
BD SurePath pap.  
600 x forstr.



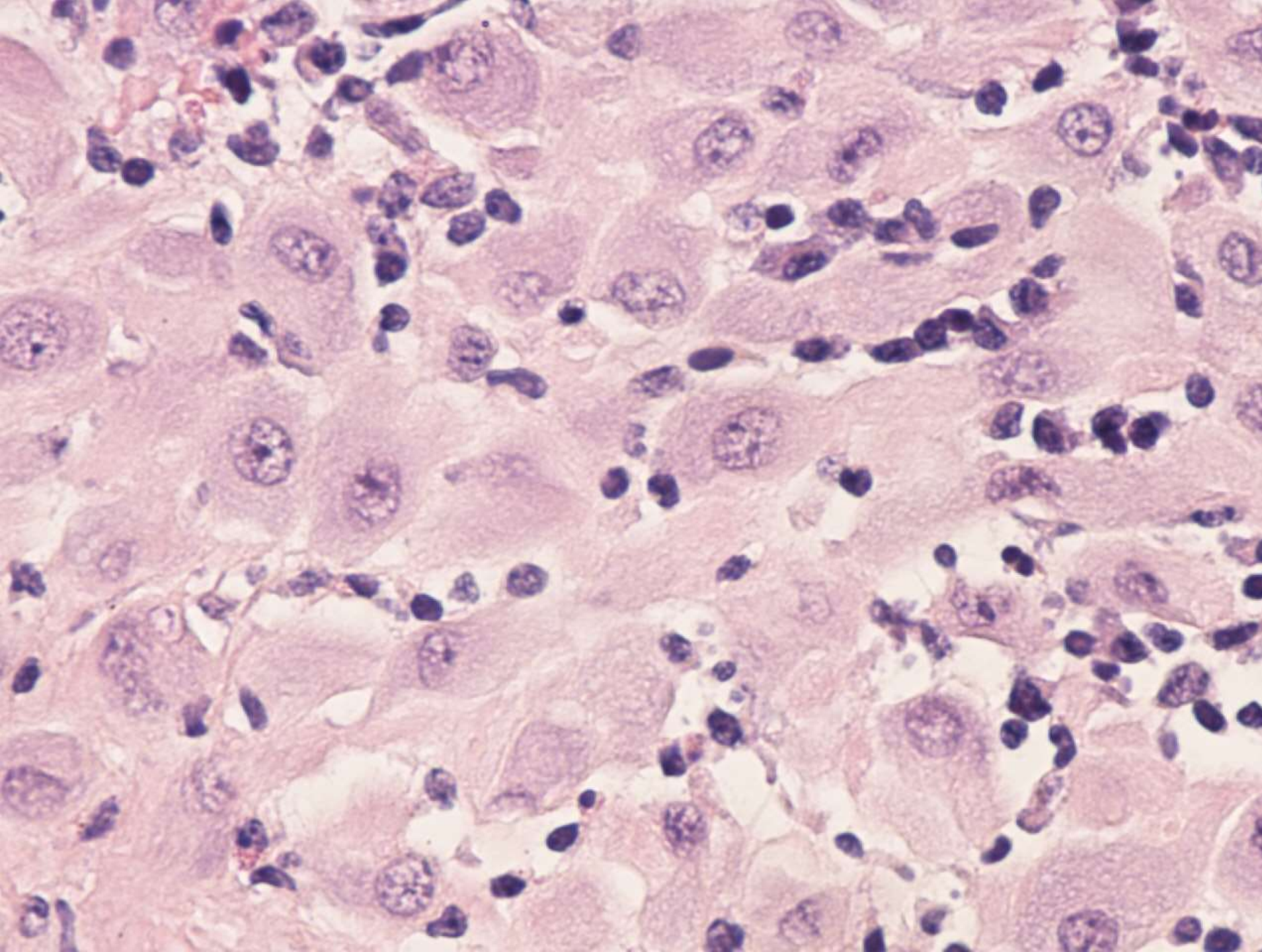
BD SurePath pap.  
600 x forstr.



BD SurePath pap.  
600 x forstr.



HE  
100 x forstørrelse



HE  
400 x forstørrelse

# Diagnose

**Cytologi:** Normale celler

Kommentar: deciduallignende celler

**Histologi:** Normalt væv, decidua