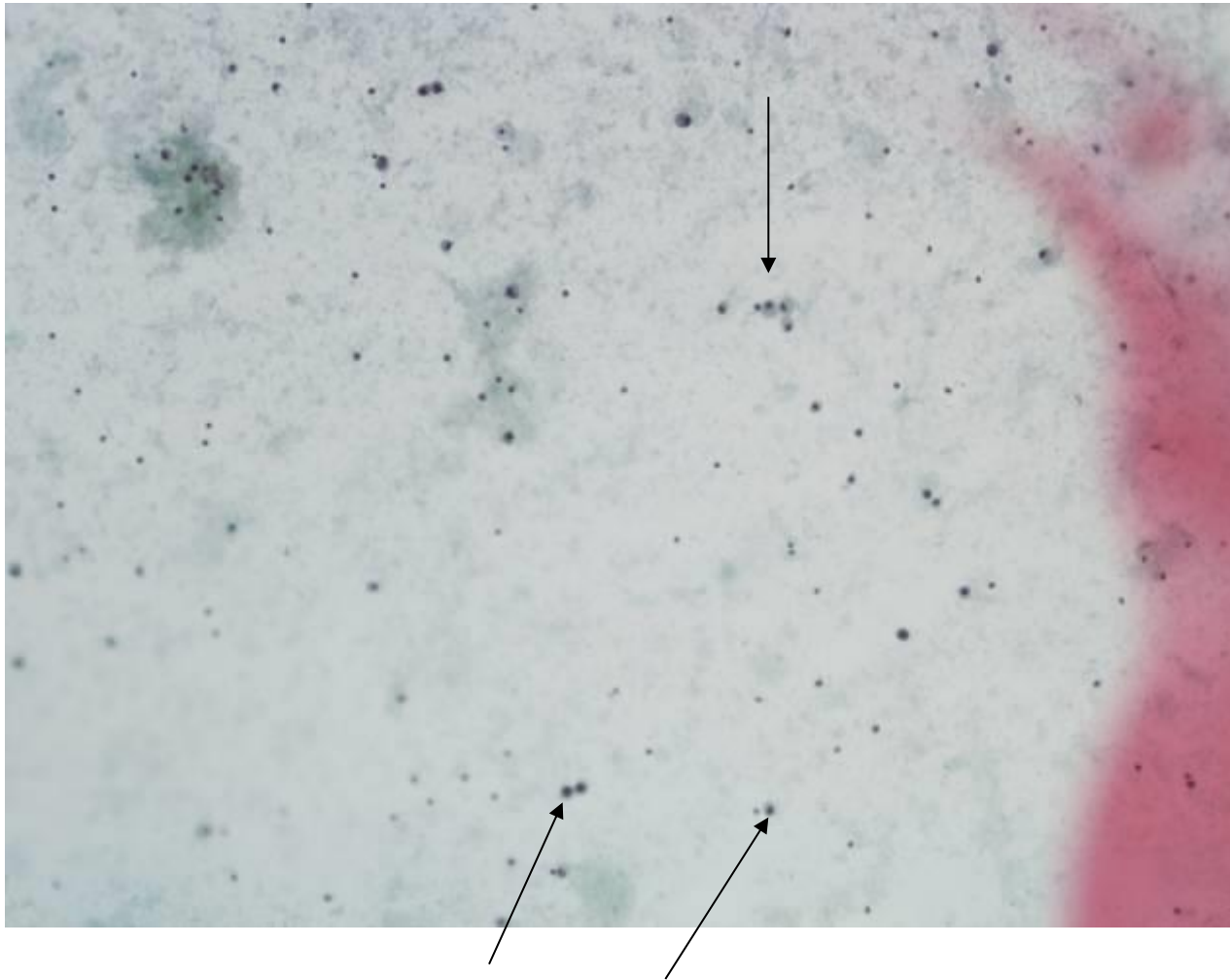


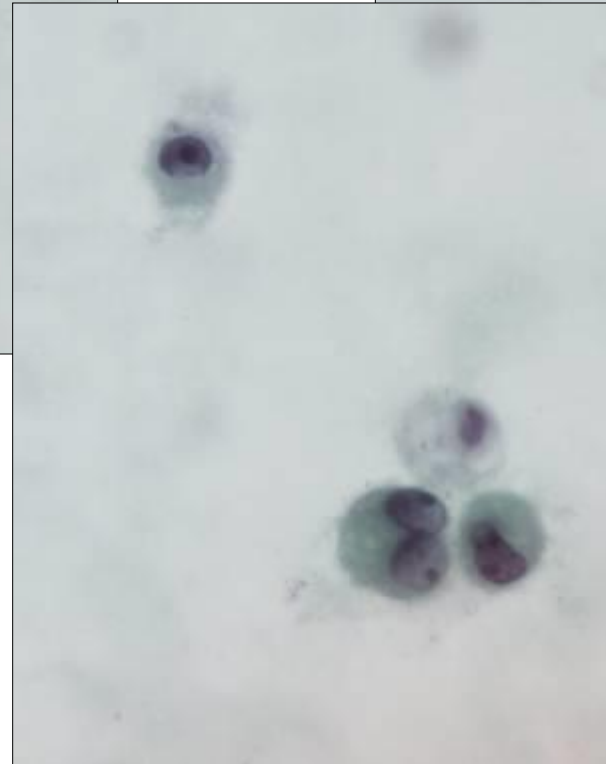
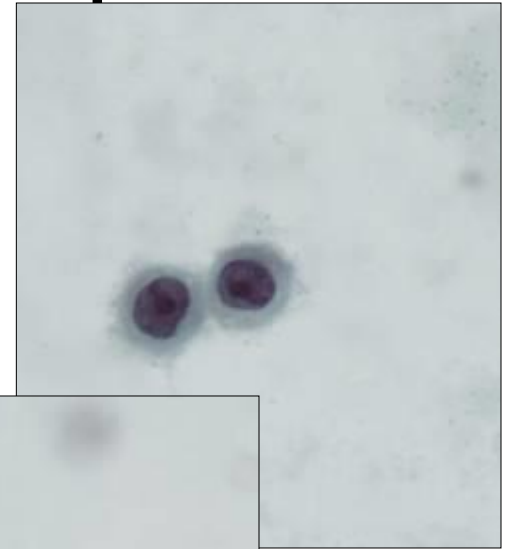
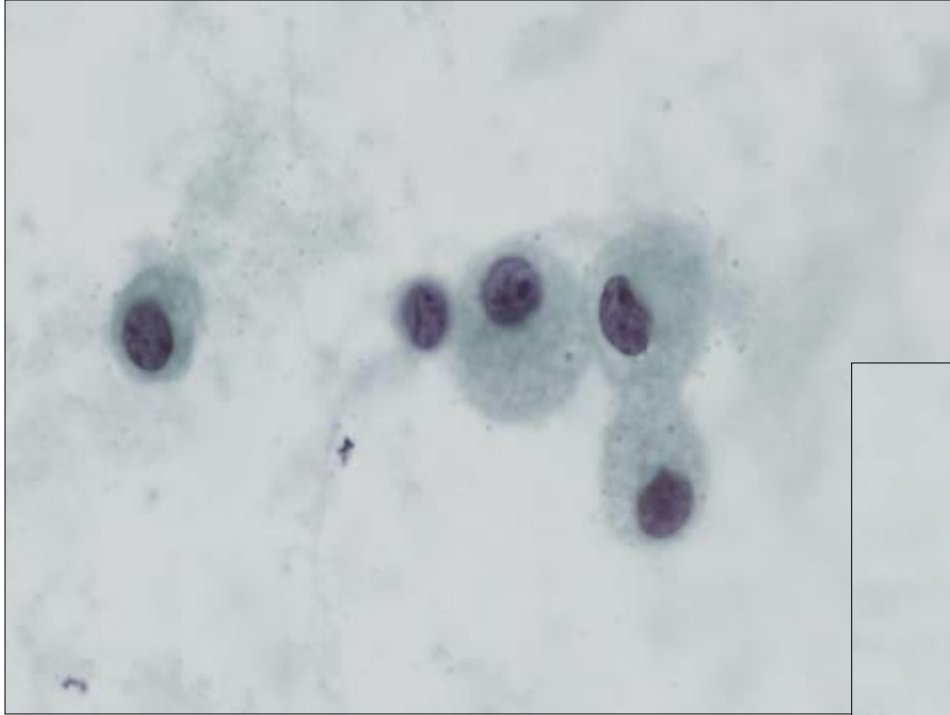Ascitesvæske

Ascites kvinde 77år

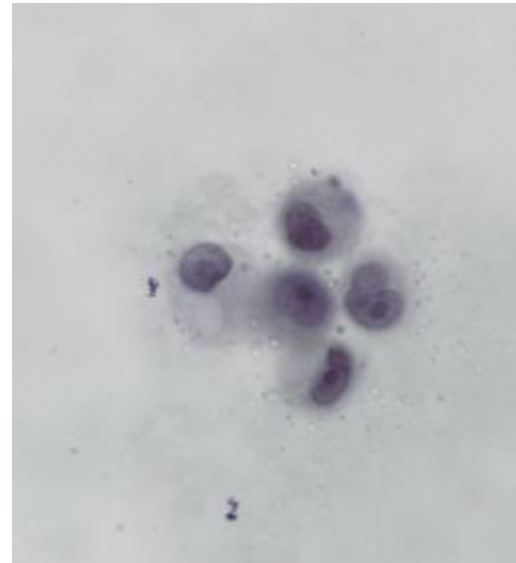
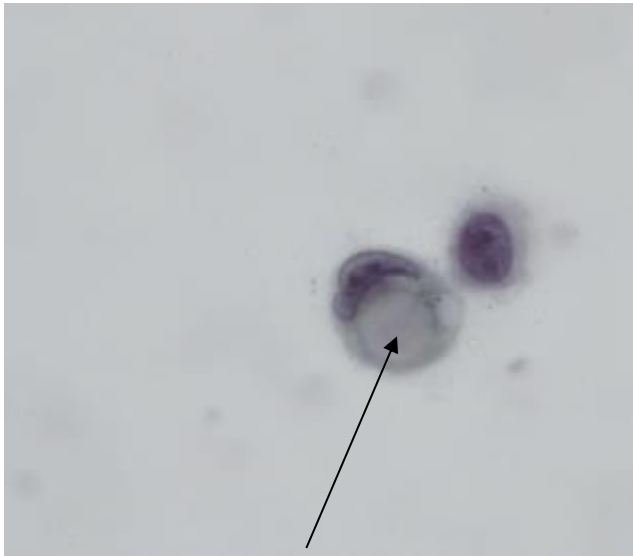
Millipore filter



Celler markeret med pile

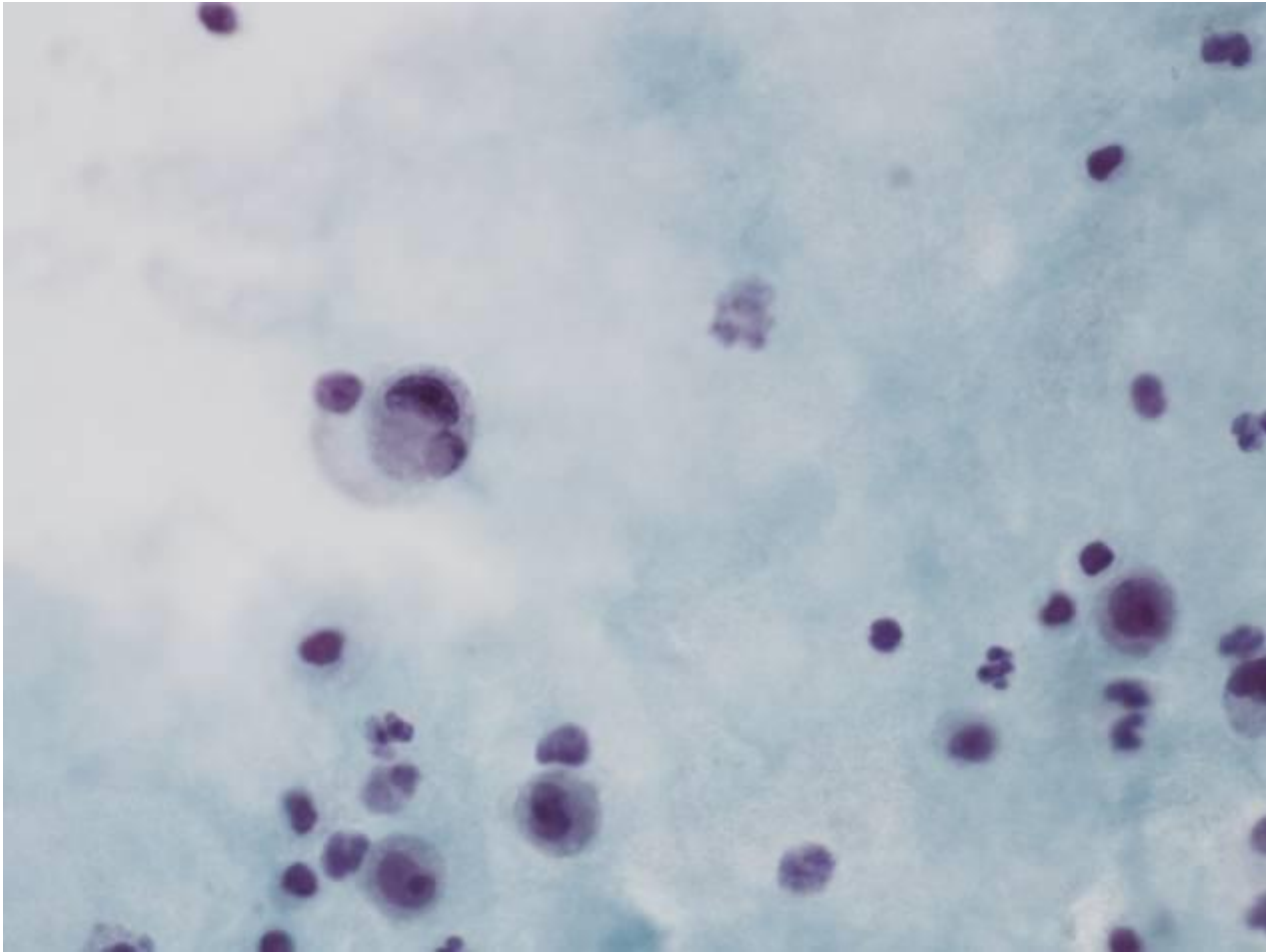


Ascites

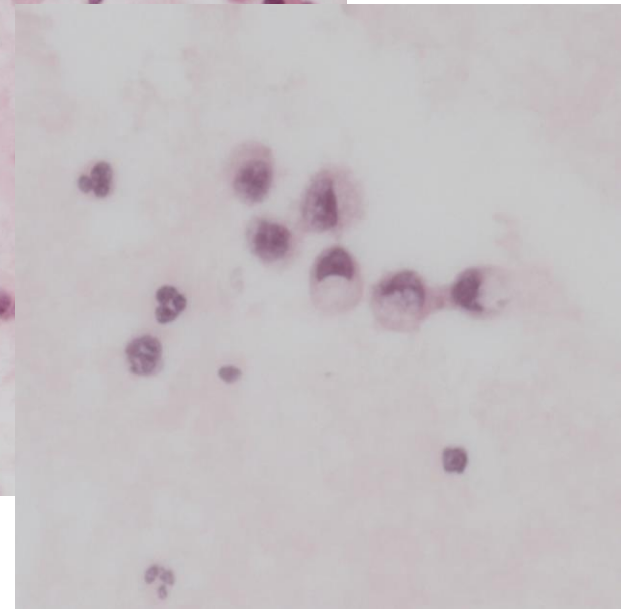
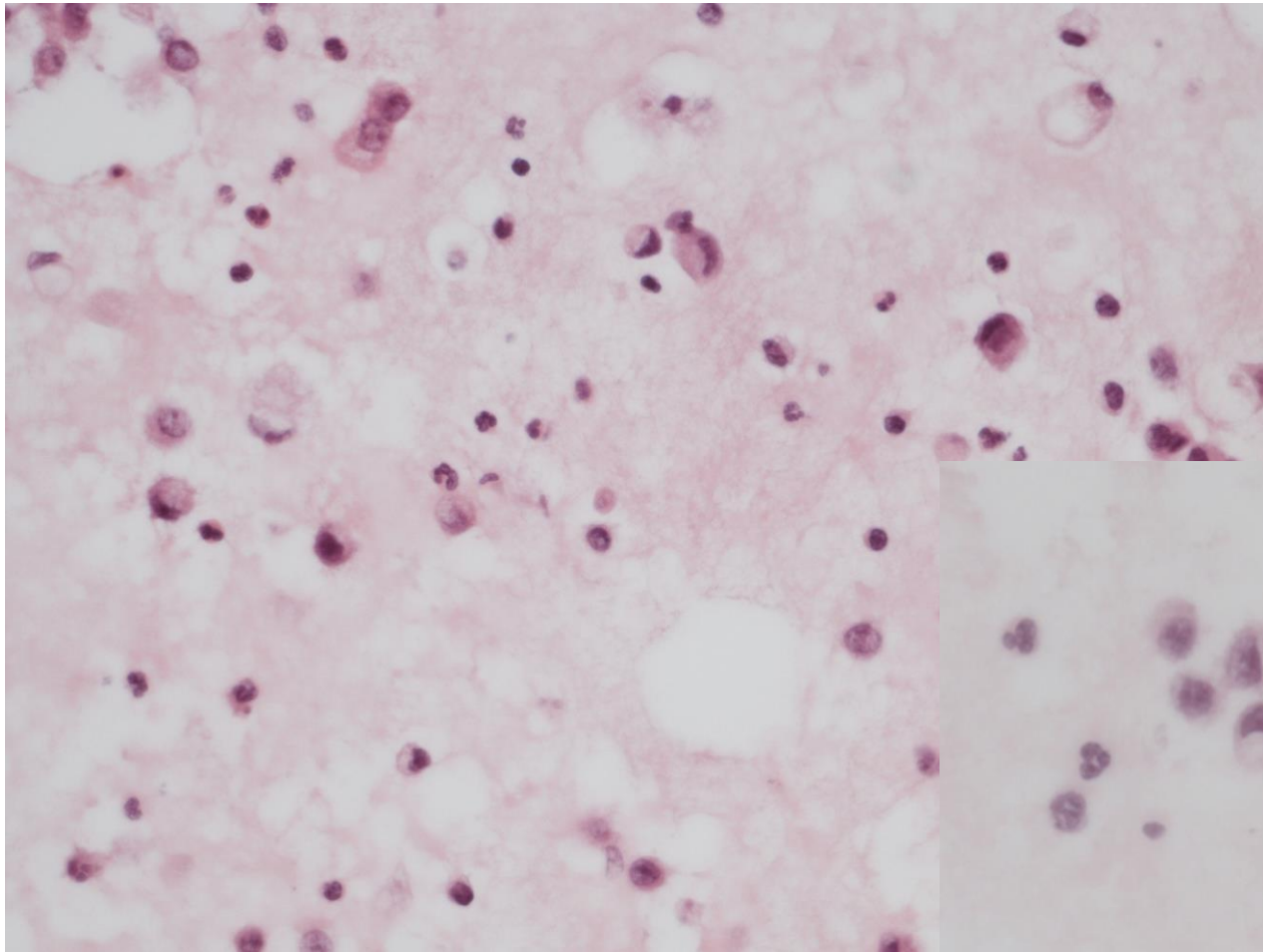


Millipore filter

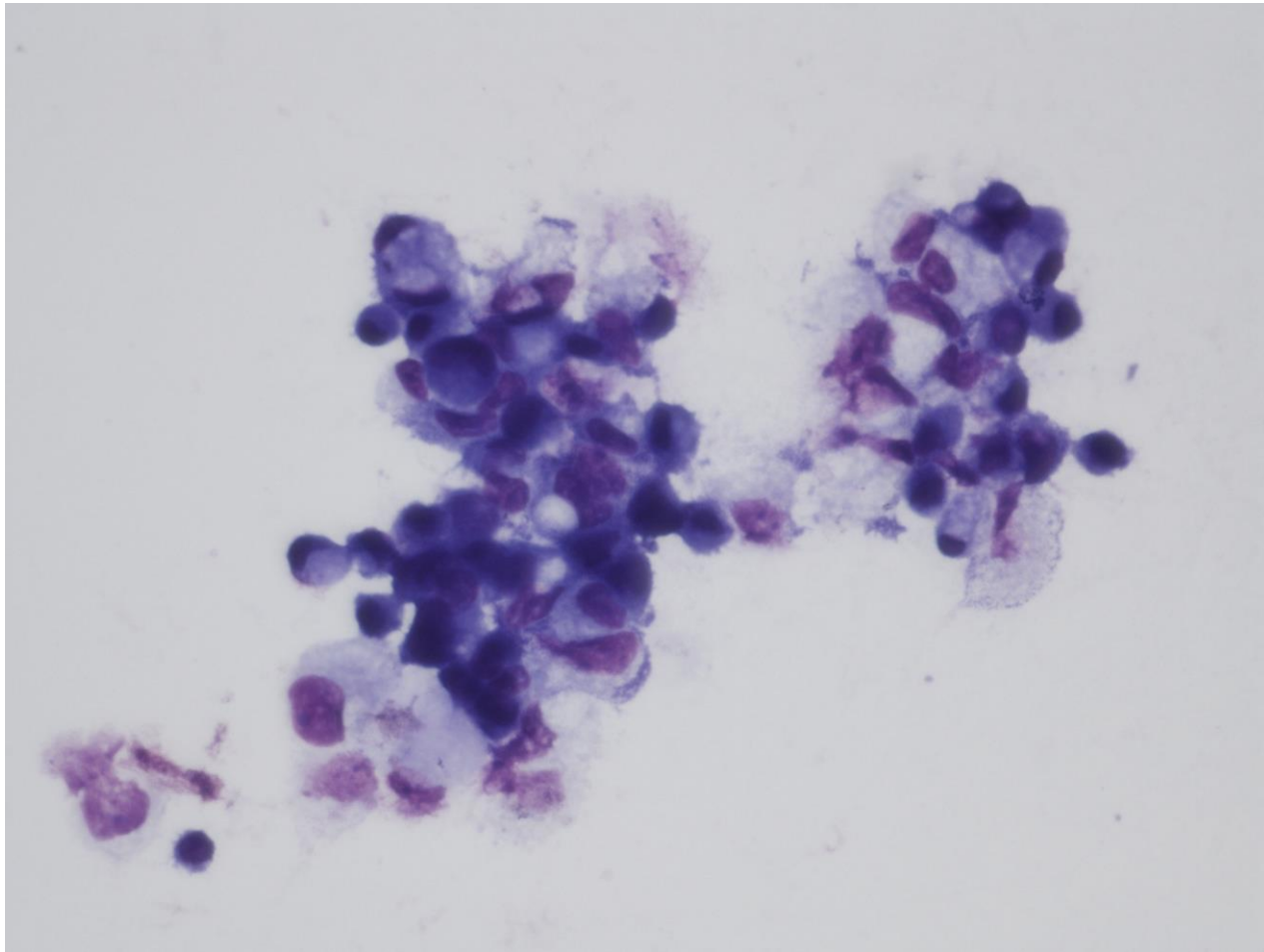
udstrygning



Koagel HE –diagnose?



FNA fra oment



Ascites

- Kliniske oplysninger: cancer ventriculi og mistanke om peritoneal karcinose. Diagnostisk ascites væske med aspiration af klar væske. FNAX3 fra suspekt, tilsyneladende infiltreret oment
- Ascites Adenokarcinom
- FNA oment metastase adenokarcinom
- Hist ventrikelslimhinde med signetringskarcinom