Månedens case
Maj 2013

- 56 årig kvinde med AGC-atypiske cylinderepitelceller, HPV RNAtest negativ i dec. 2008
- Histologi (cervixskrab, portiobiopsier) januar 2009 i privatpraksis viste normalt væv
- Smear maj 2010, se efterfølgende billeder

PAP smear, mikrobiopsi

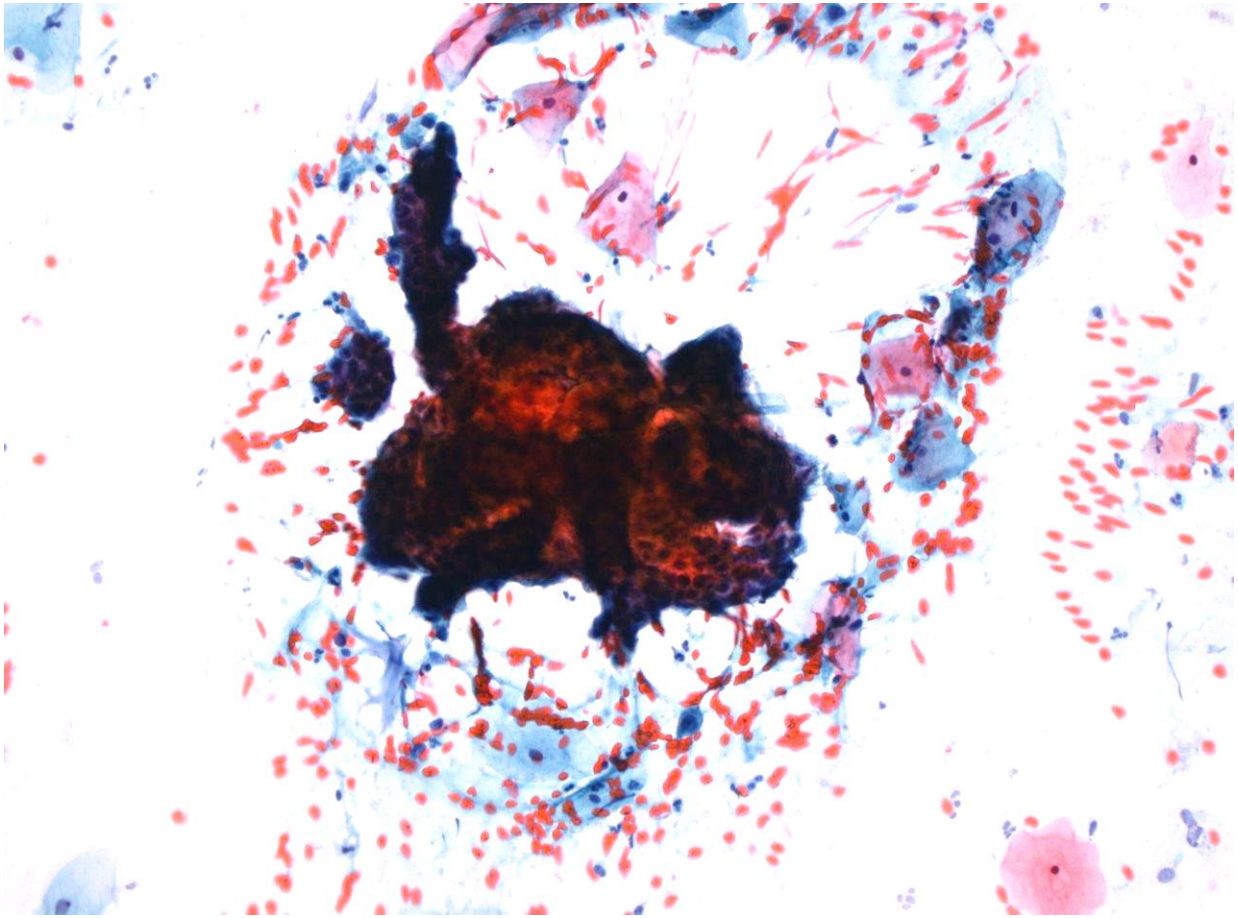

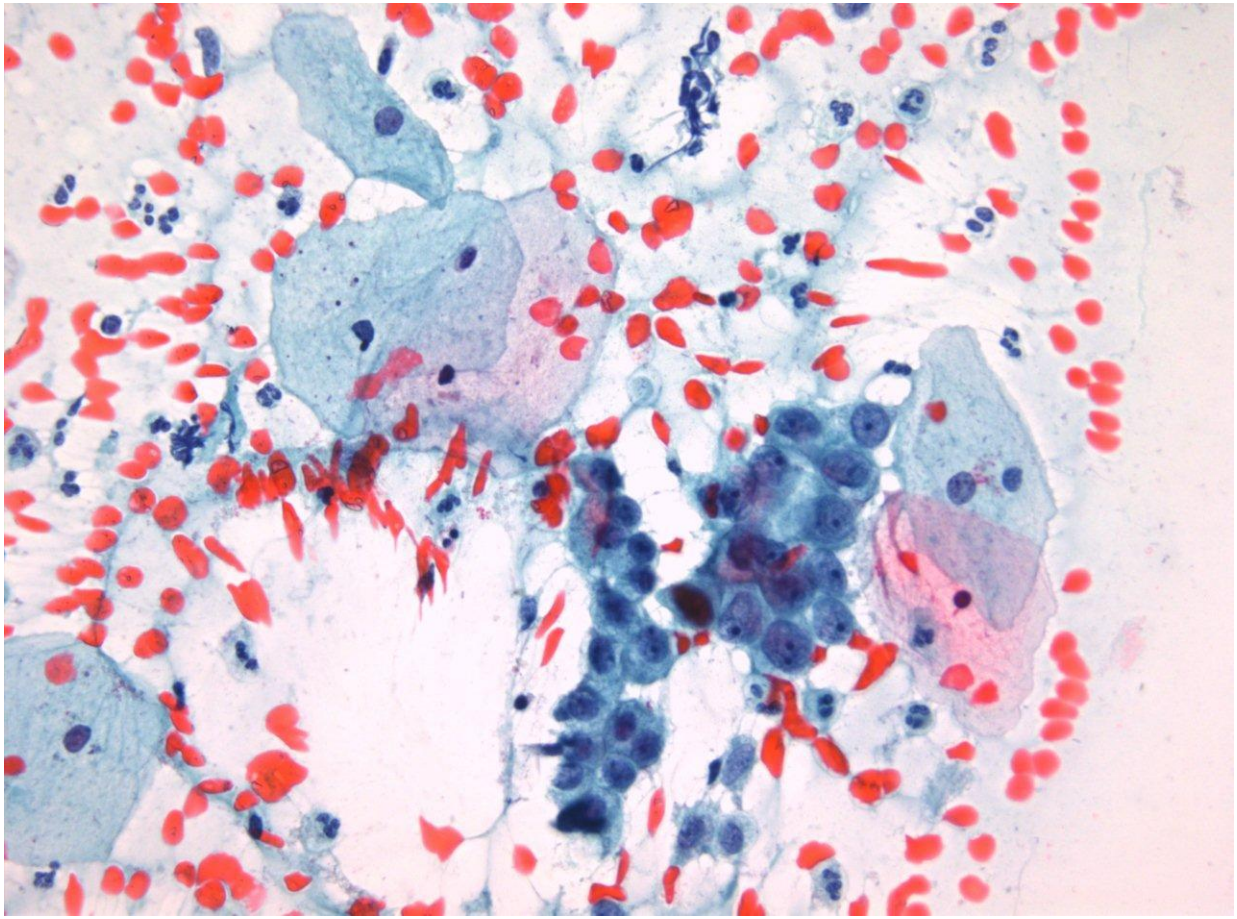

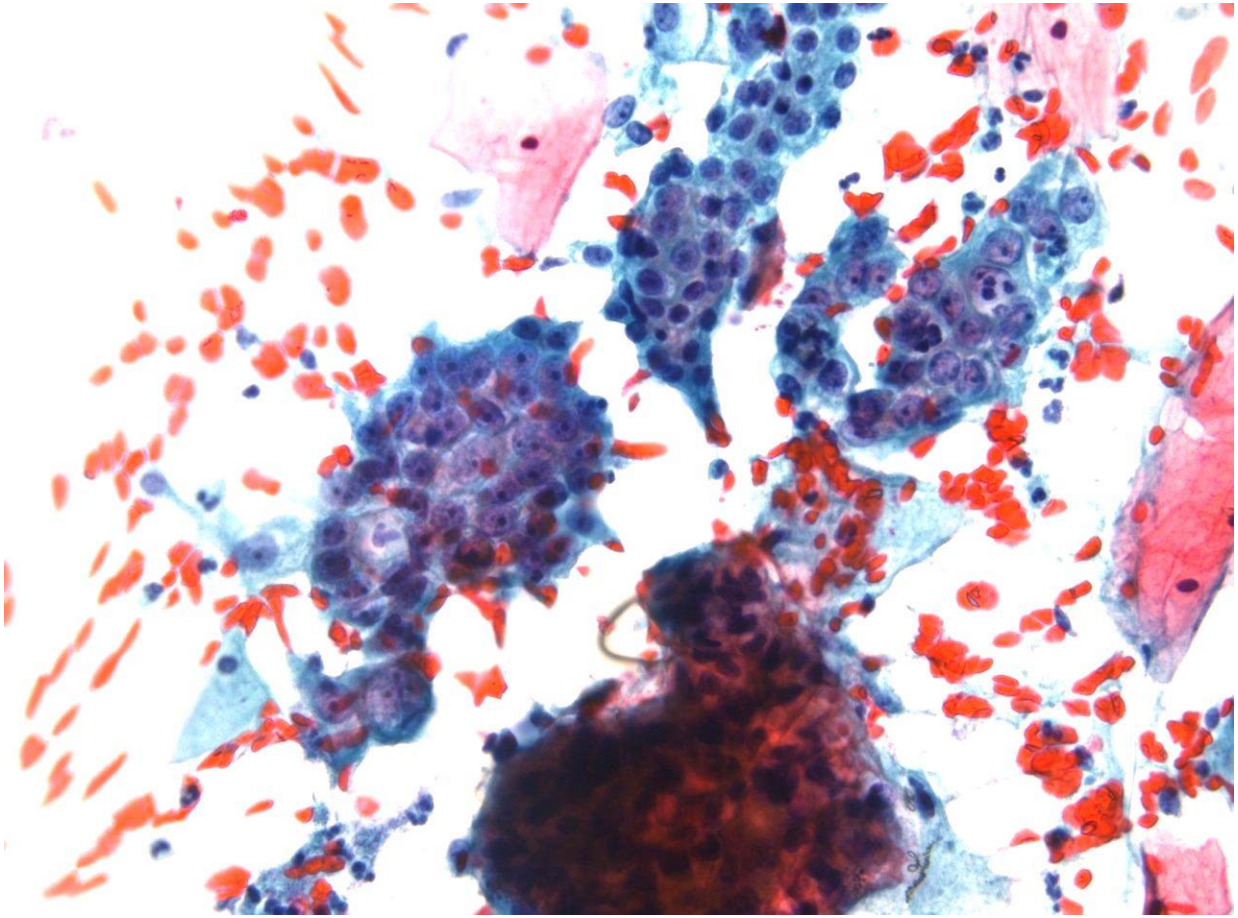

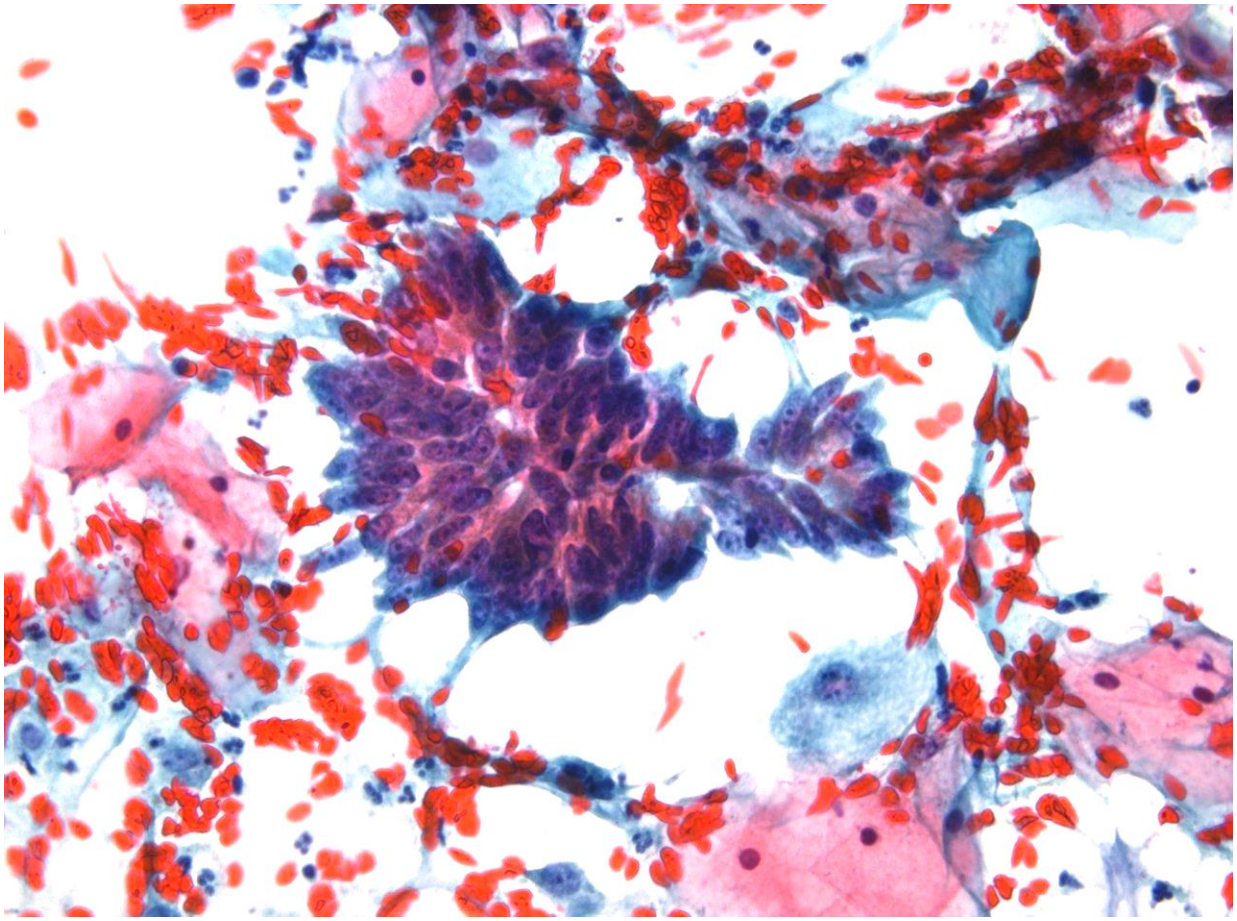

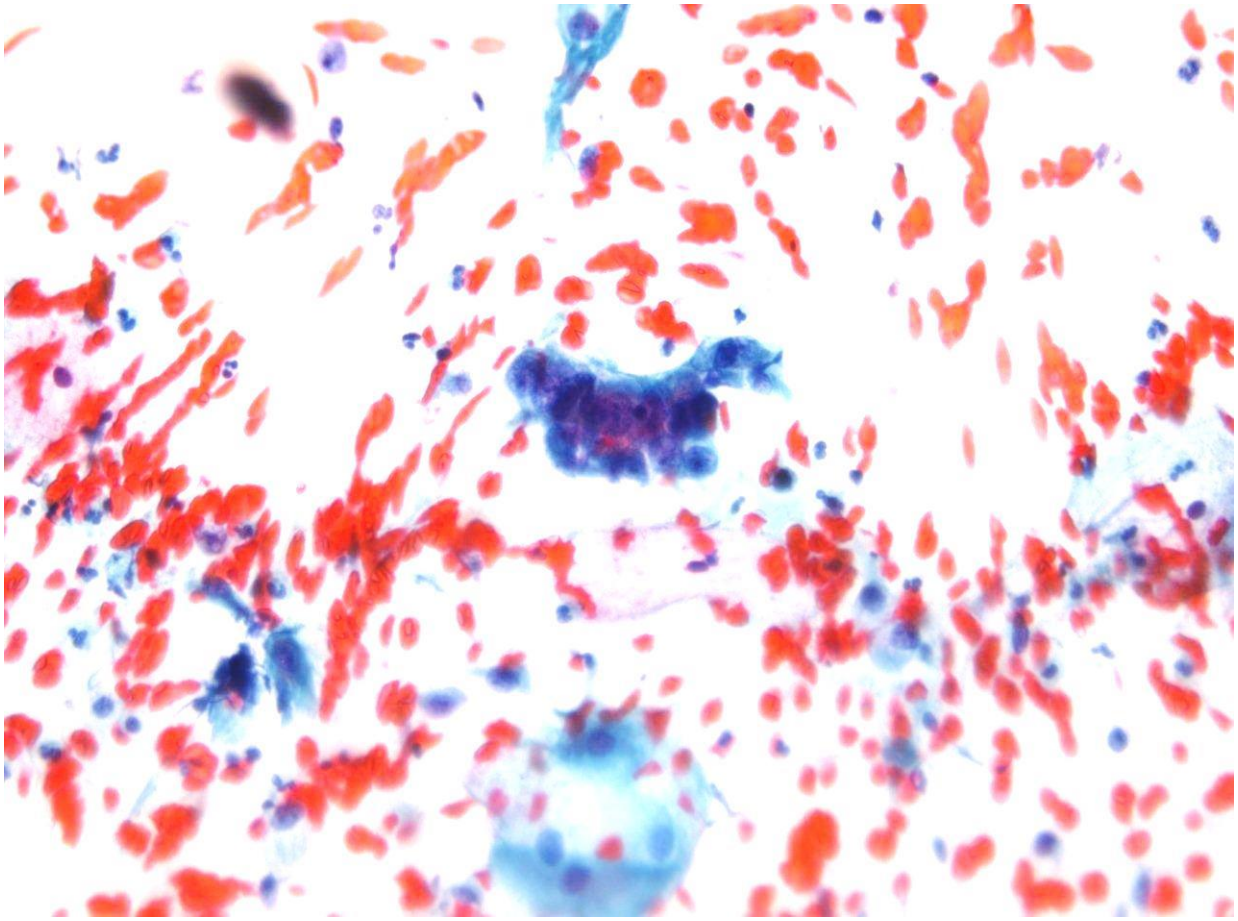

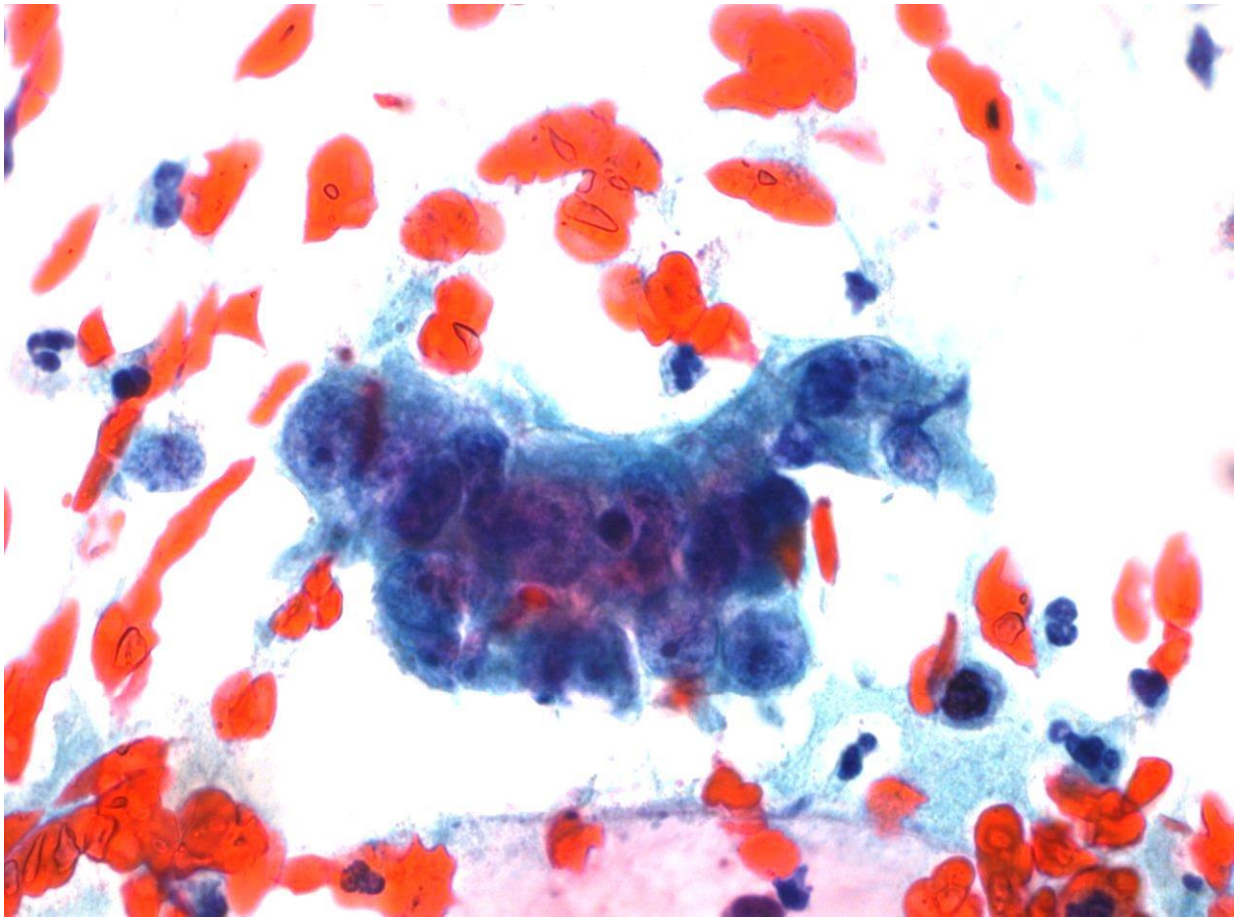

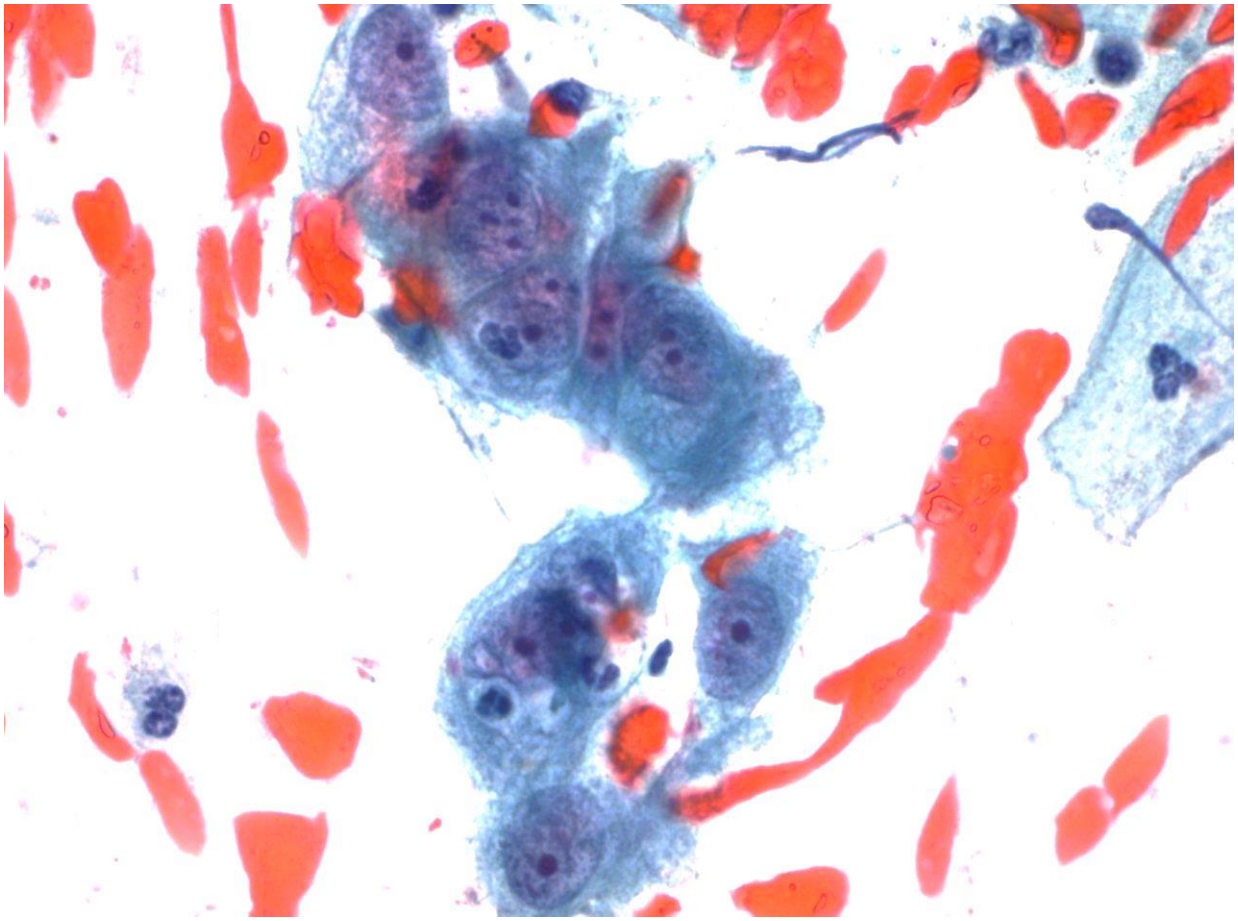

Diagnose?

- Repair?
- AGC?
- AIS?
- Adenokarcinom?

Konus efterfølgende

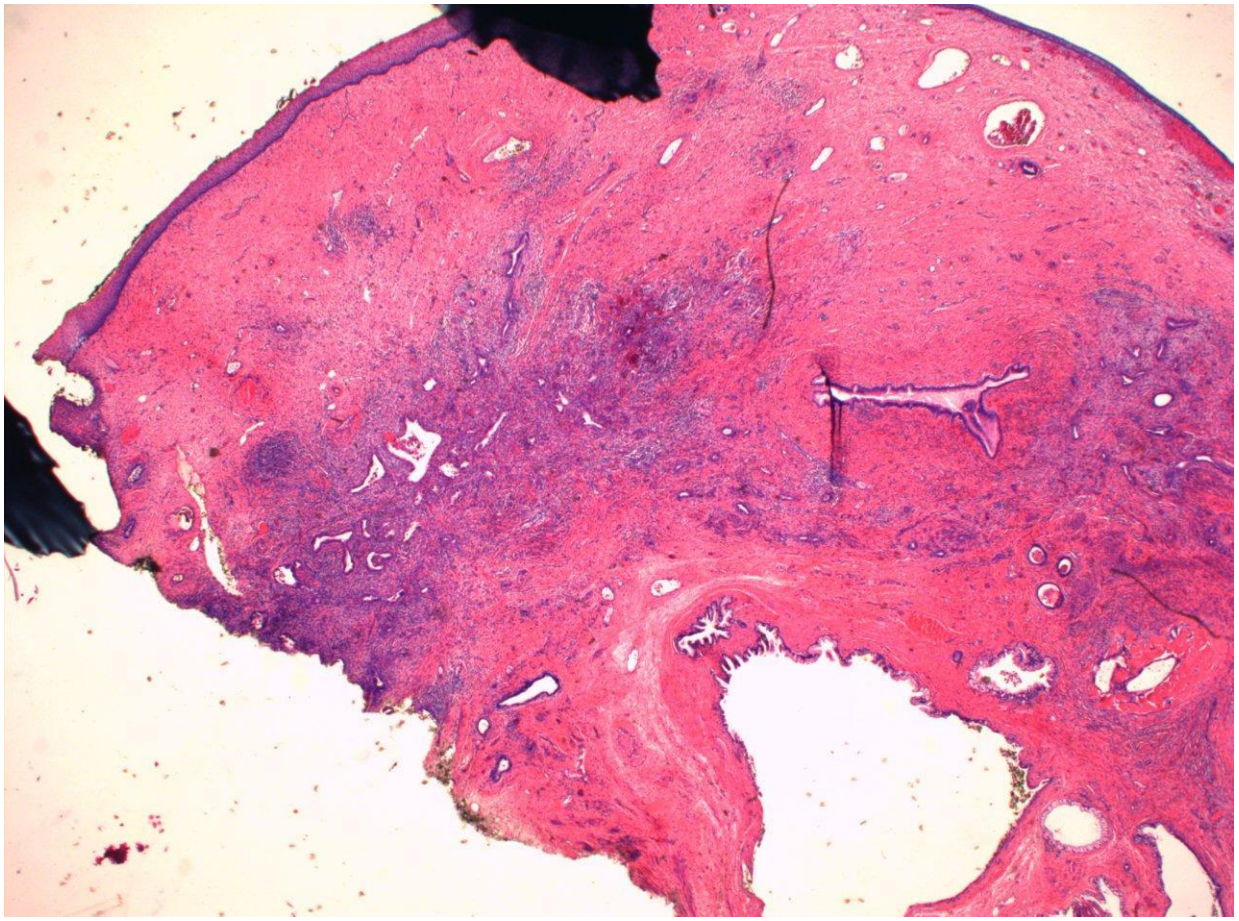

Spredtliggende irregulære kirtler i stroma, også dybt ned til profunde/laterale rand

Spredtliggende kirtler med fokalt atypisk epitel. Distinkte nukleoler. Se mitose (pil). Stromaet er desmoplastisk.

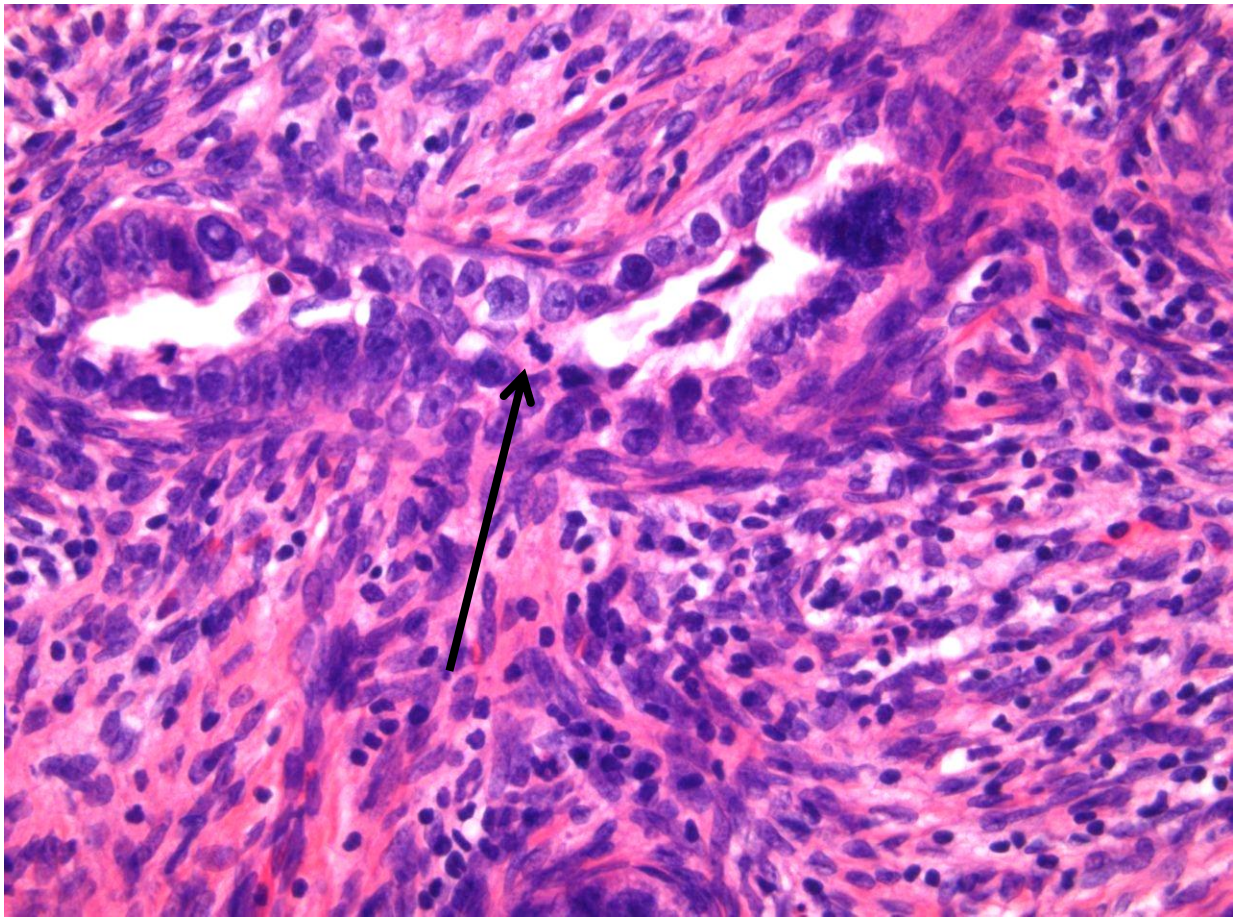

Ki67 varierende

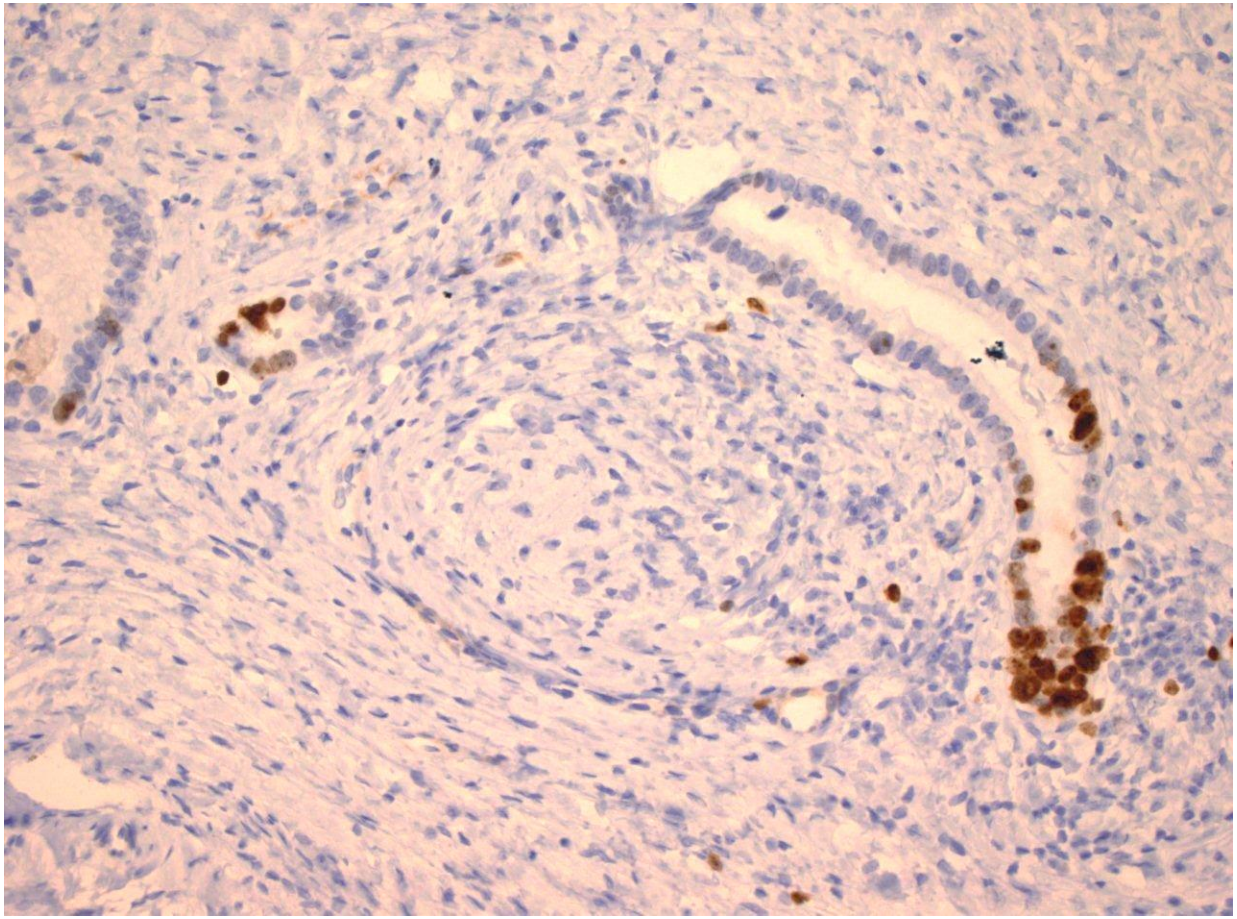

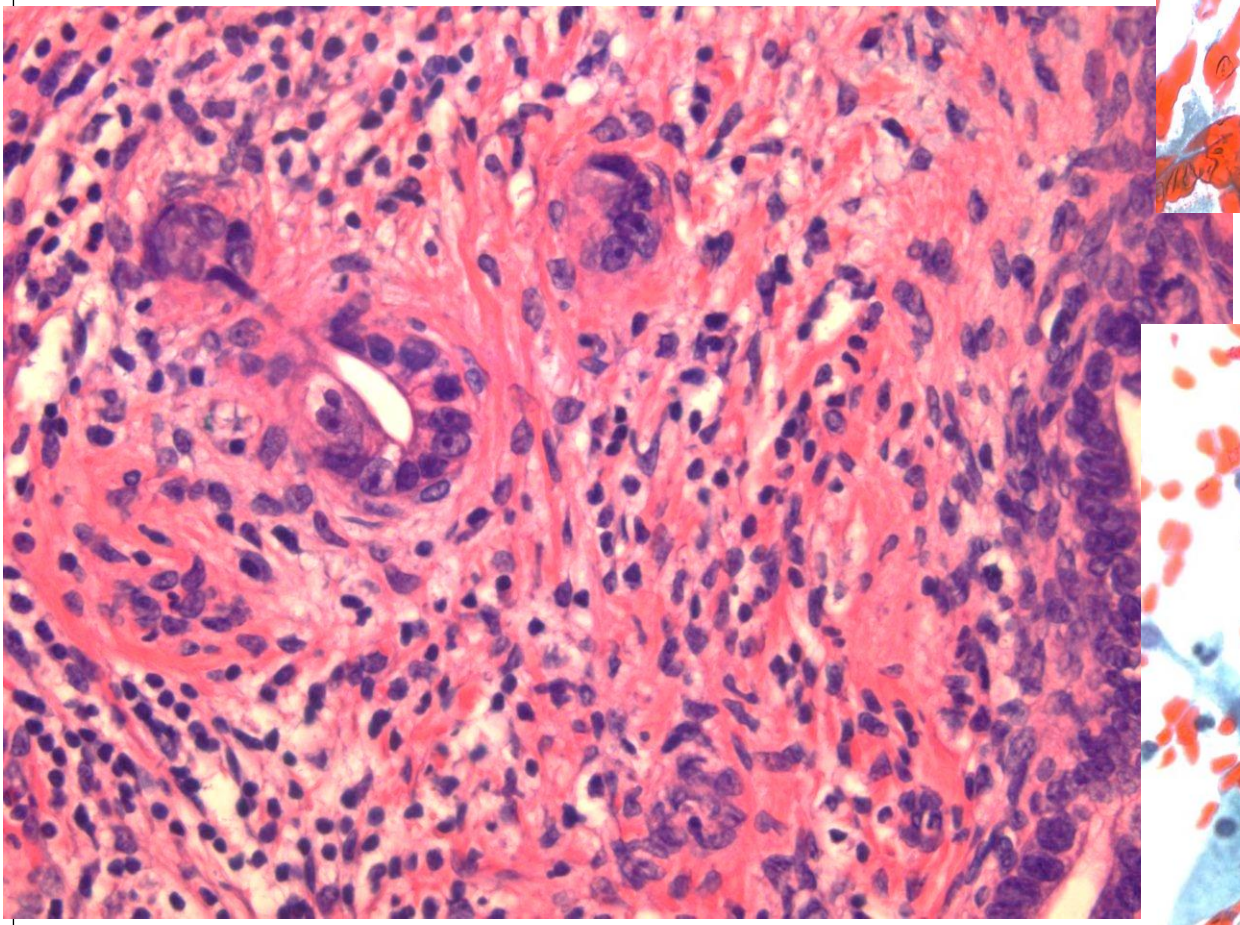

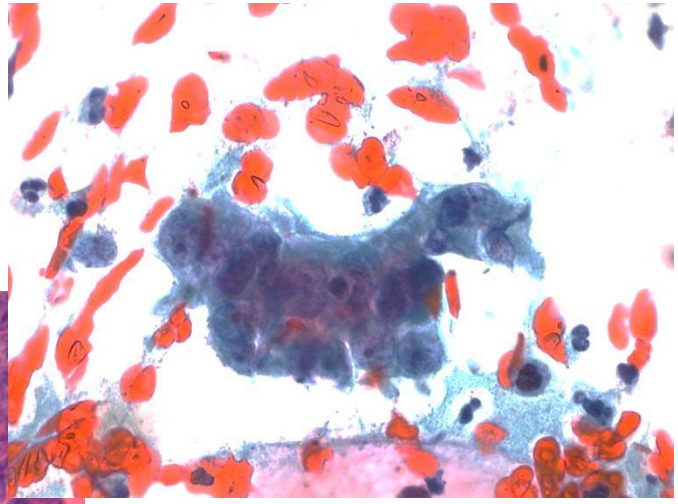

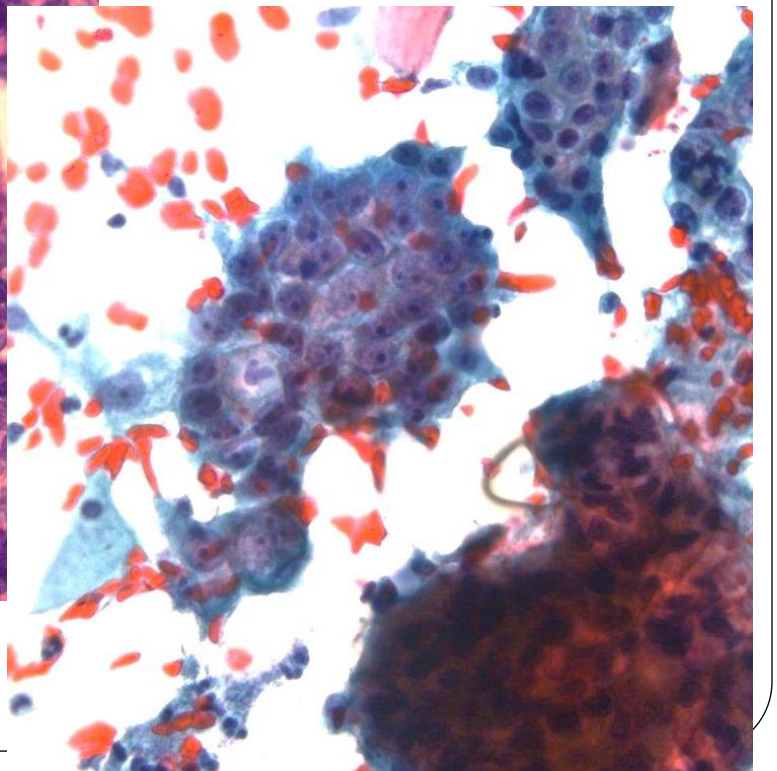

Negativ P16

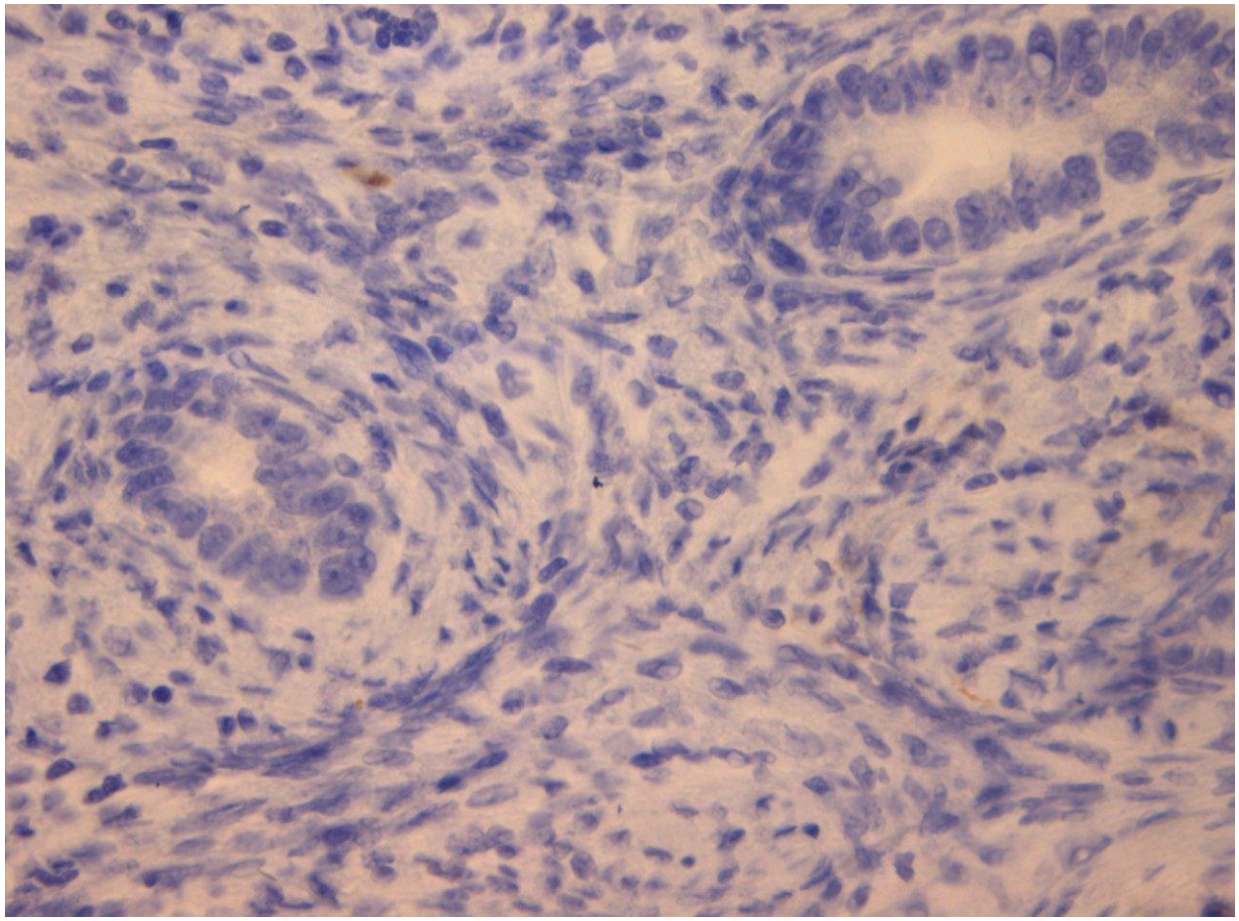

Diagnose: adenoma malignum (minimal deviation adenocarcinoma)

- Sjælden variant (1%) af cervikalt adenokarcinom
- Prognose ofte dårlig, da diagnose stilles sent
- Meget højt differentierede kirtler, men fokal atypi, dybtvoksende i cervikalt stroma
- Ikke HPV-relateret (P16 negativ)