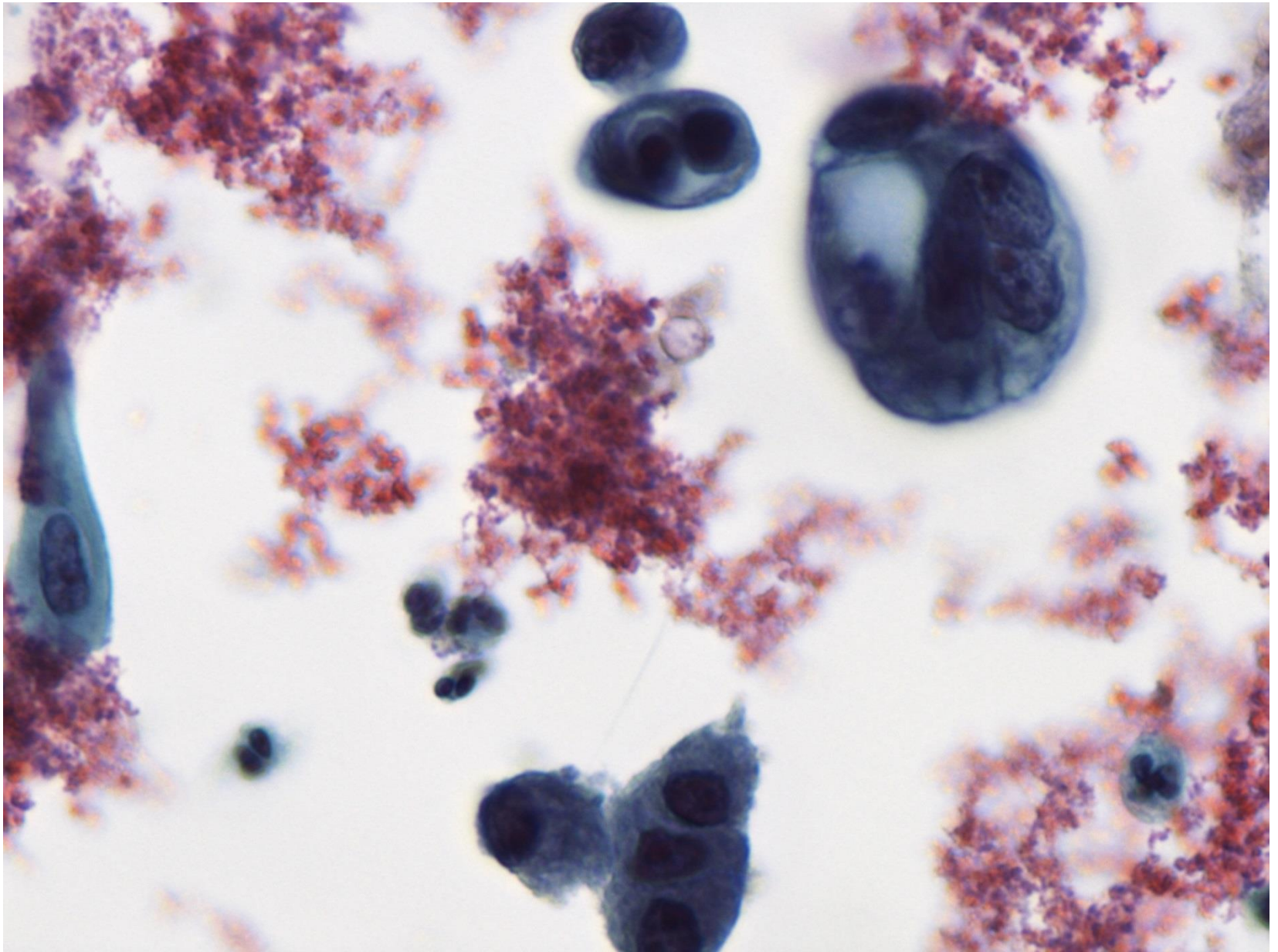
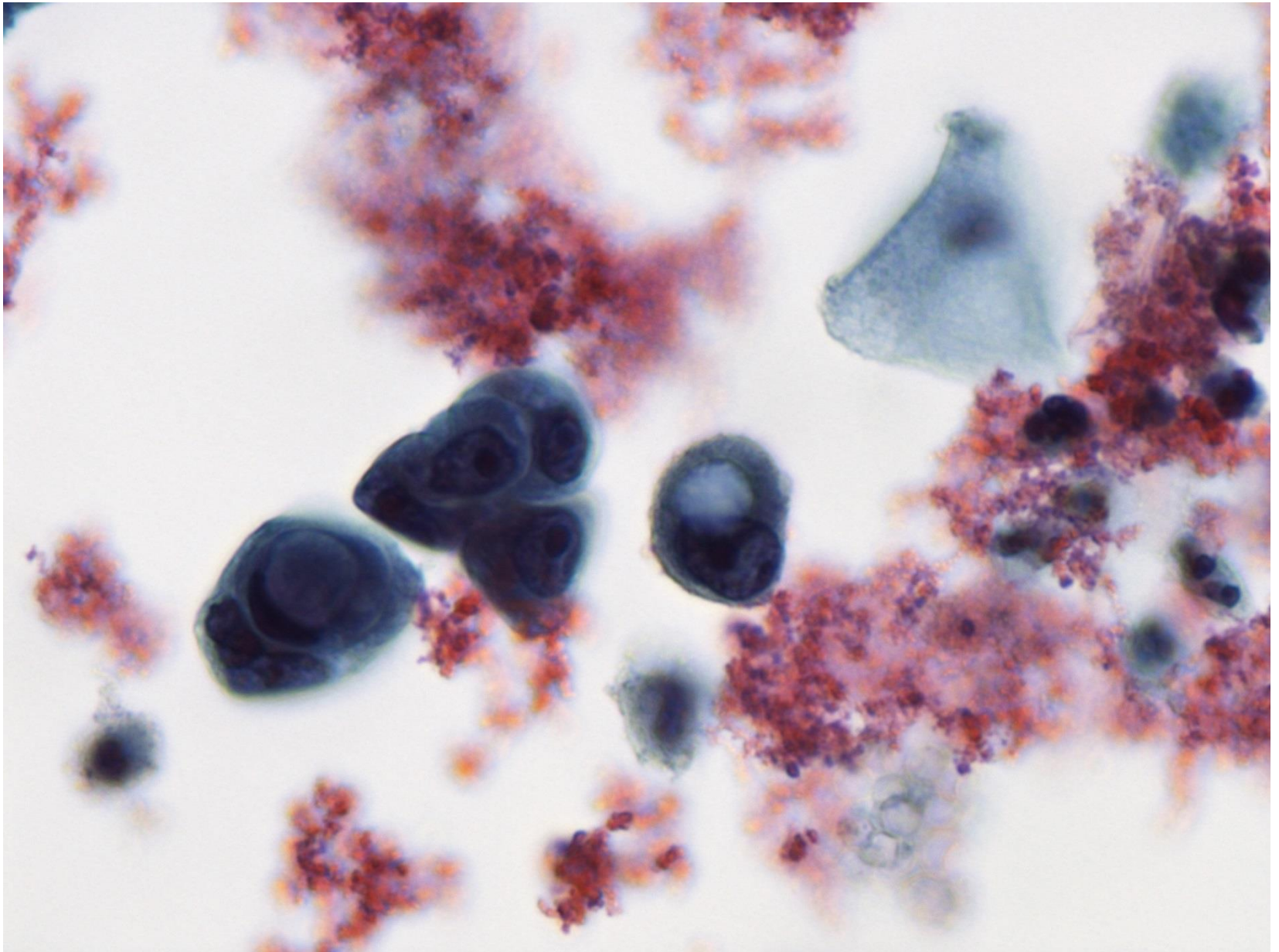


Månedens case november 2013

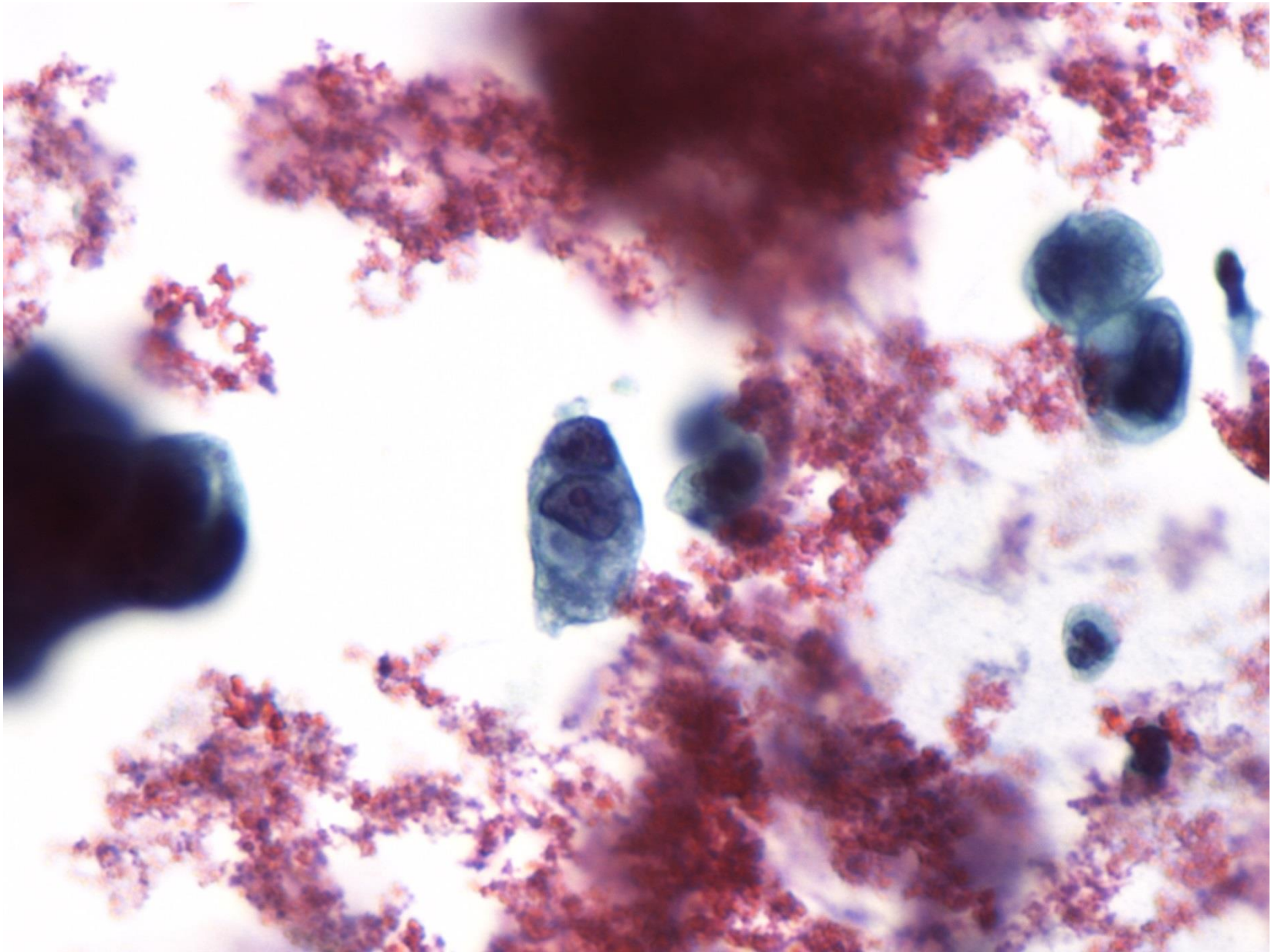
Væskebaseret cytologi fra 70 årig
kvinde med stor tumor på cervix uteri.
Opereret for cancer recti for 2 år siden.



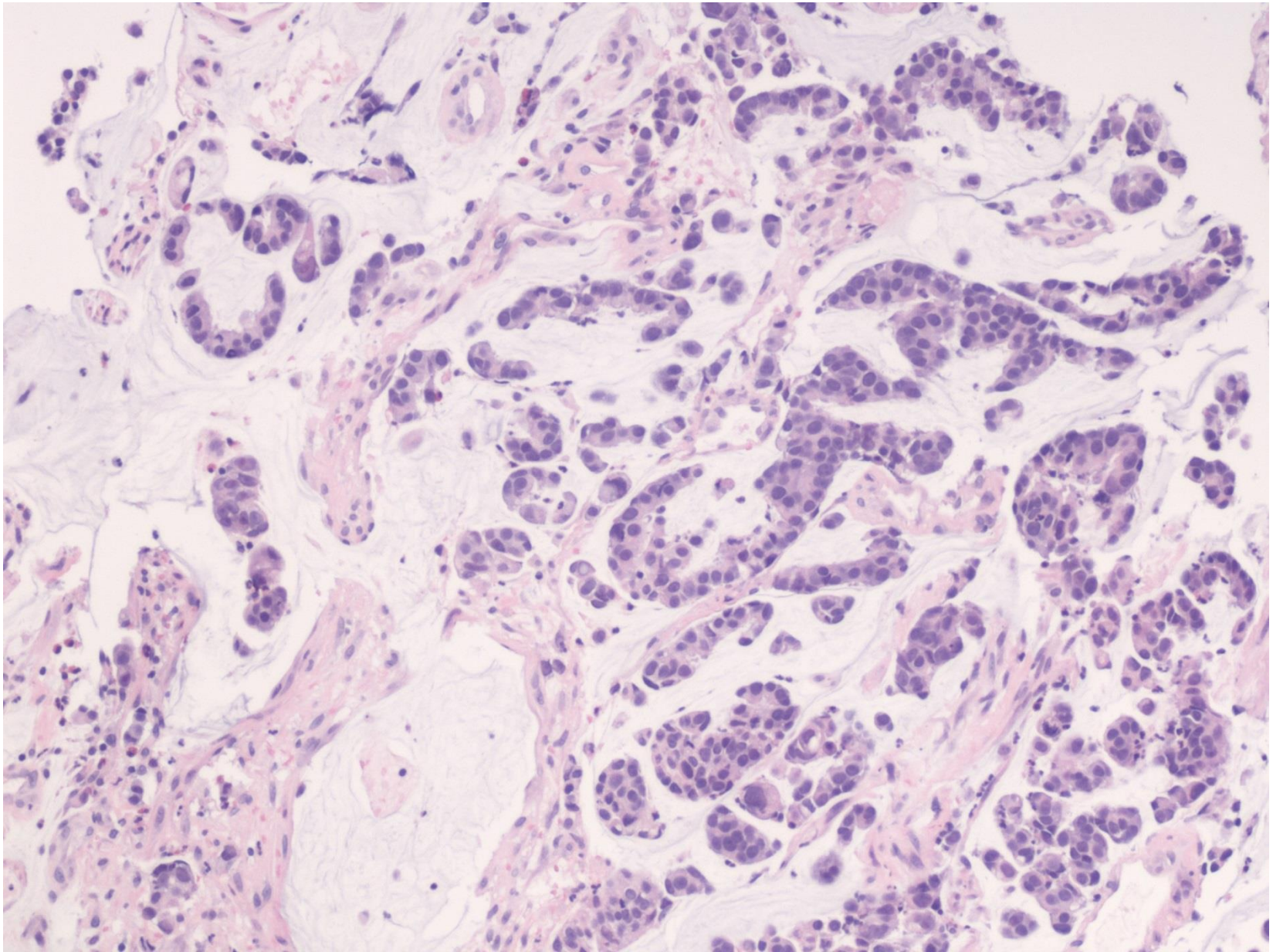
SurePath VBT 600 x forstr.



SurePath VBT 600 x forstr.



SurePath VBT 600 x forstr.



Samtidig portibiopsi med adenokarcinom metastase fra rectum. HE 100 x forstr.