Månedens case
Marts 2013

PLEURAVÆSKE

UDLÅNT AF:
DORTHE EJERSBO
AFDELING FOR KLINISK PATOLOGI, ODENSE UNIVERSITETSHOSPITAL

Case
Marts 2013

92 årig mand med svær aorta-insufficiens indledende med åndenød. Røntgen af thorax viser højresidigt, moderat pleuraekssudat, muligvis relateret til kar-problemerne, men det er ikke helt oplagt.

Materialet fremsendes til cytologisk undersøgelse. Der modtages 1.800 ml. gul væske, der procederes både med UST og VBT (ThinPrep). Der fremstilles både et plasmatrombin-koagel og en Cellient celleblok.

Pleuravæske

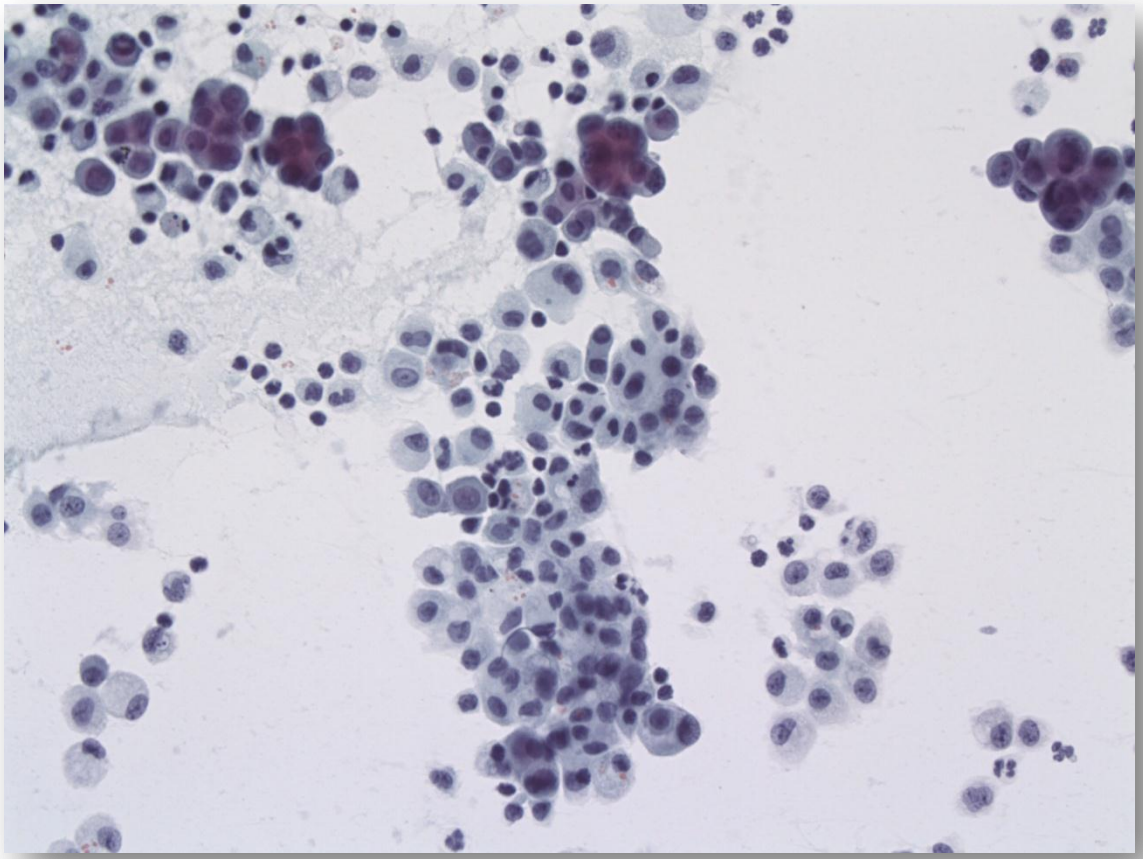

UST Pap 20x

UST

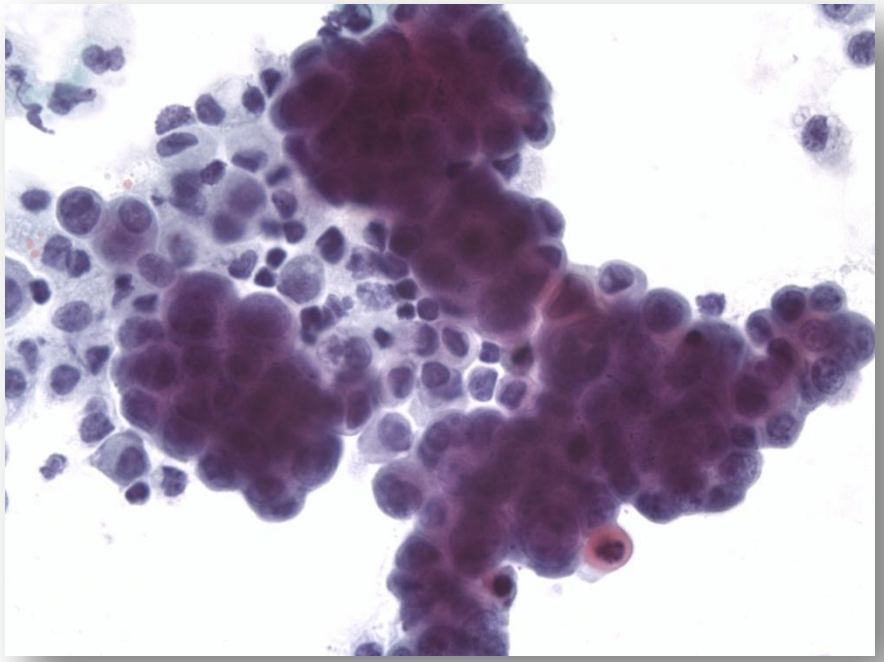

VBT

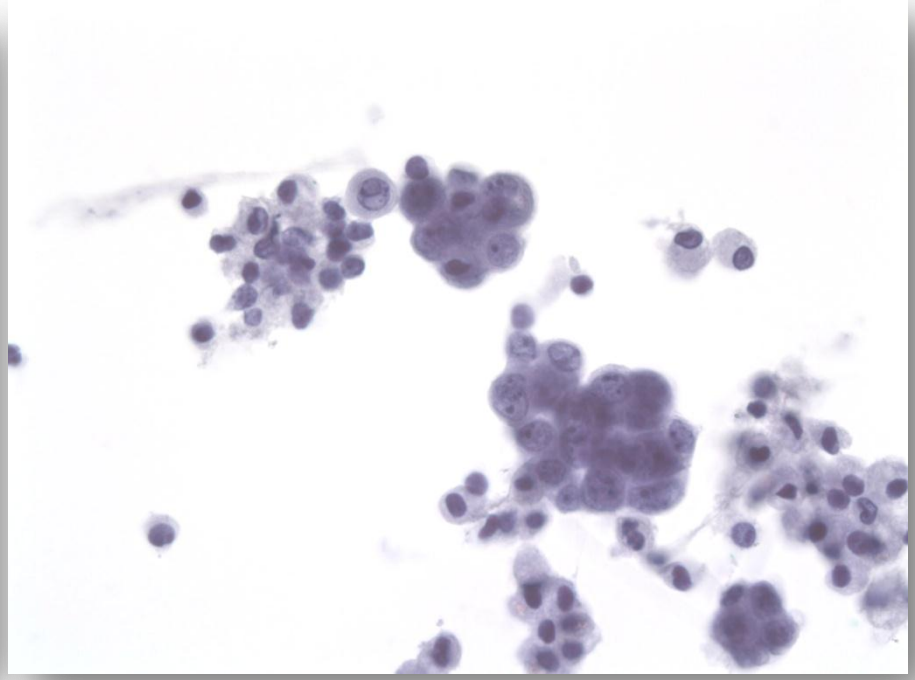

Pap 40x

UST

VBT

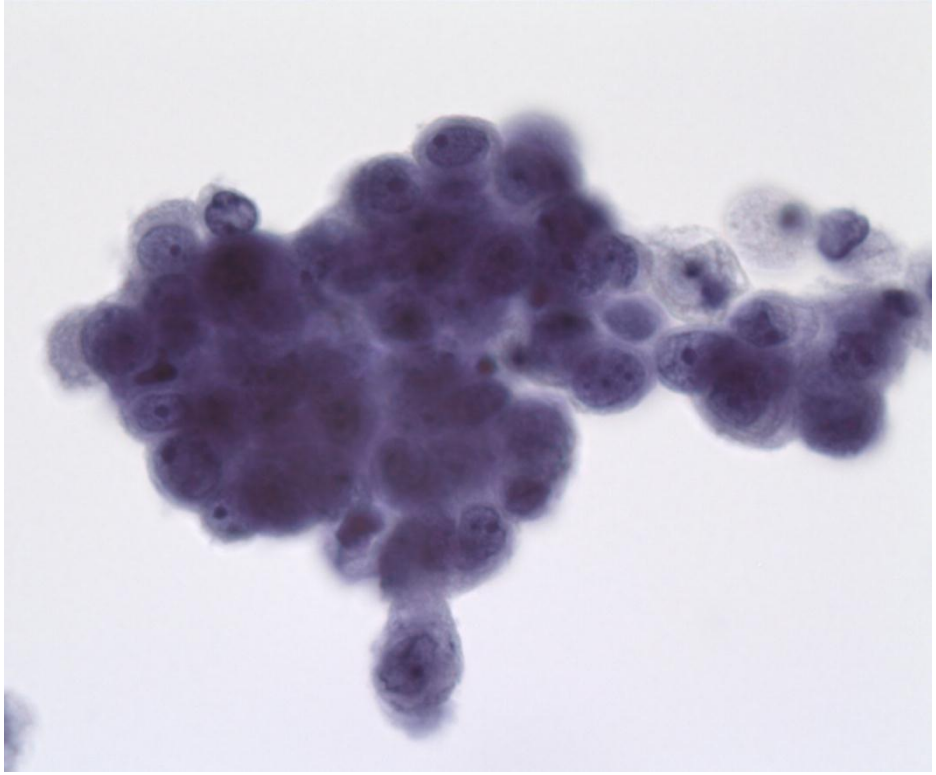

Pap 63x

UST

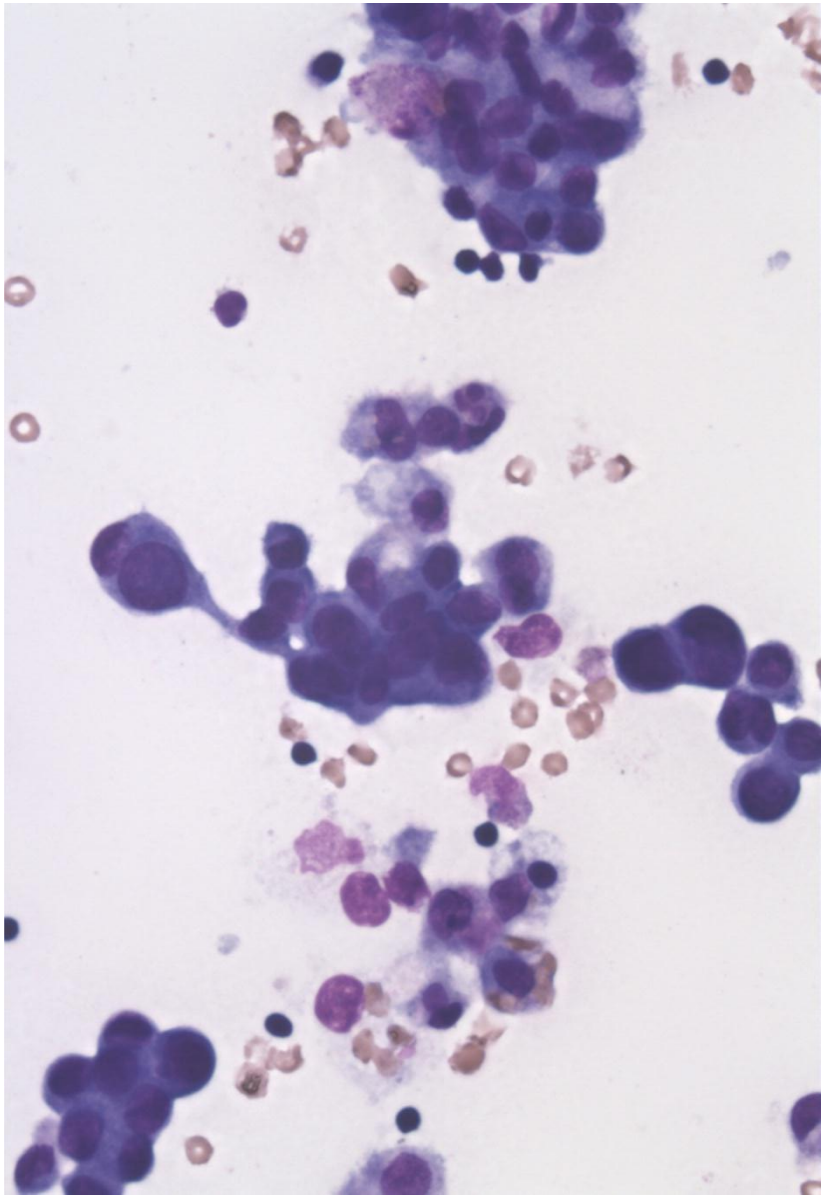

VBT

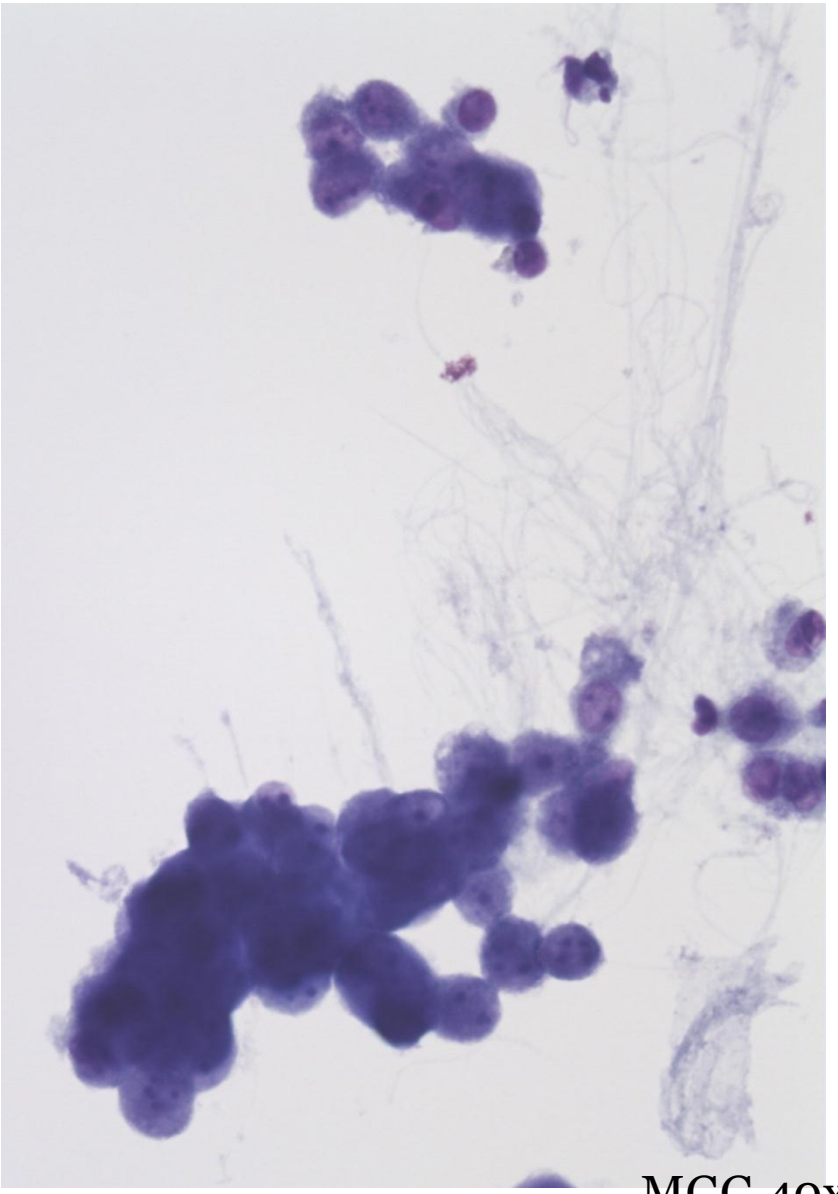

MGG 40x

Plasmatrombin

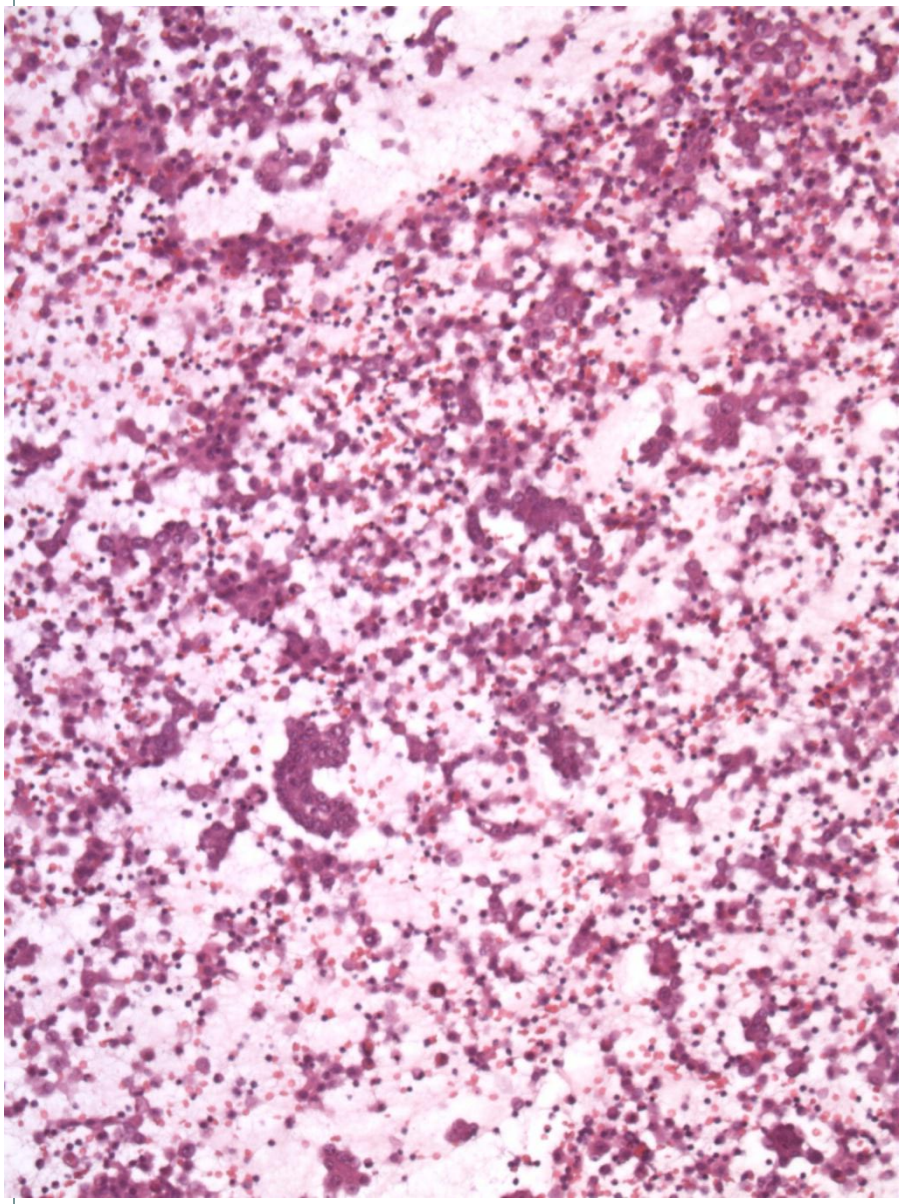

Cellient

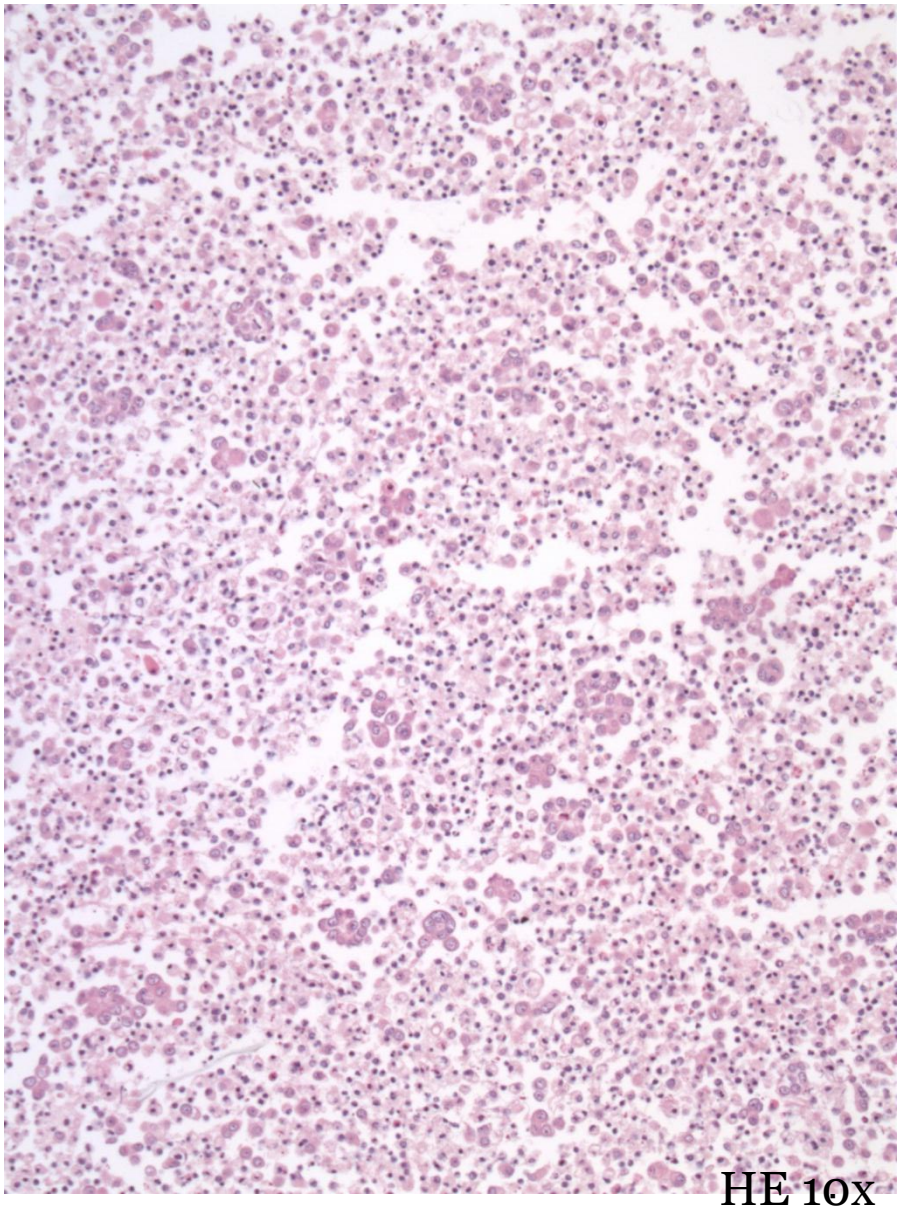

HE 10x

Plasma-trombin

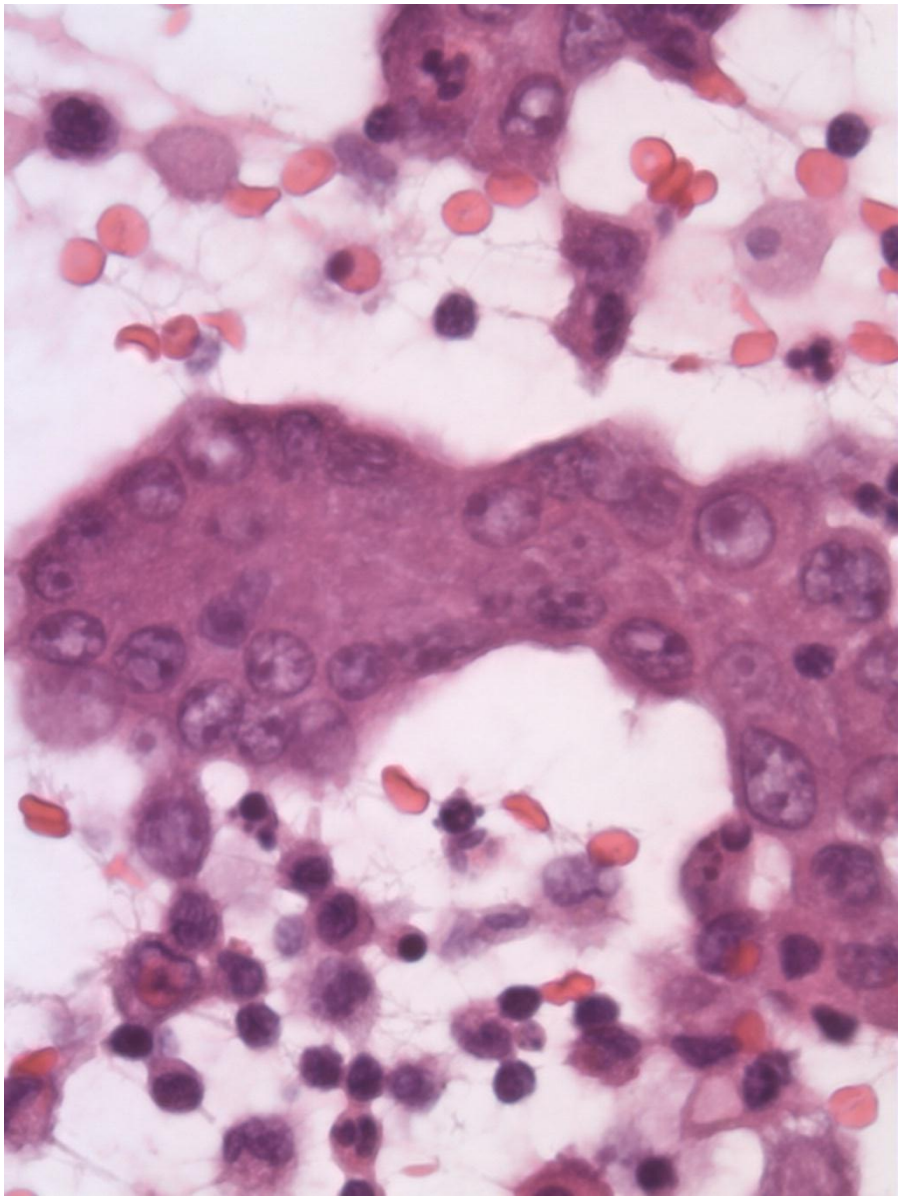

Cellient

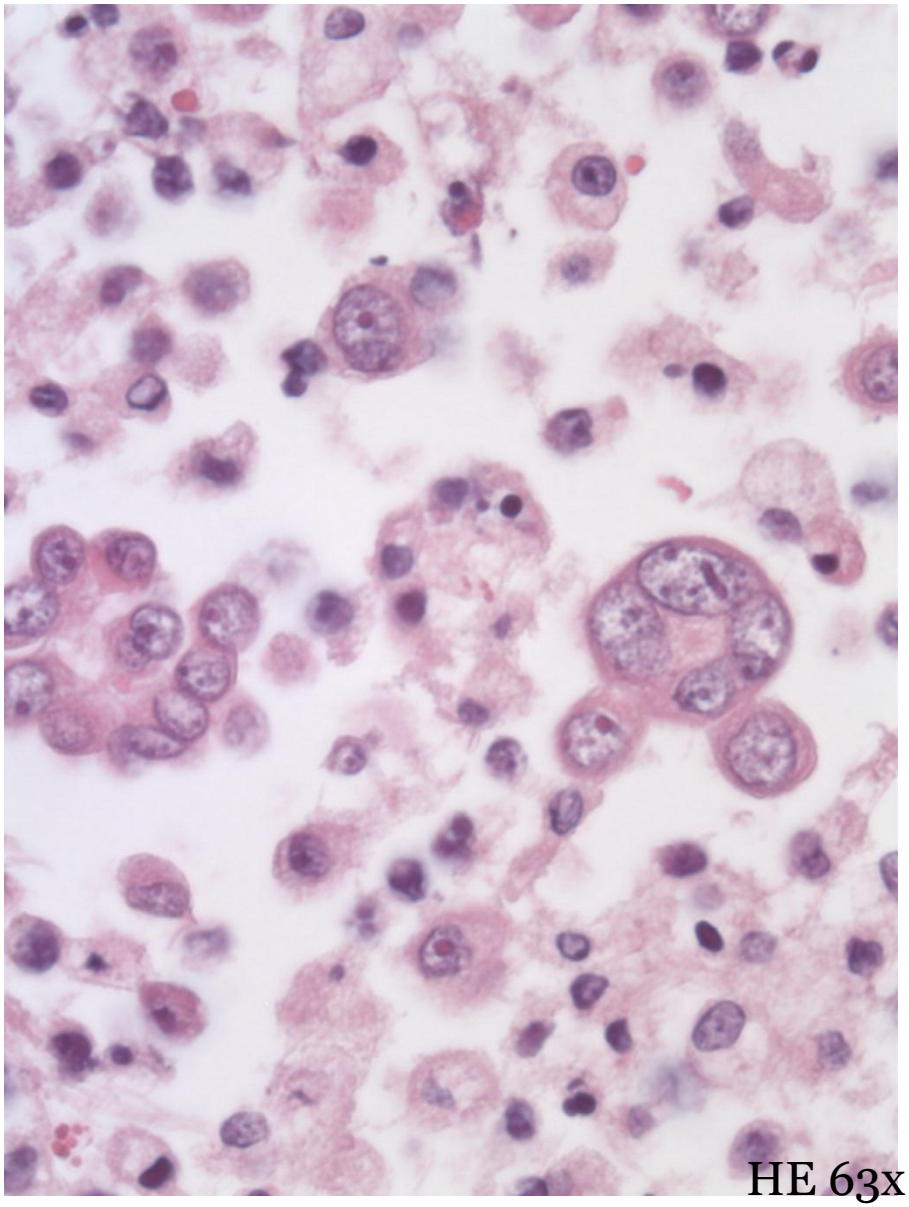

HE 63x

DIAGNOSE

- Reaktivt mesotel?
- Malignt mesoteliom?
- Metastase fra adenokarcinom?
- Andet?

ICC

Plasmatrombin

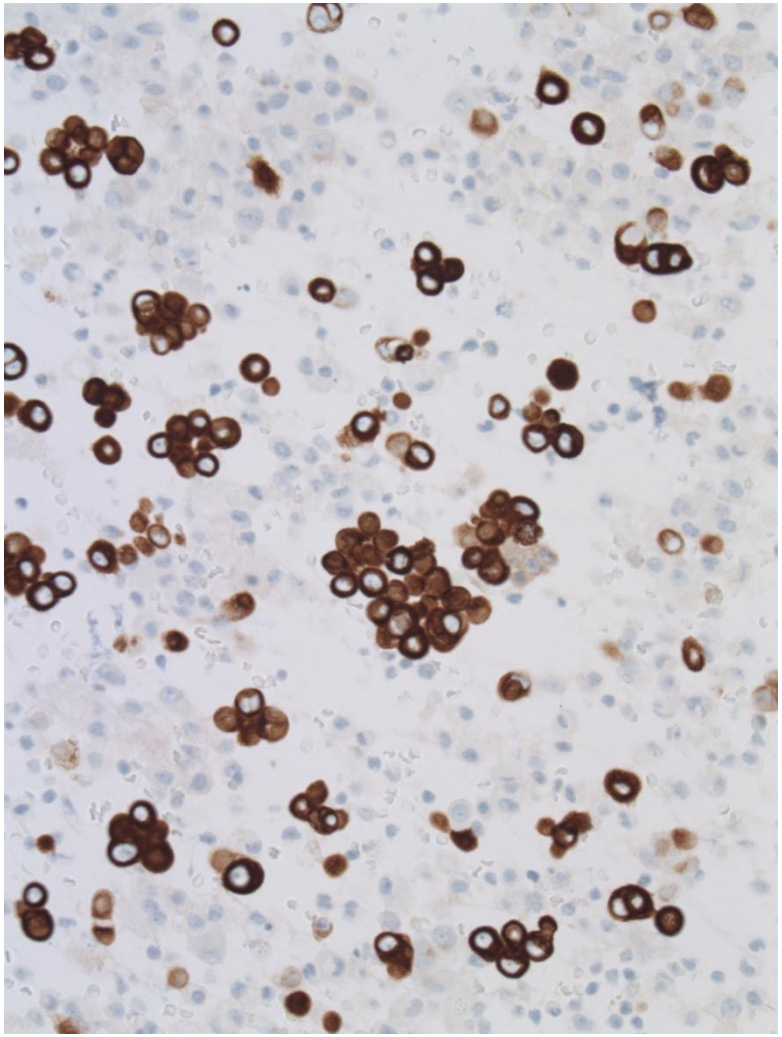

Cellient

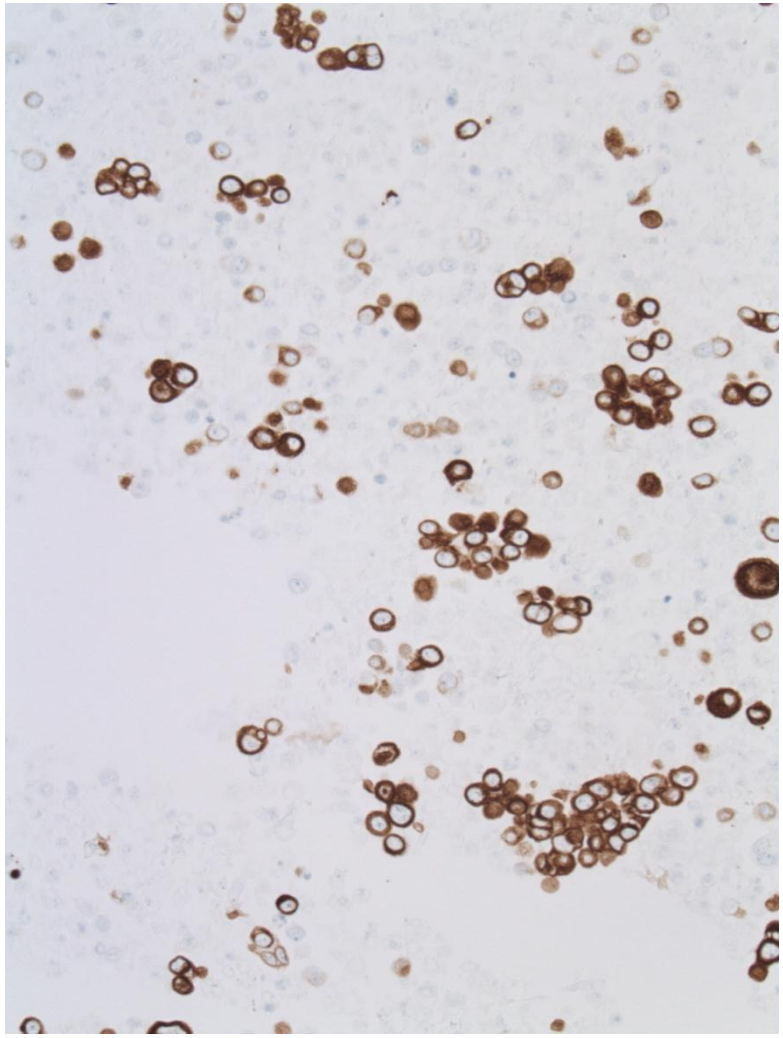

CK7 20x

ICC

Plasmatrombin

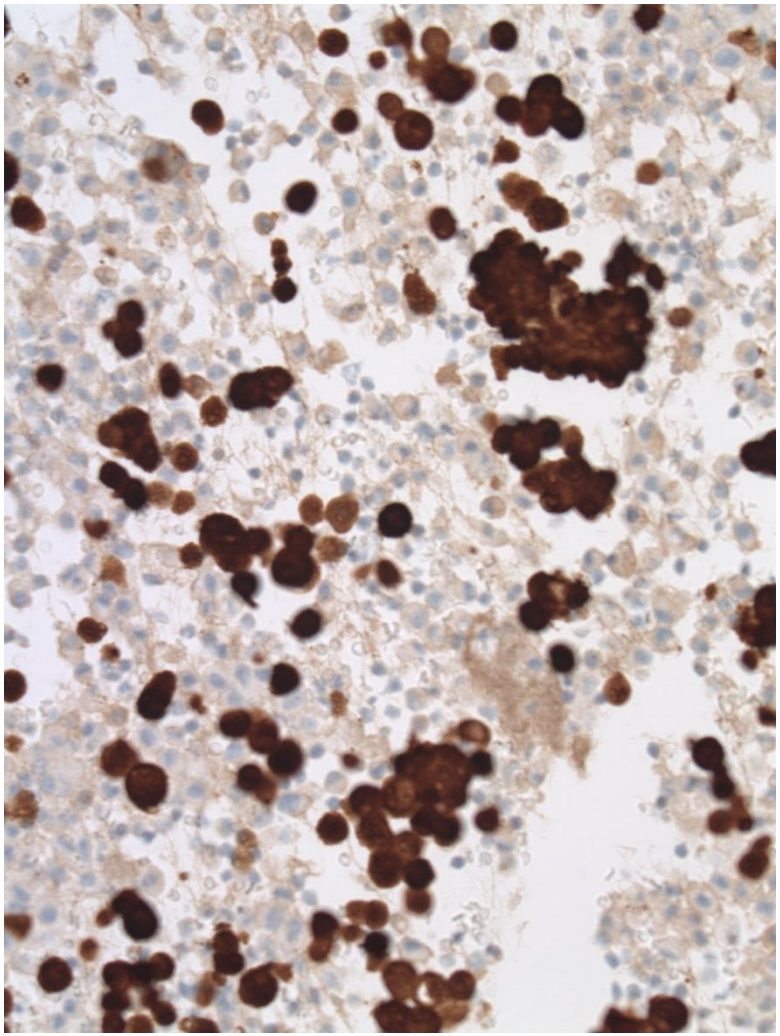

Cellient

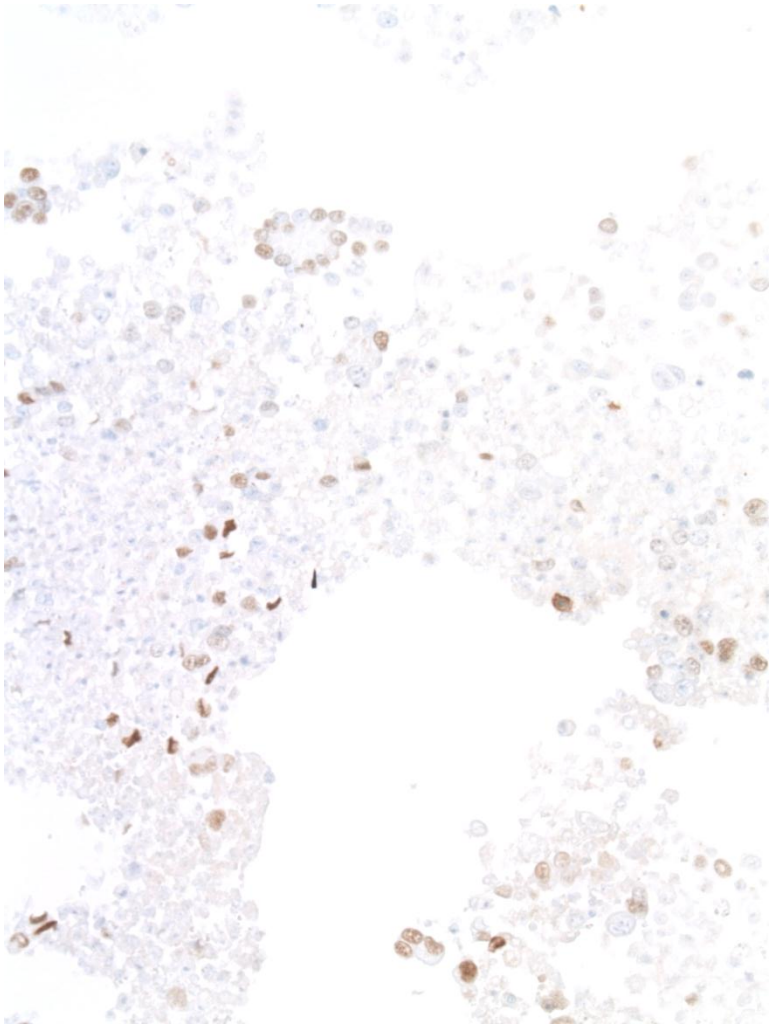

Calretinin 20x

ICC

Plasmatrombin

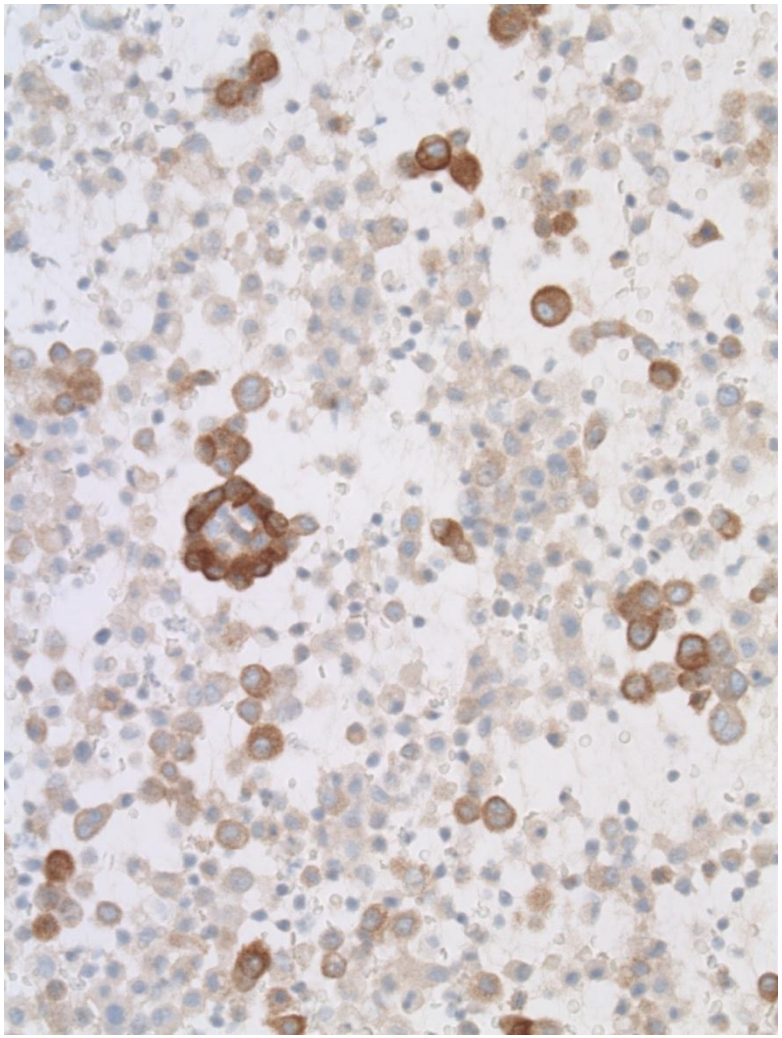

Cellient

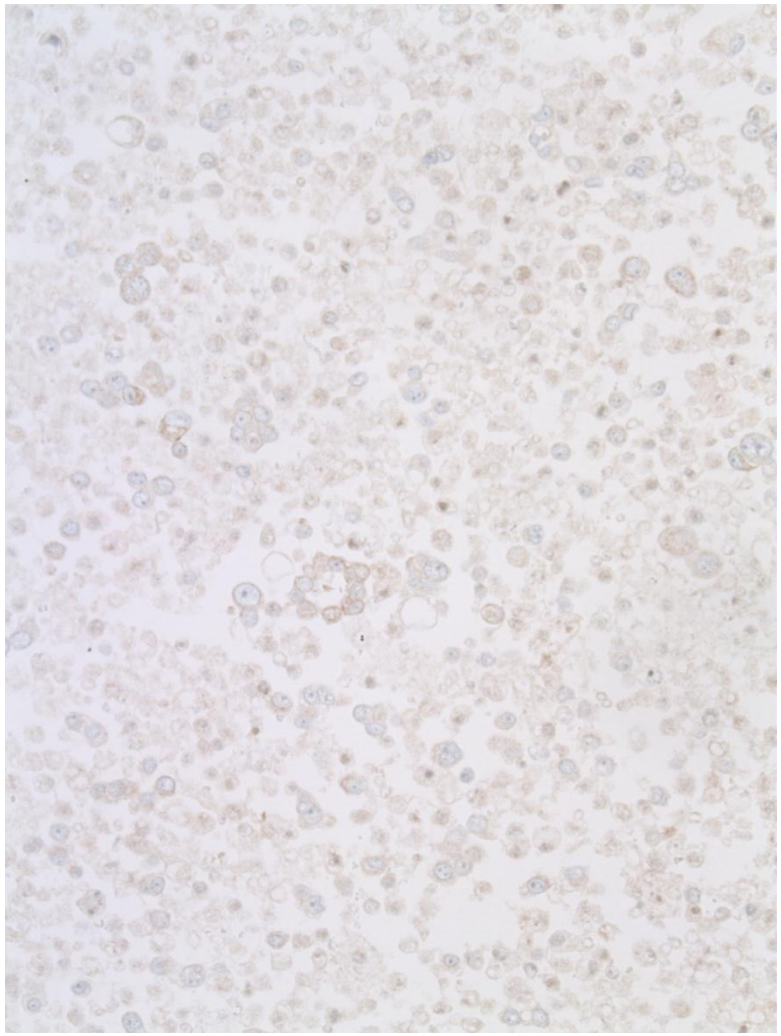

EMA 20x

ICC

Plasmatrombin

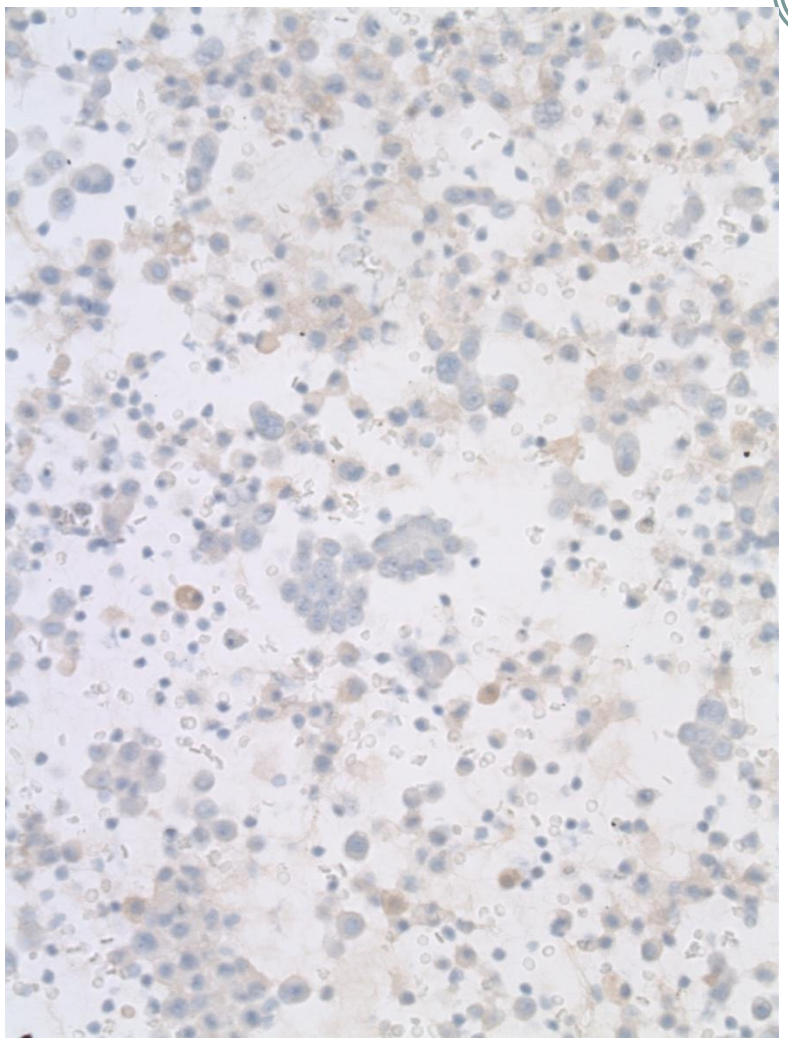

Cellient

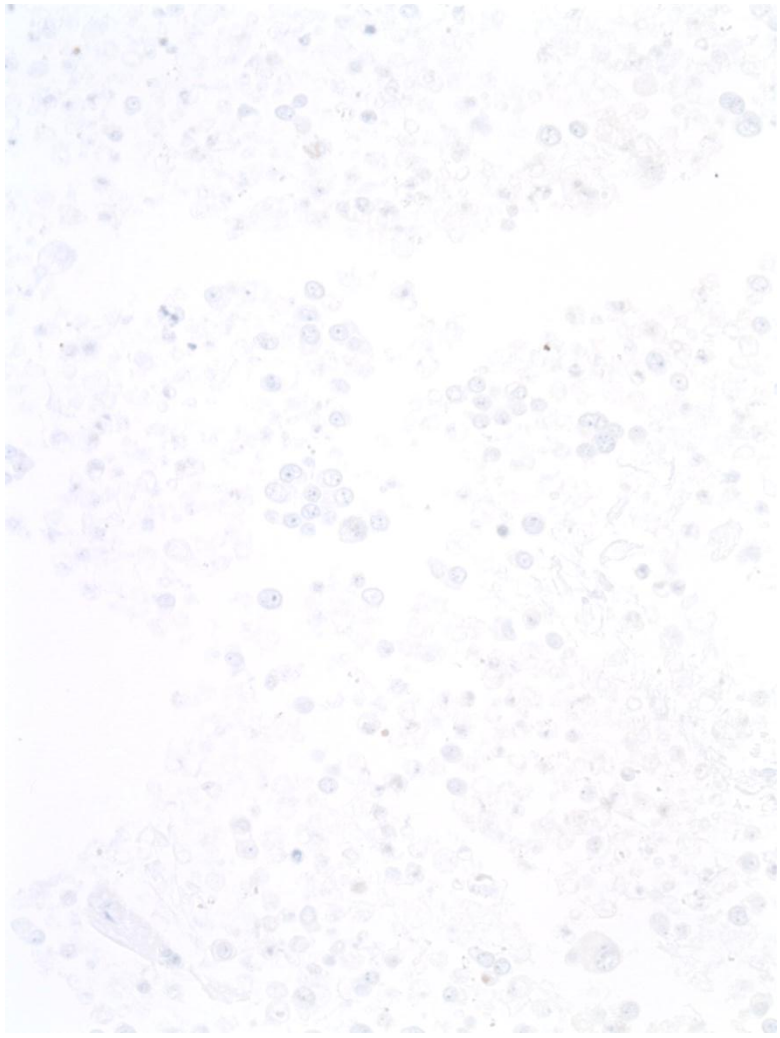

TTF-1 20x

Diagnose

MALIGNE CELLER MED MESOTELCELLEPRÆG

– STÆRK MISTANKE OM **MALIGNT MESOTELIOM**, MEN FORANDRINGERNE BØR VERIFICERES HISTOLOGISK.