Case

77 årig kvinde med højresidigt pleuraeksudat og stigende CA125.

Tidligere:

2006 ovariecancer

1989 invasivt lobulært mammakarcinom

Pleuravæske

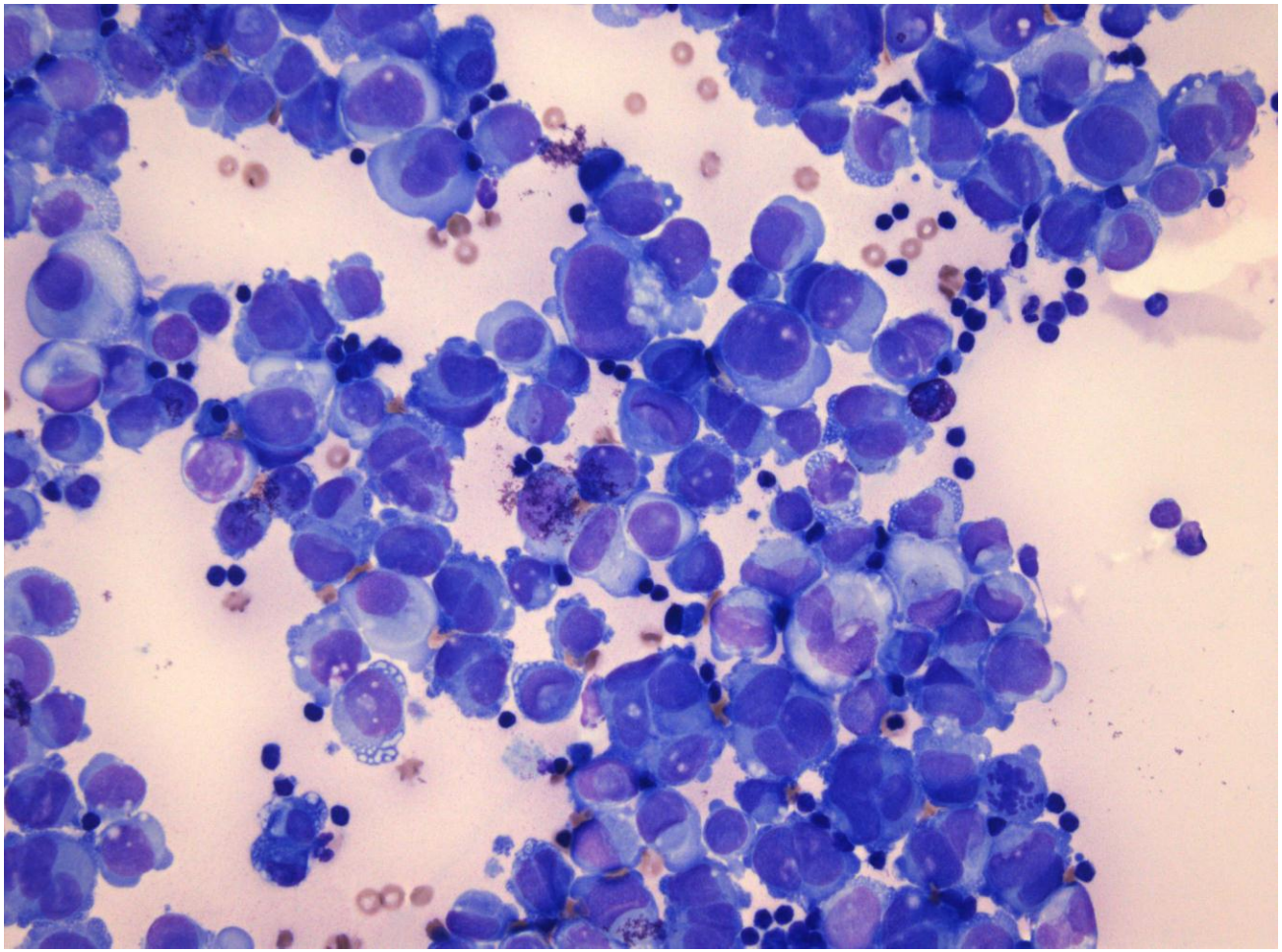

Pleuravæske

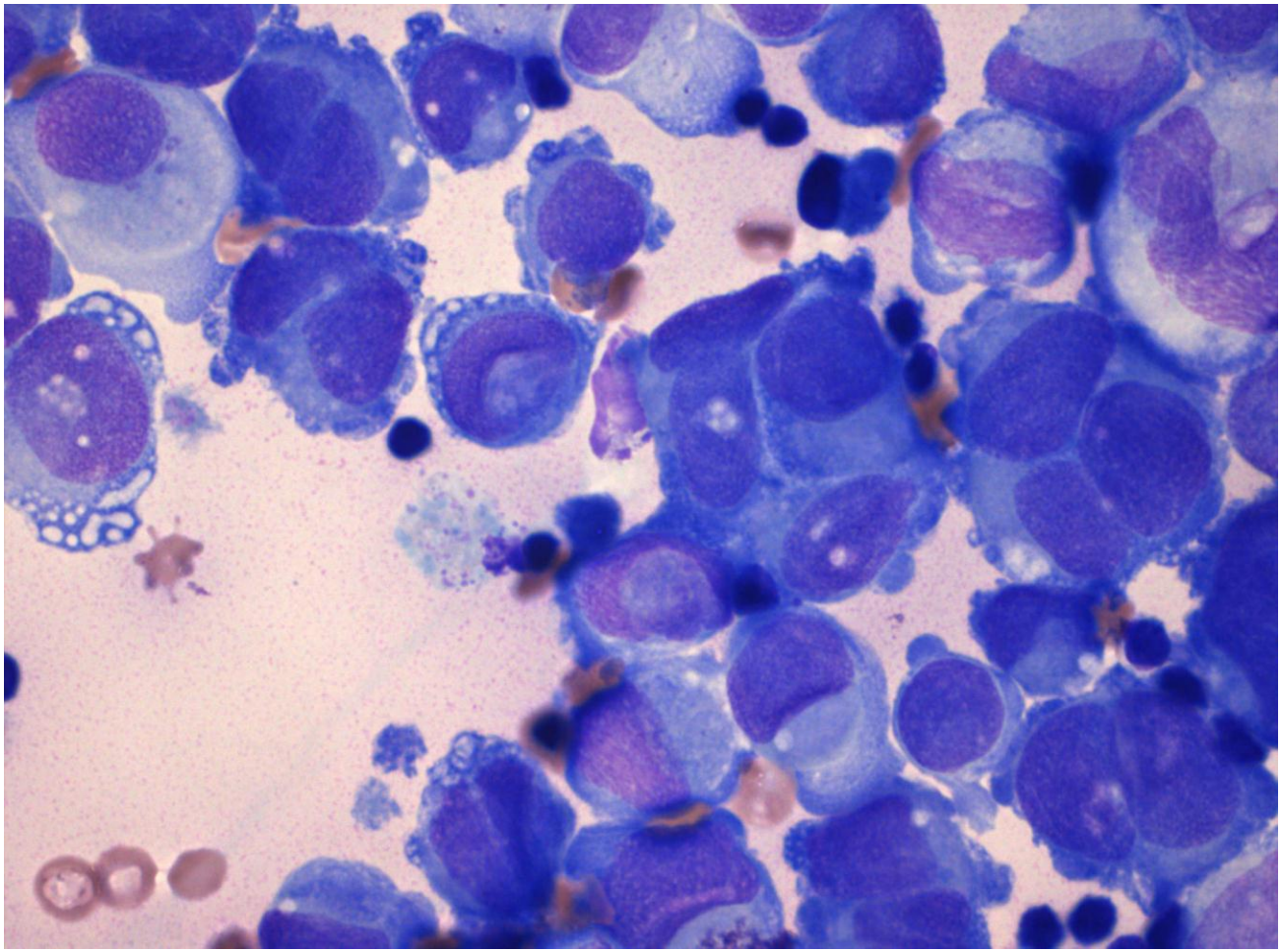

Pleuravæske

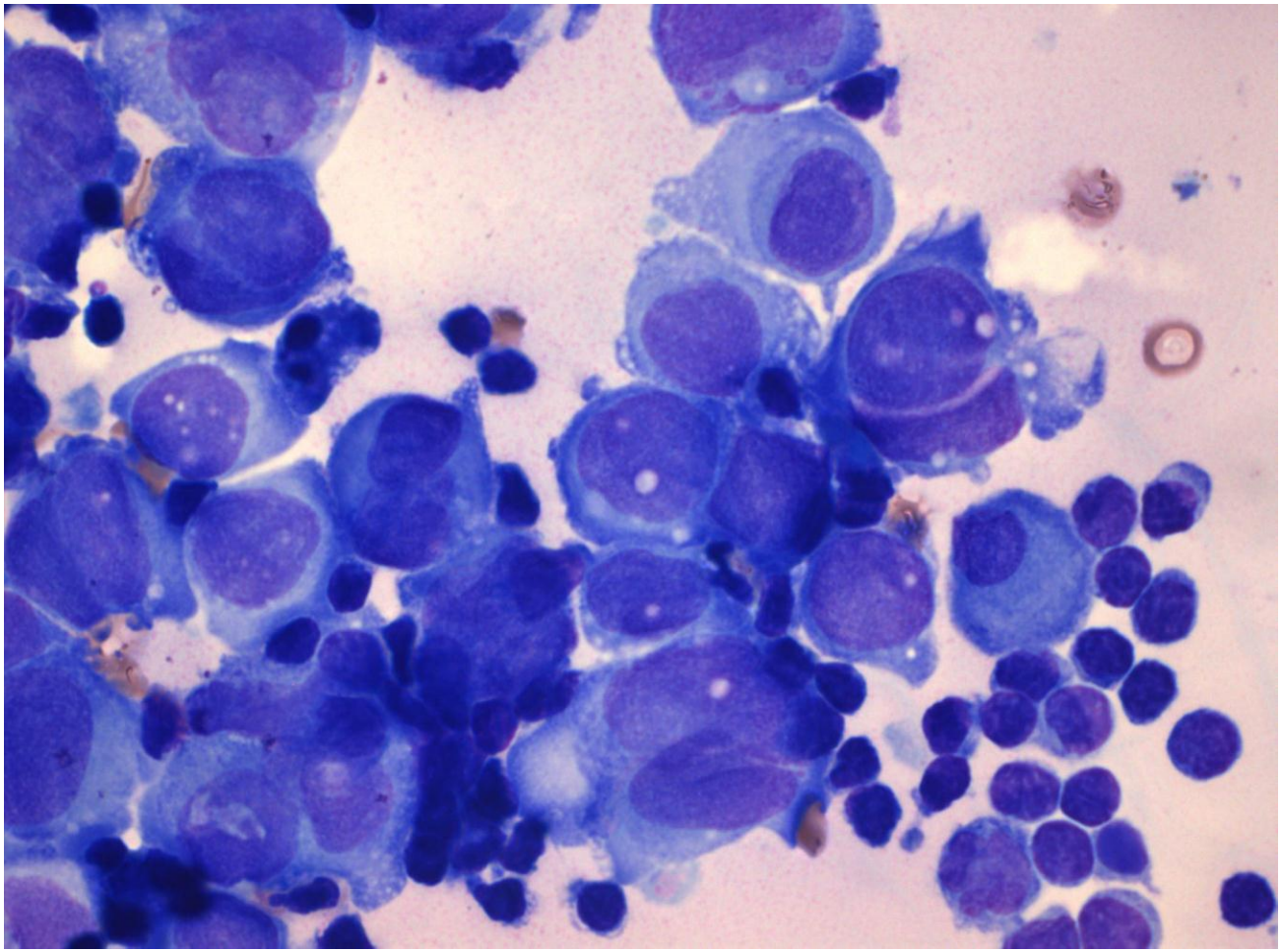

Pleuravæske,
HE snit af koaglet

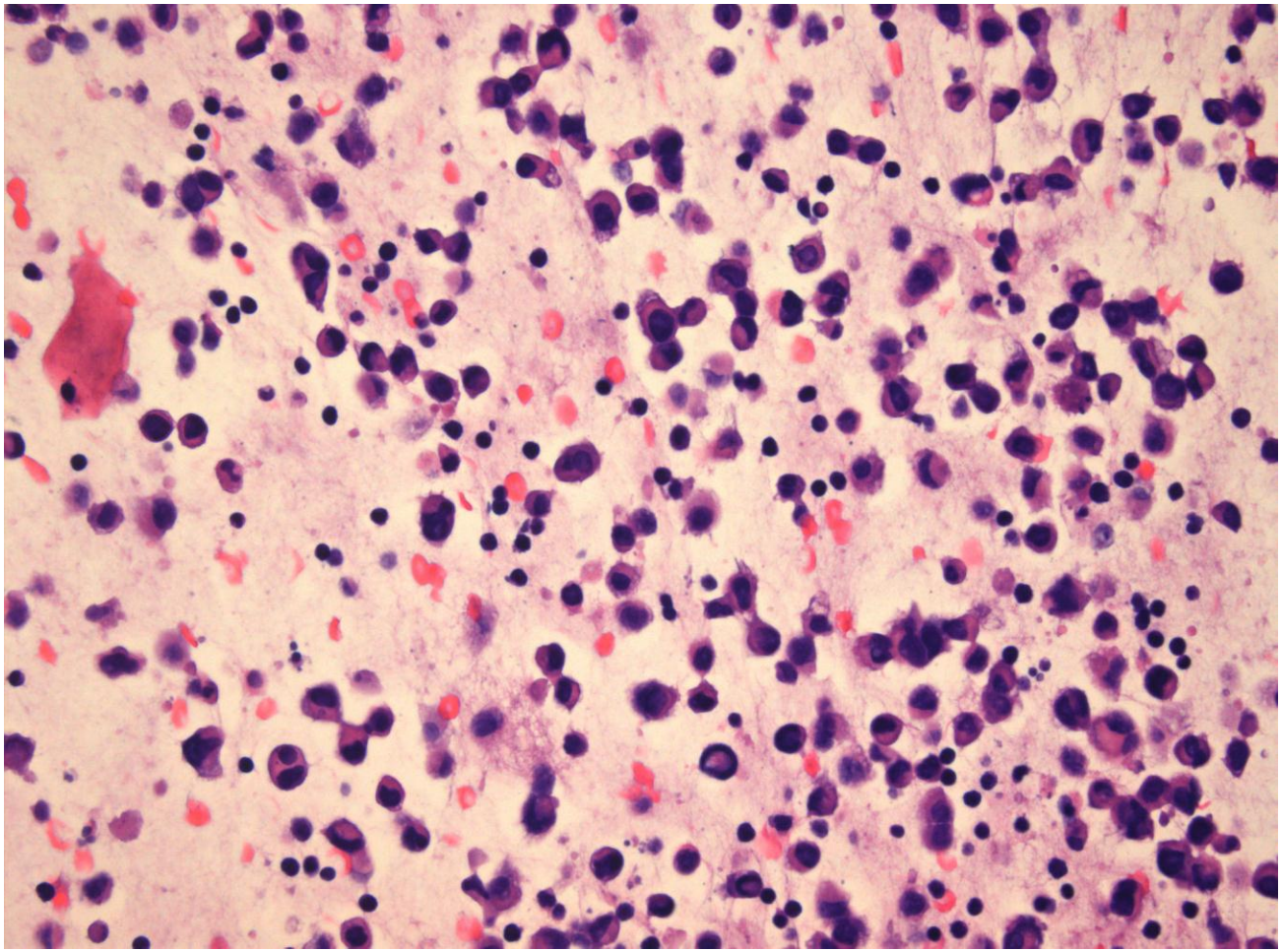

Pleuravæske, slimfarvning

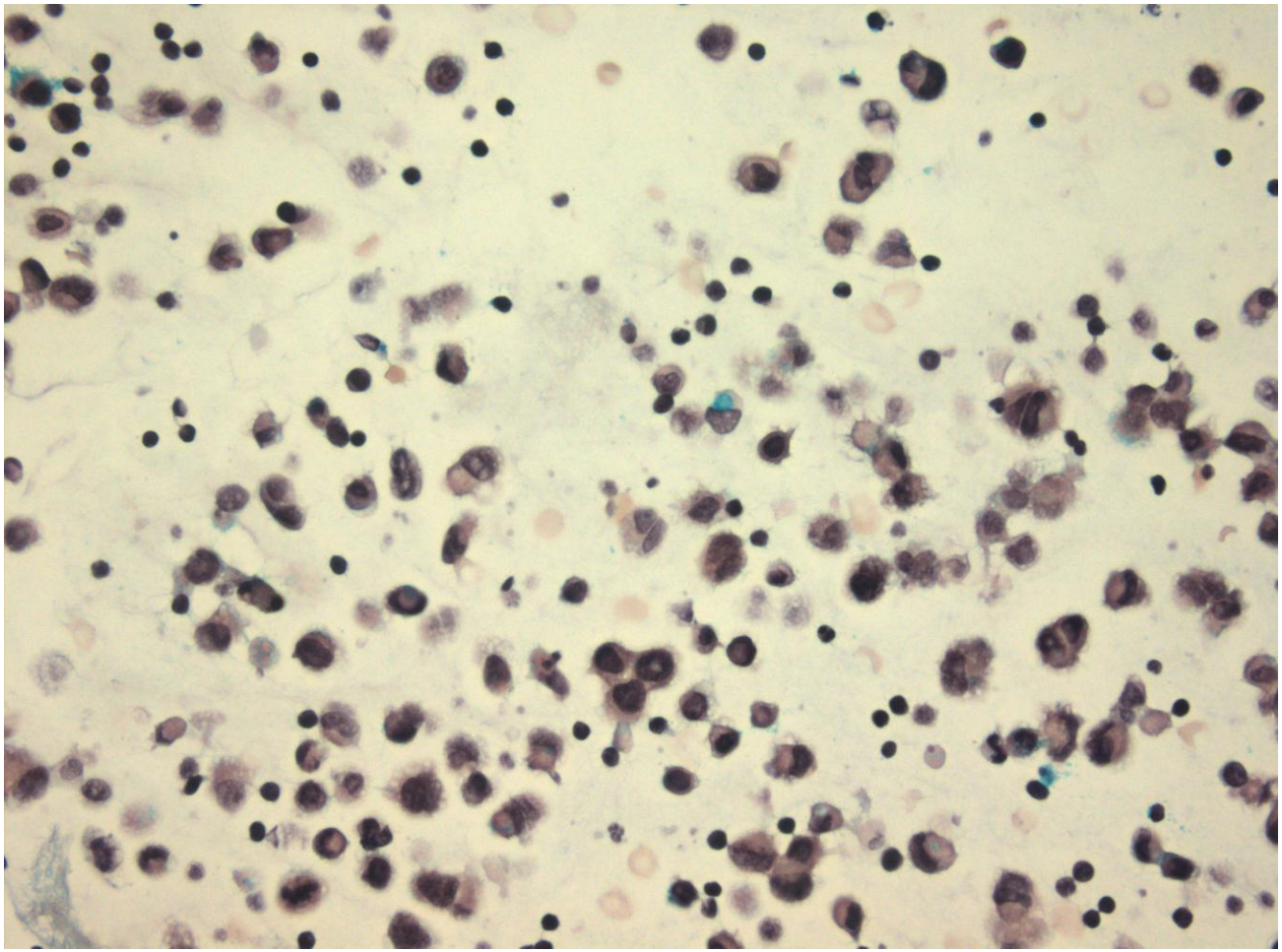

Slimfarvning

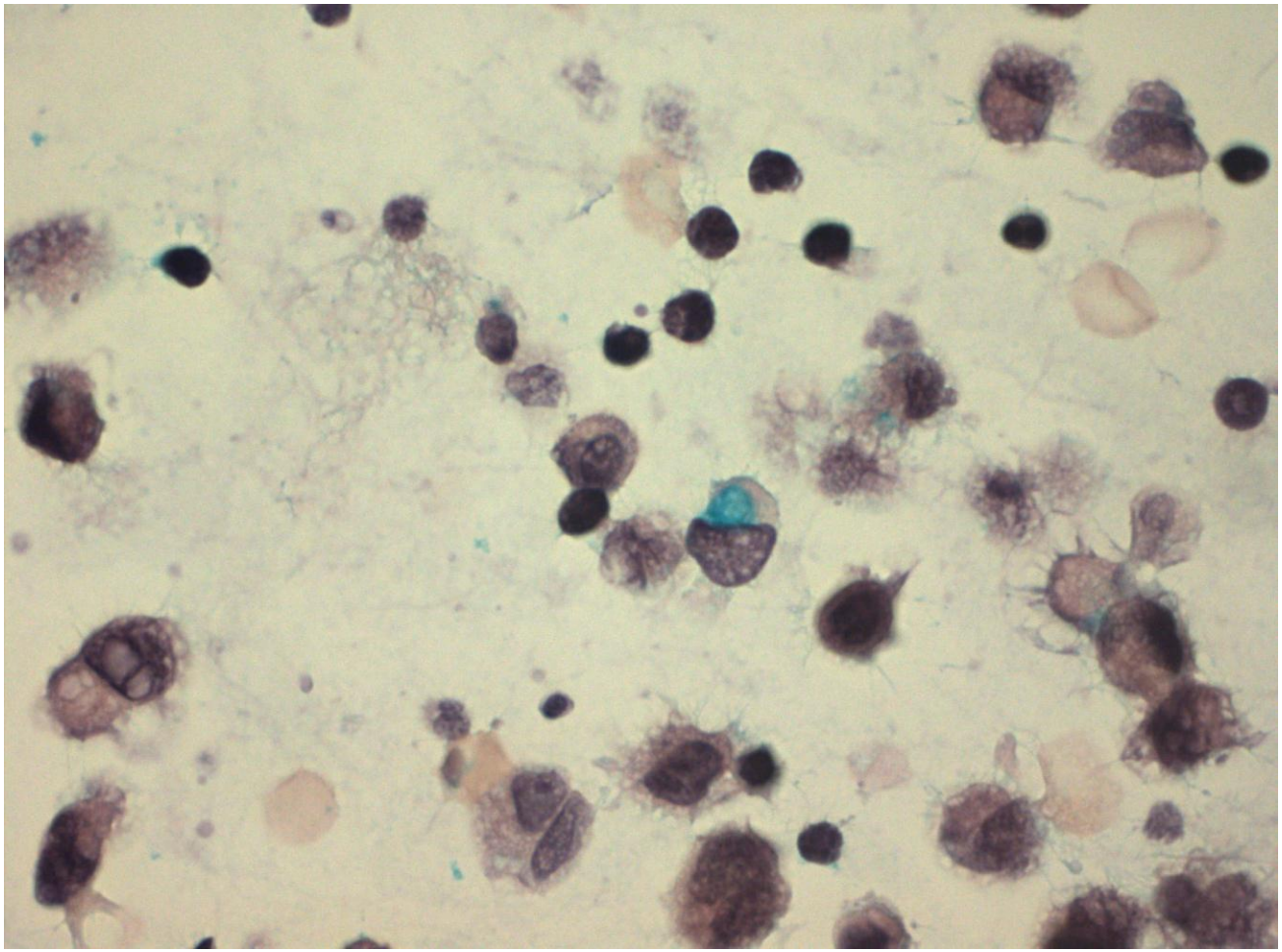

Pleuravæske, CK7 immunfarvning

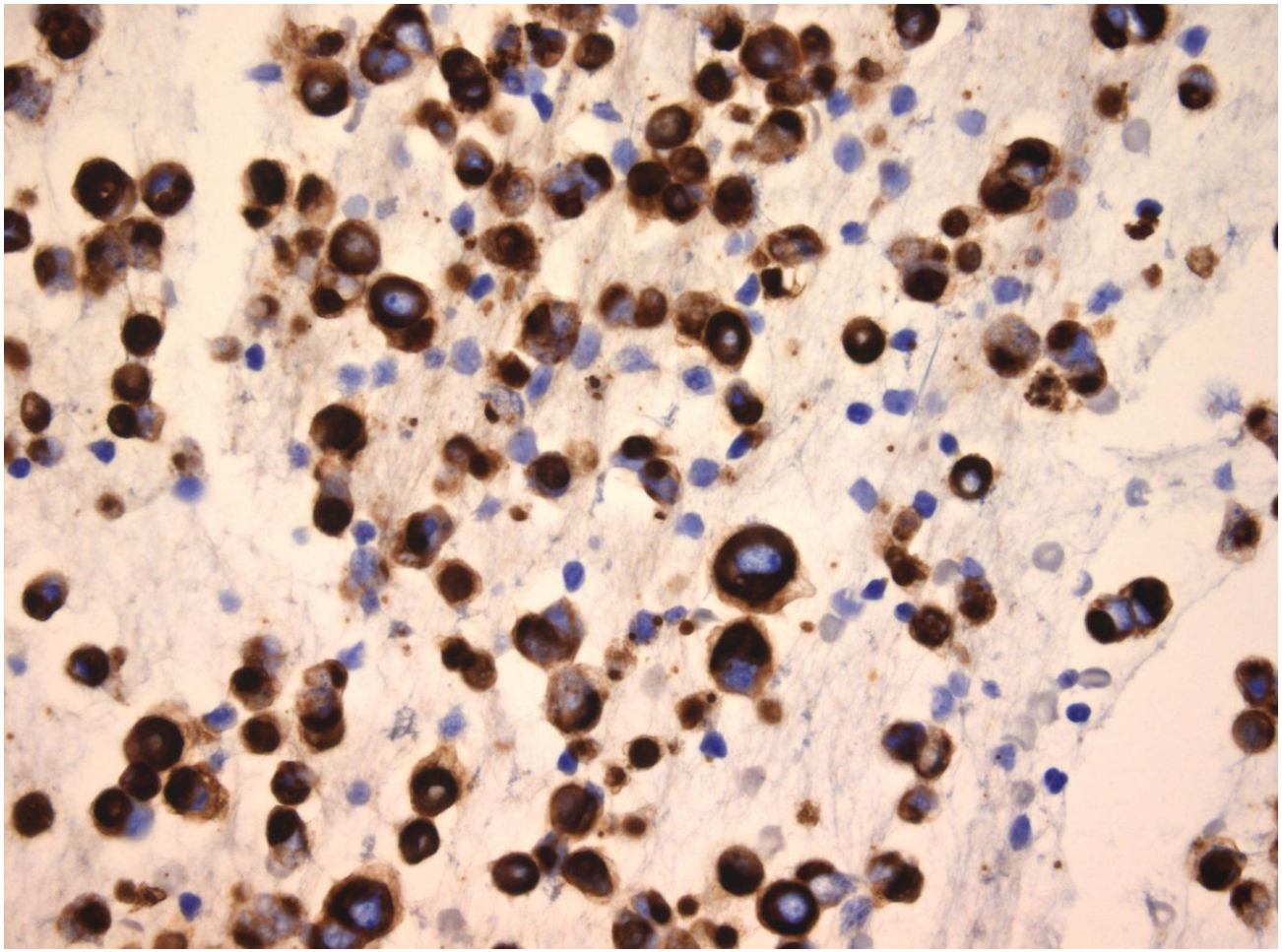

Pleuravæske, PAX8 immunfarvning

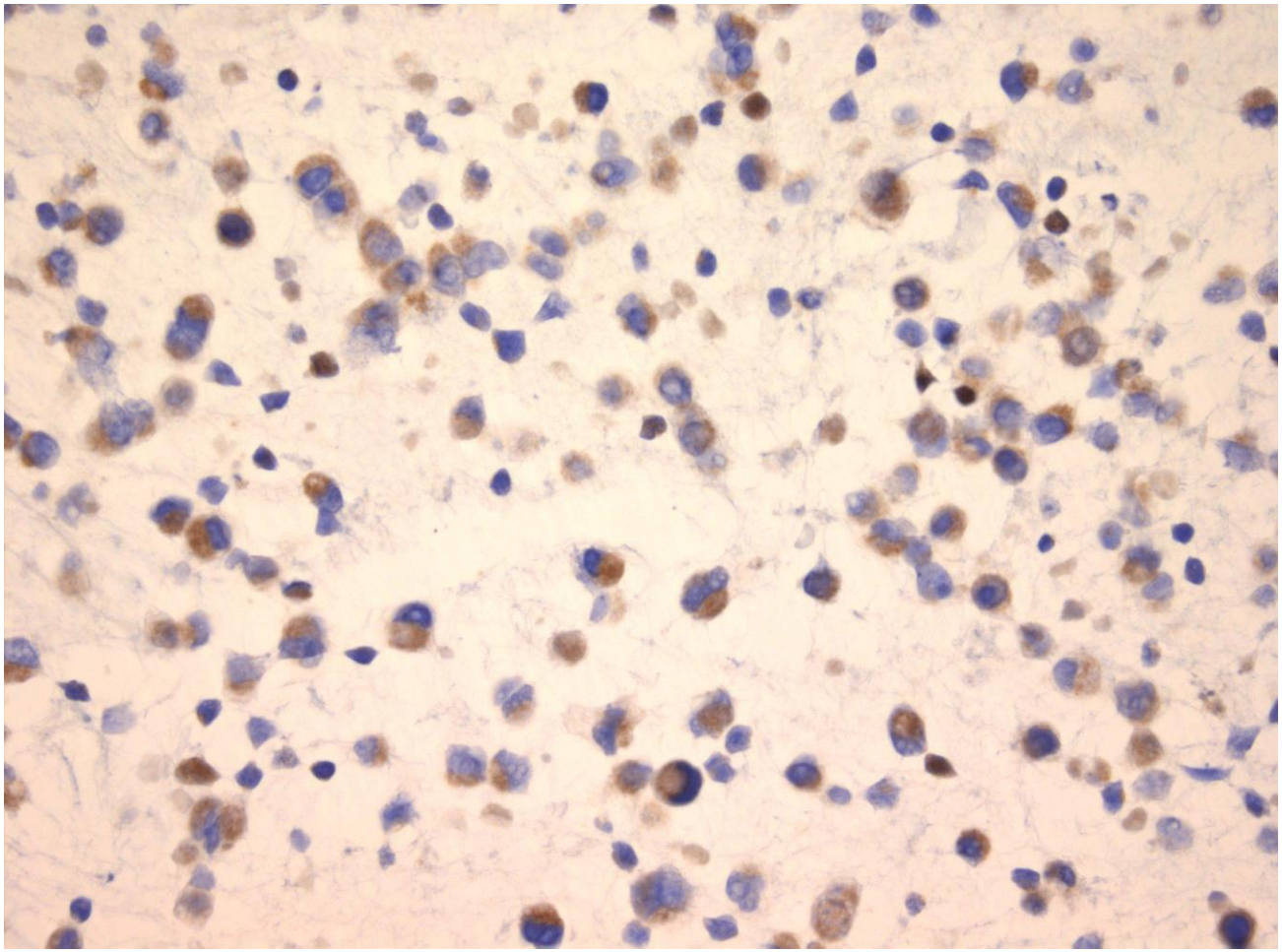

PAX8 (gynækologisk markør) er en kernefarvning, derfor uspecifik cytoplasmareaktion!

Pleuravæske, østrogenreceptor farvning

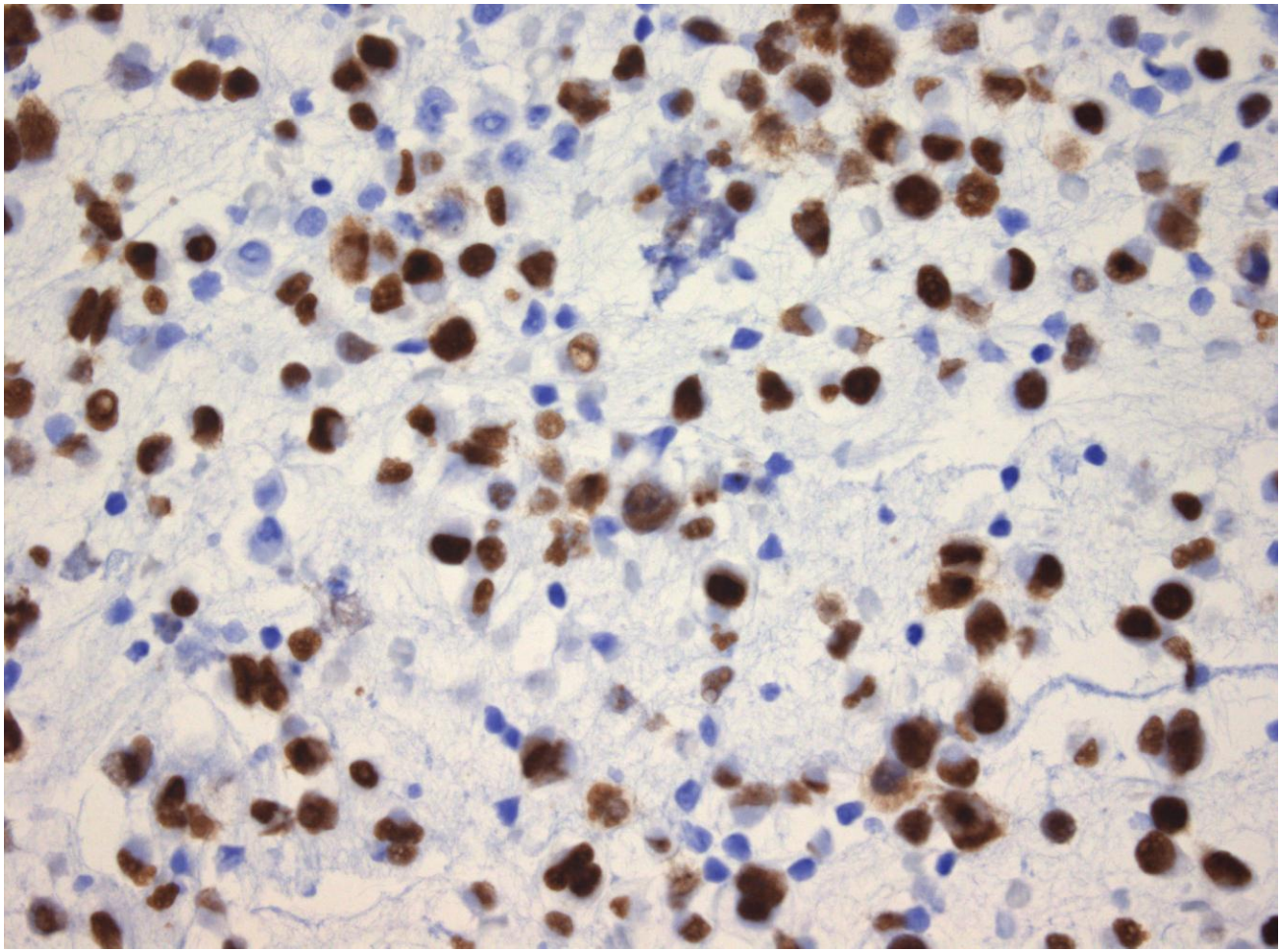

Øvrige immunresultater

- Tumorcellerne negative for: WT1, CA125, Ecadherin, GCDFP15, calretinin, CEA, TTF1, CK20, P53, S100, vimentin, MPO, CD34 og TdT.

Diagnose?

- Lymfom/leukæmisk sygdom?
- Metastase fra lungecancer?
- Metastase fra ovariecancer?
- Metastase fra lobulært mammakarcinom?

Diagnose: metastase fra invasivt lobulært mammakarcinom

- Pleuravæske: små dissocierede tumorceller uden særlig nukleoletegning, enkelte i små rækker,hvor kerner tager form efter hinanden, enkelte med intracytoplasmatiske mucinvakuoler.
- Immunprofil: positivitet for Cytokeratin 7 og østrogenreceptor

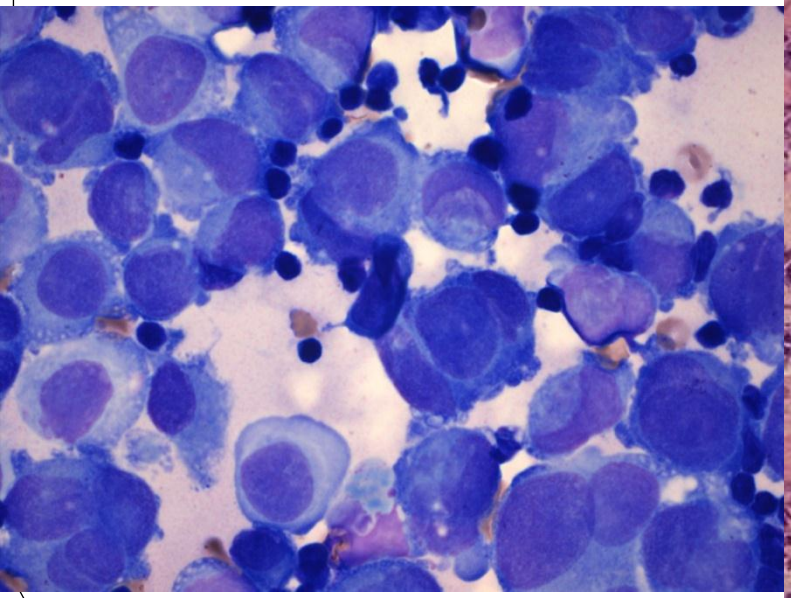

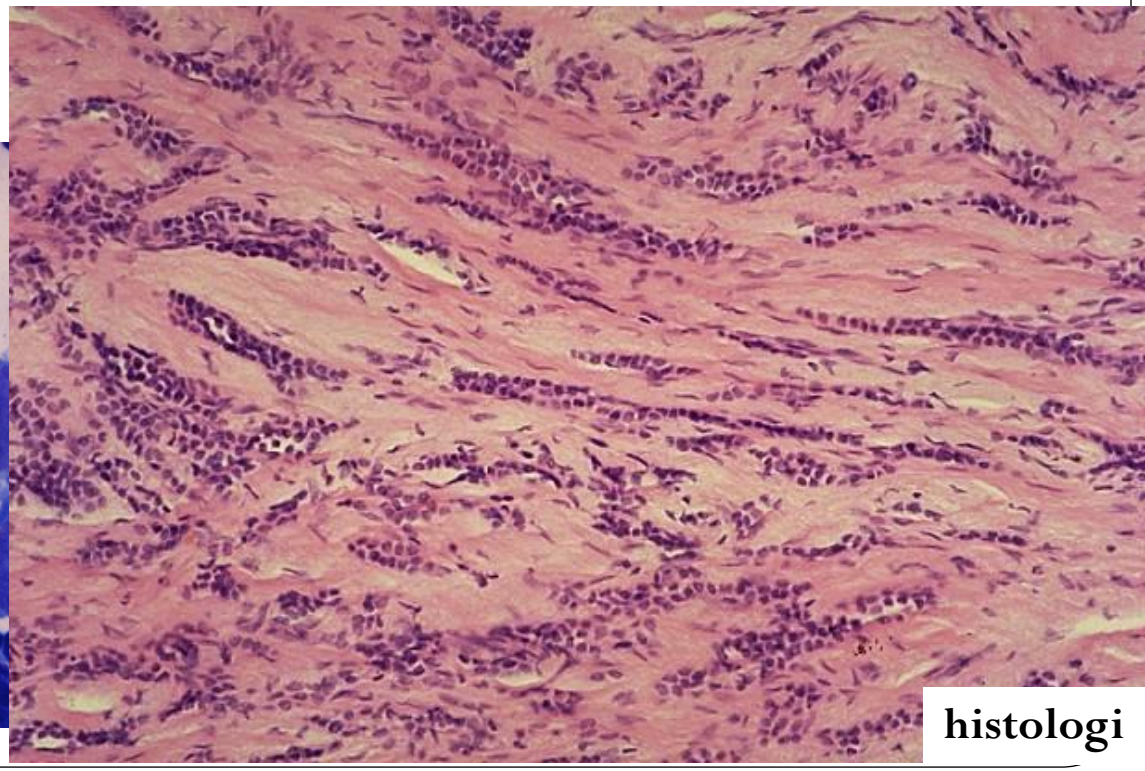

histologi