Case 3.

68 årig kvinde.

Kliniske oplysninger: Ascites væske. Udfyldning i det lille bækken

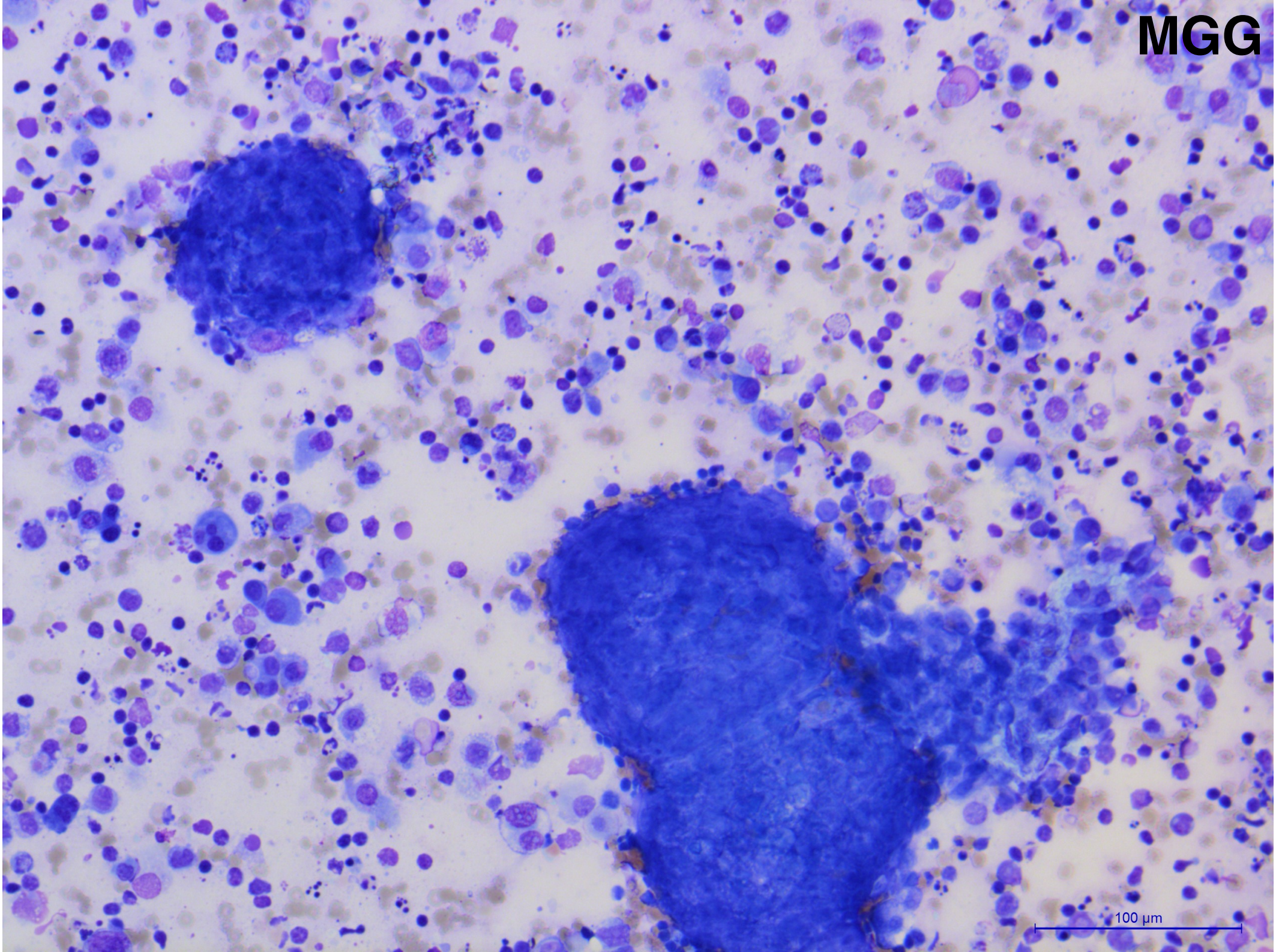
MGG
100 µm

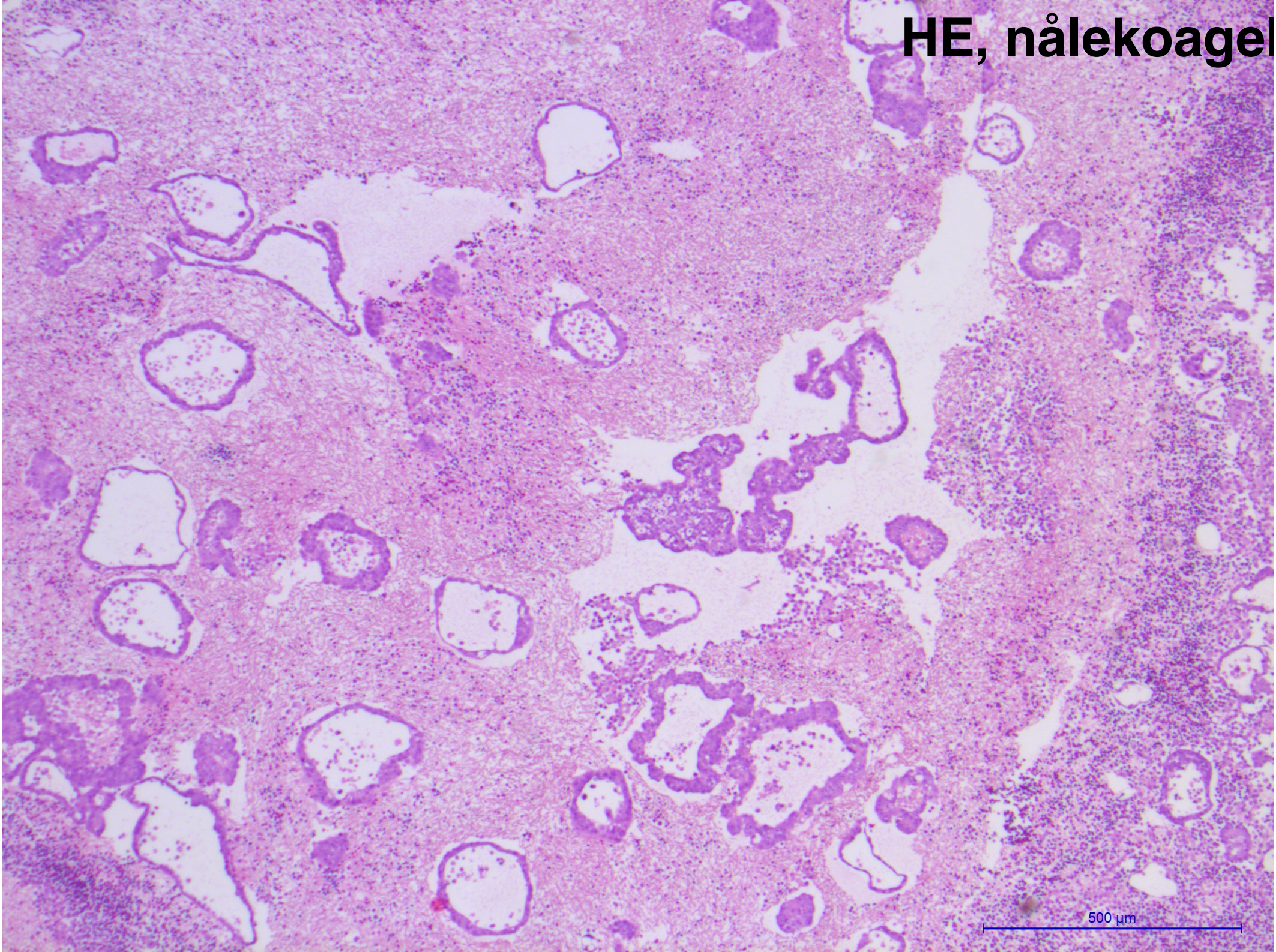
HE, nålekoagel
500 µm

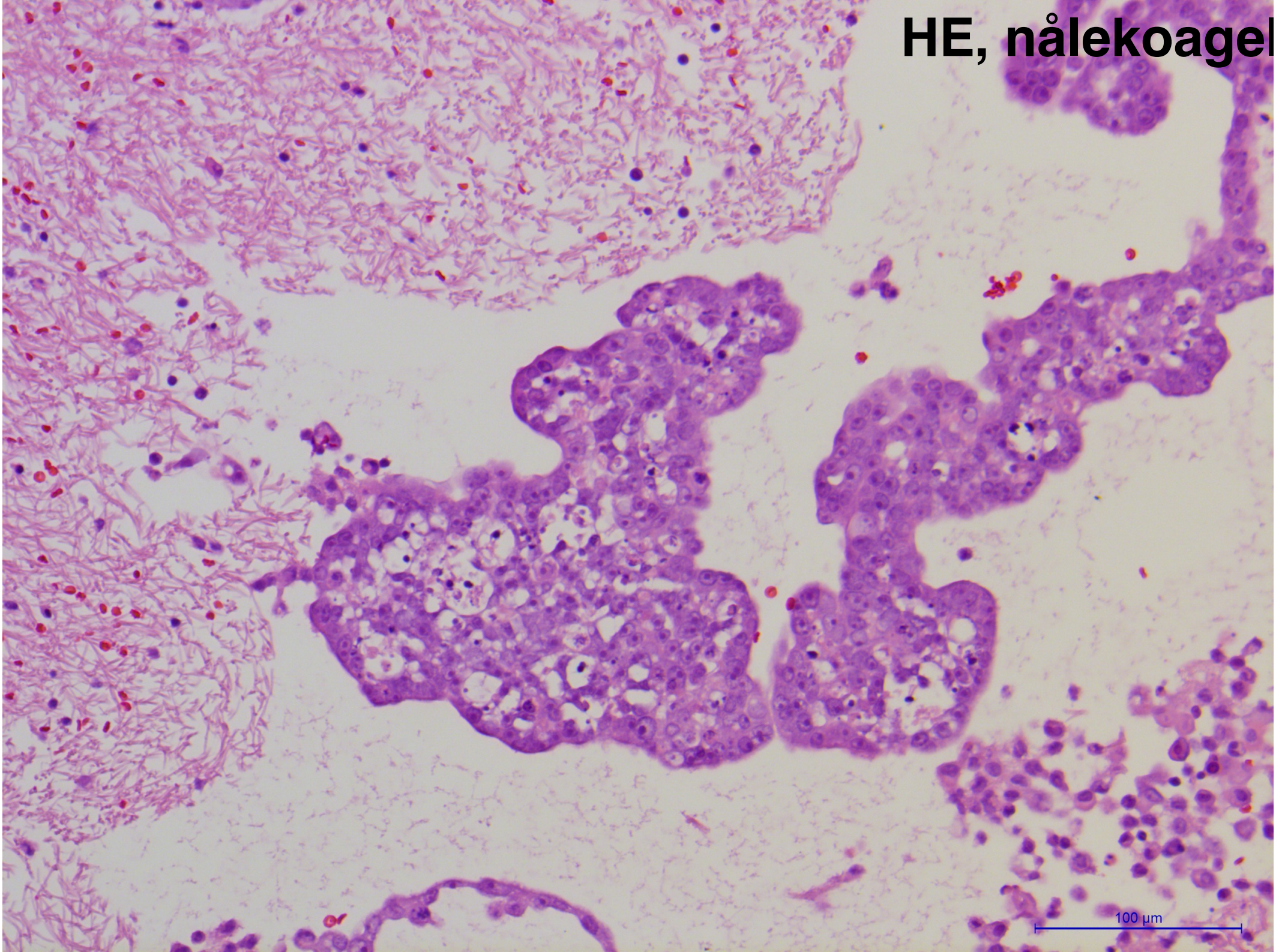
HE, nålekoagel
100 µm

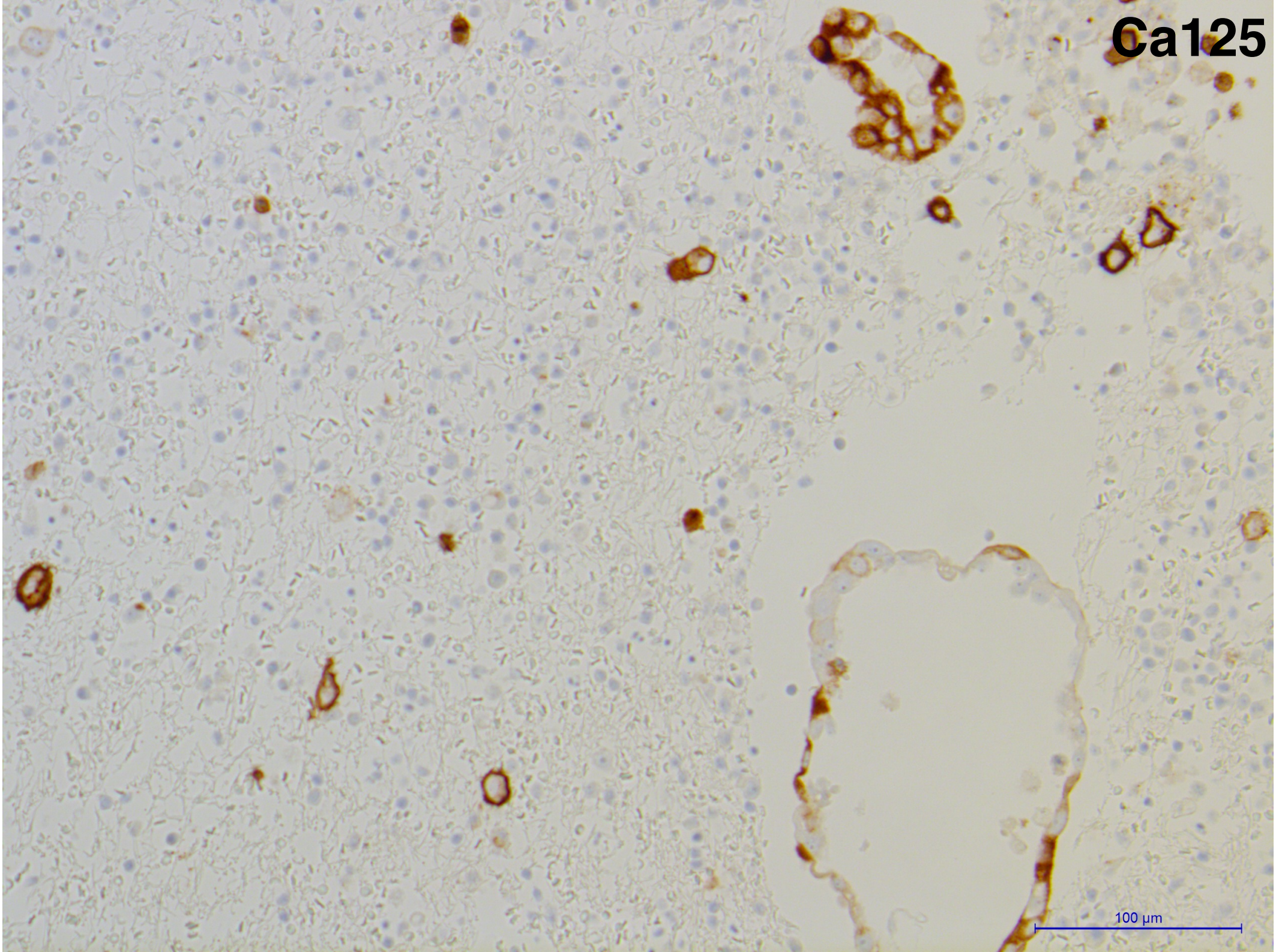
Ca125
100 µm

Diagnoseforslag ? evt. yderligere immuner.