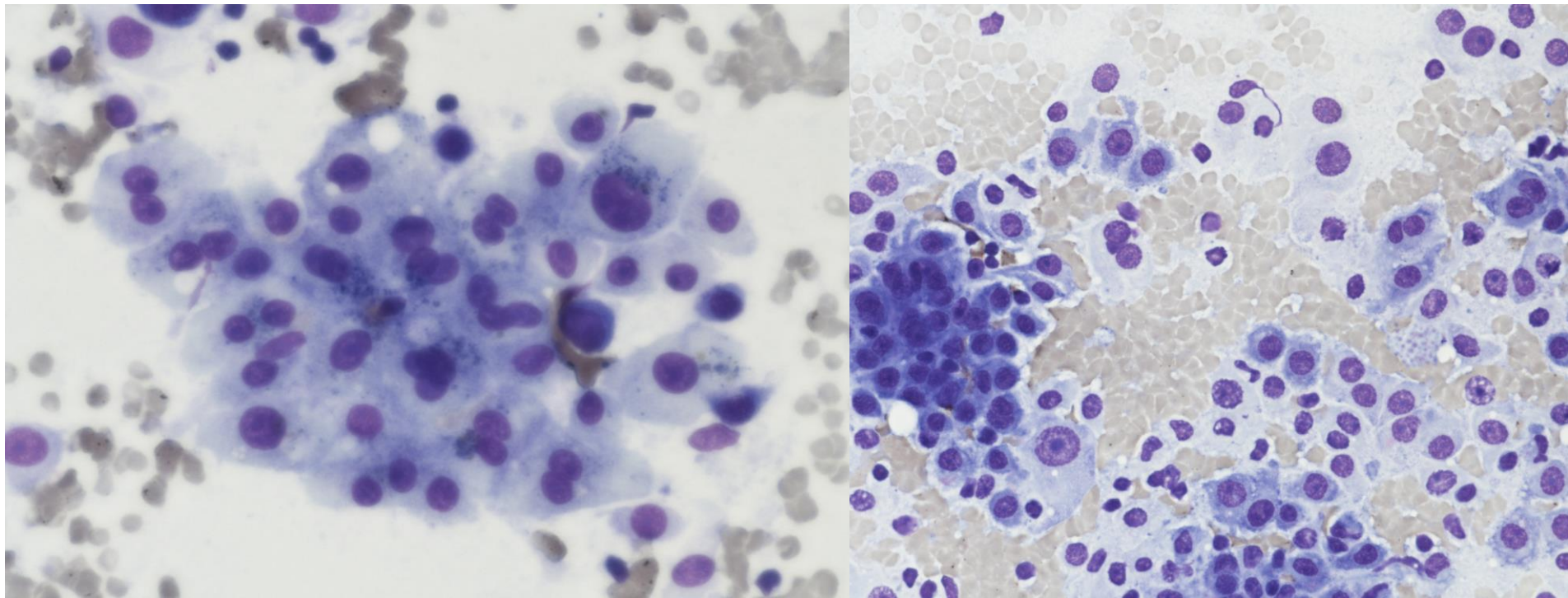


Case 3: FNA fra 13mm proces i lever. 75 år mand.



FNA udstrygning MGG