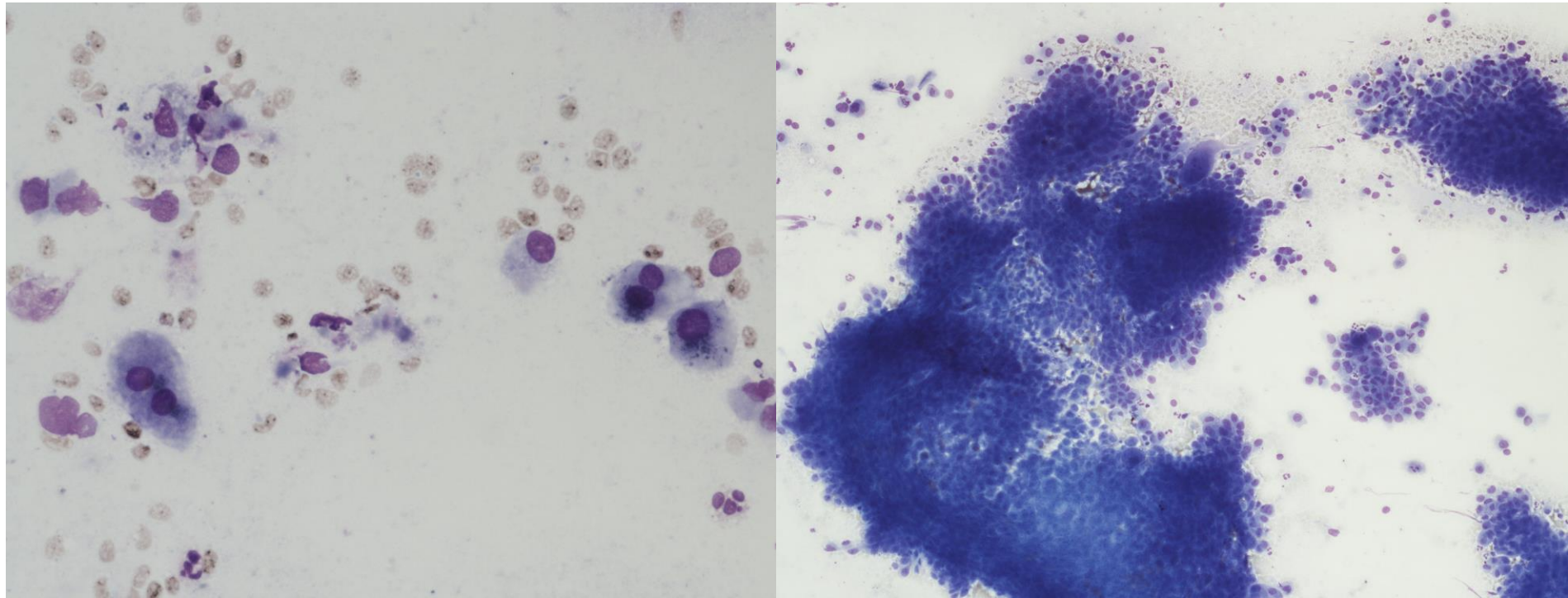
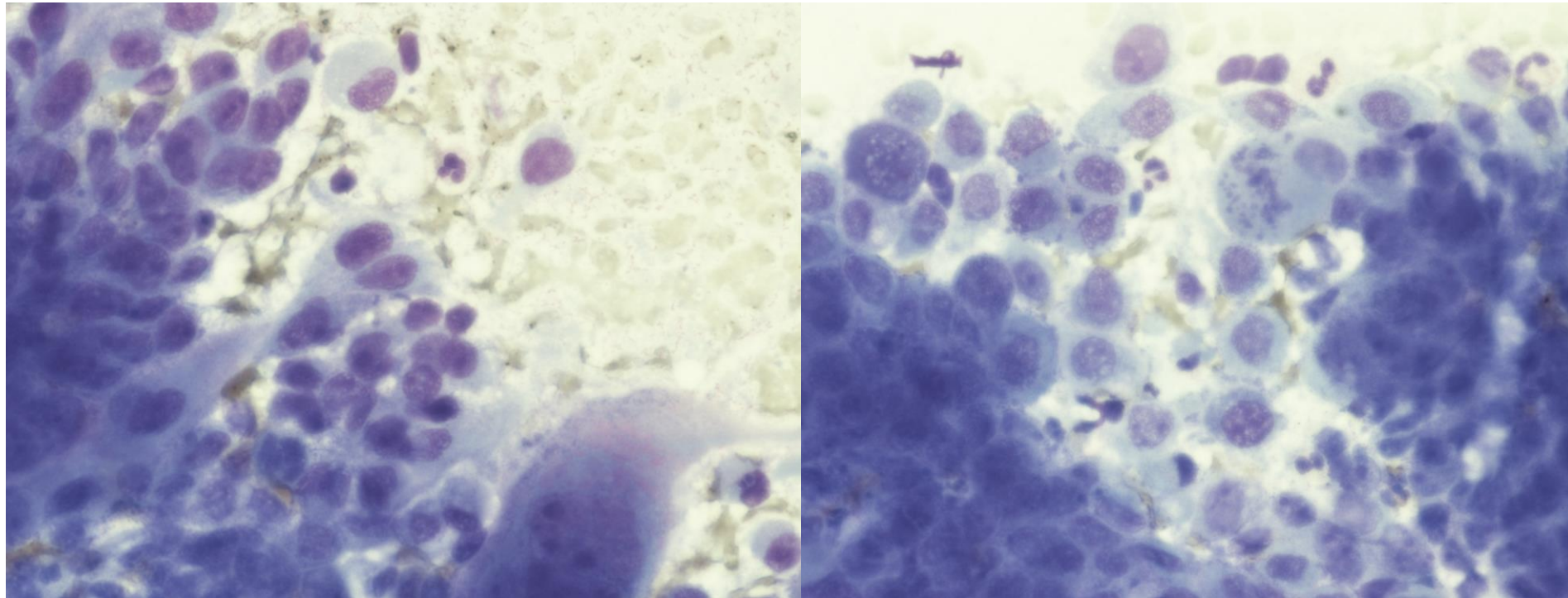


# Case 2: FNA lever. Central tumor i leveren med perifer galdevejsdilation. Mand 54 år.



FNA udstrygning MGG

# Case 2: FNA lever. Central tumor i leveren med perifer galdevejsdilation. Mand 54 år.



FNA udstrygning MGG