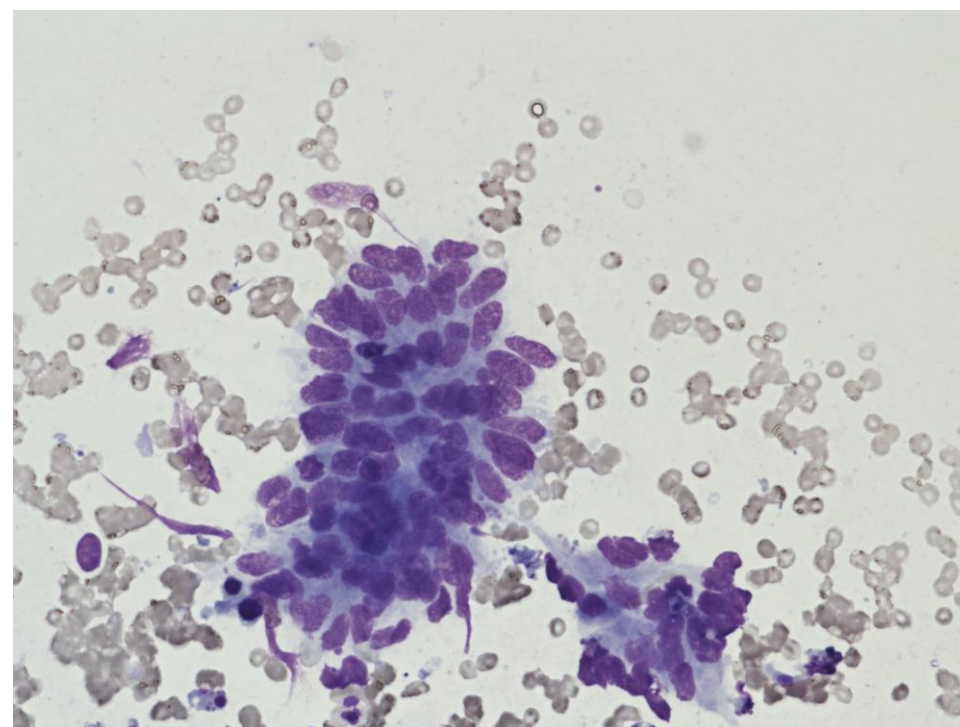
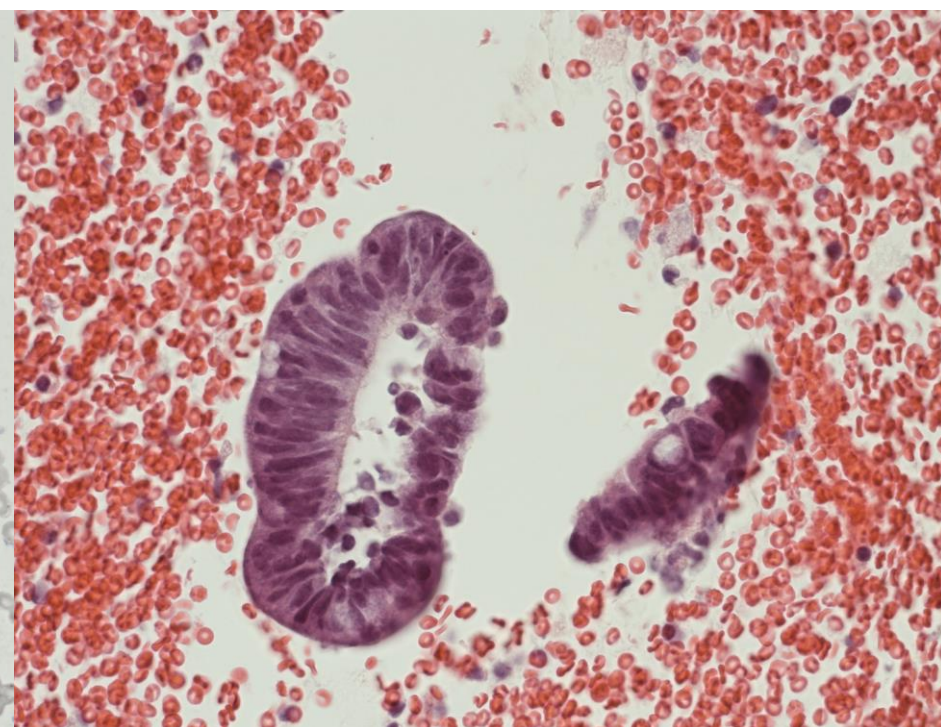

# Case 1: FNA proces i hø. leverlap. Mand 63 år.



FNA udstrygning MGG



FNA koagel HE