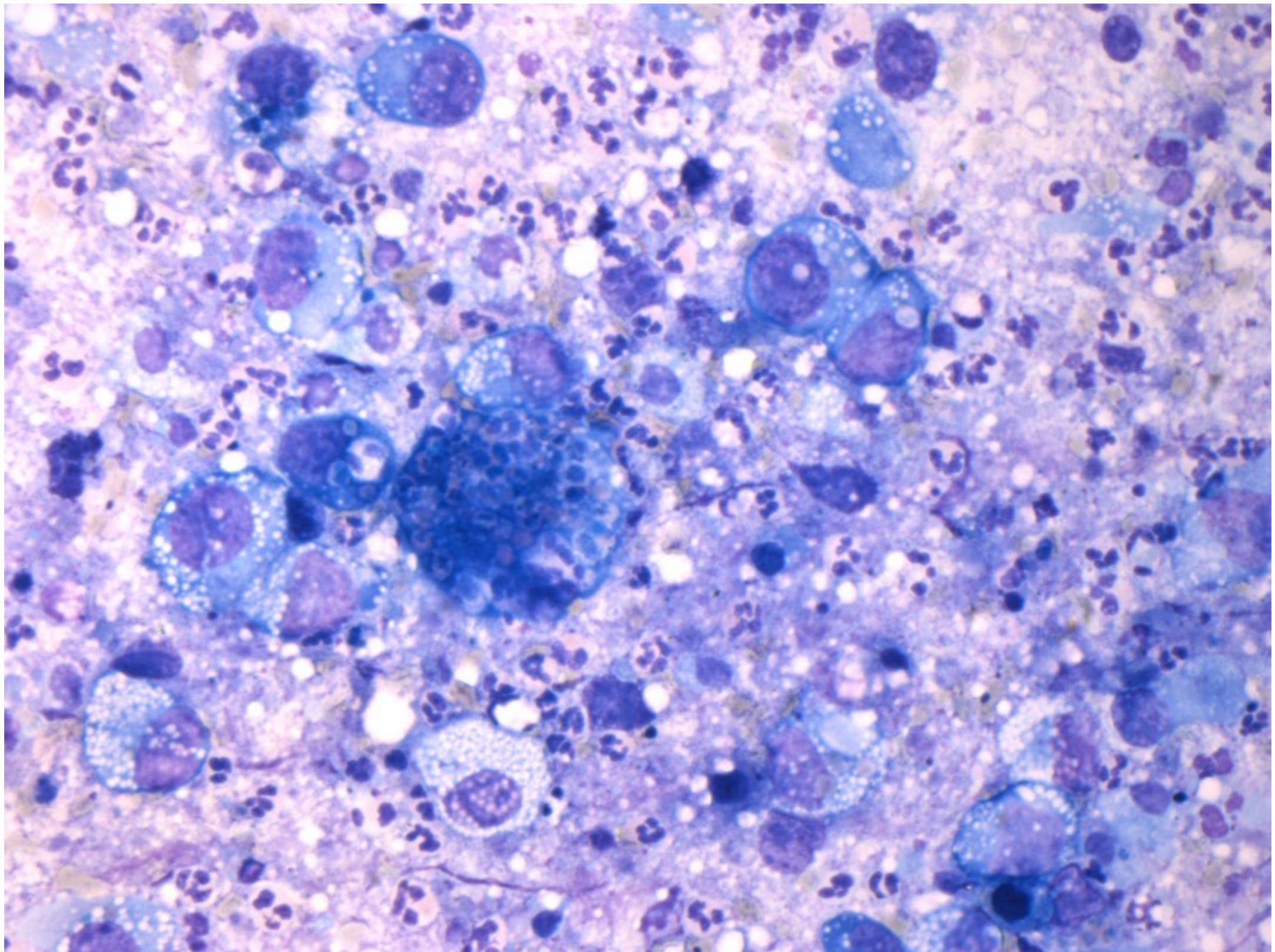
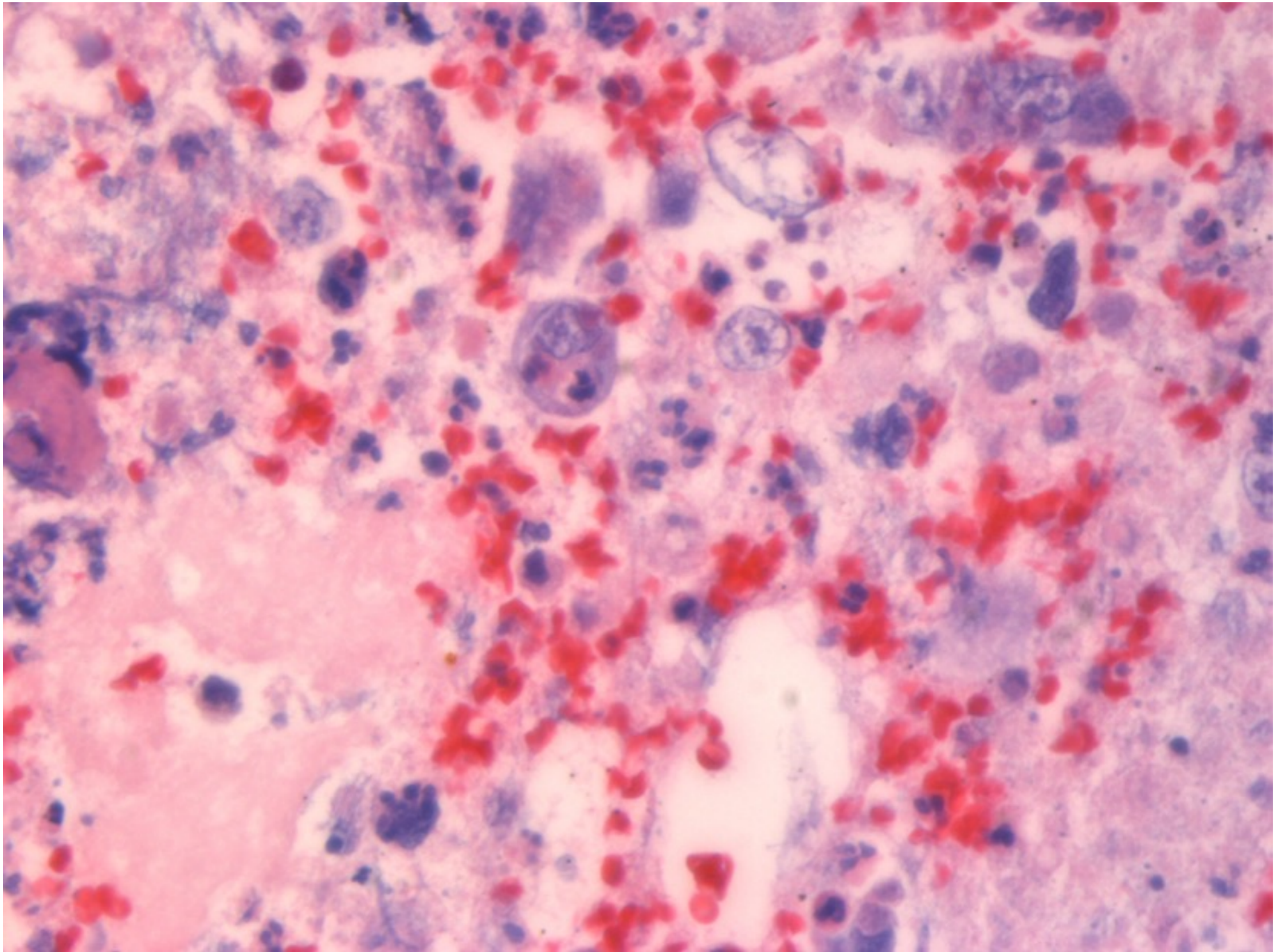


Kliniske oplysninger:

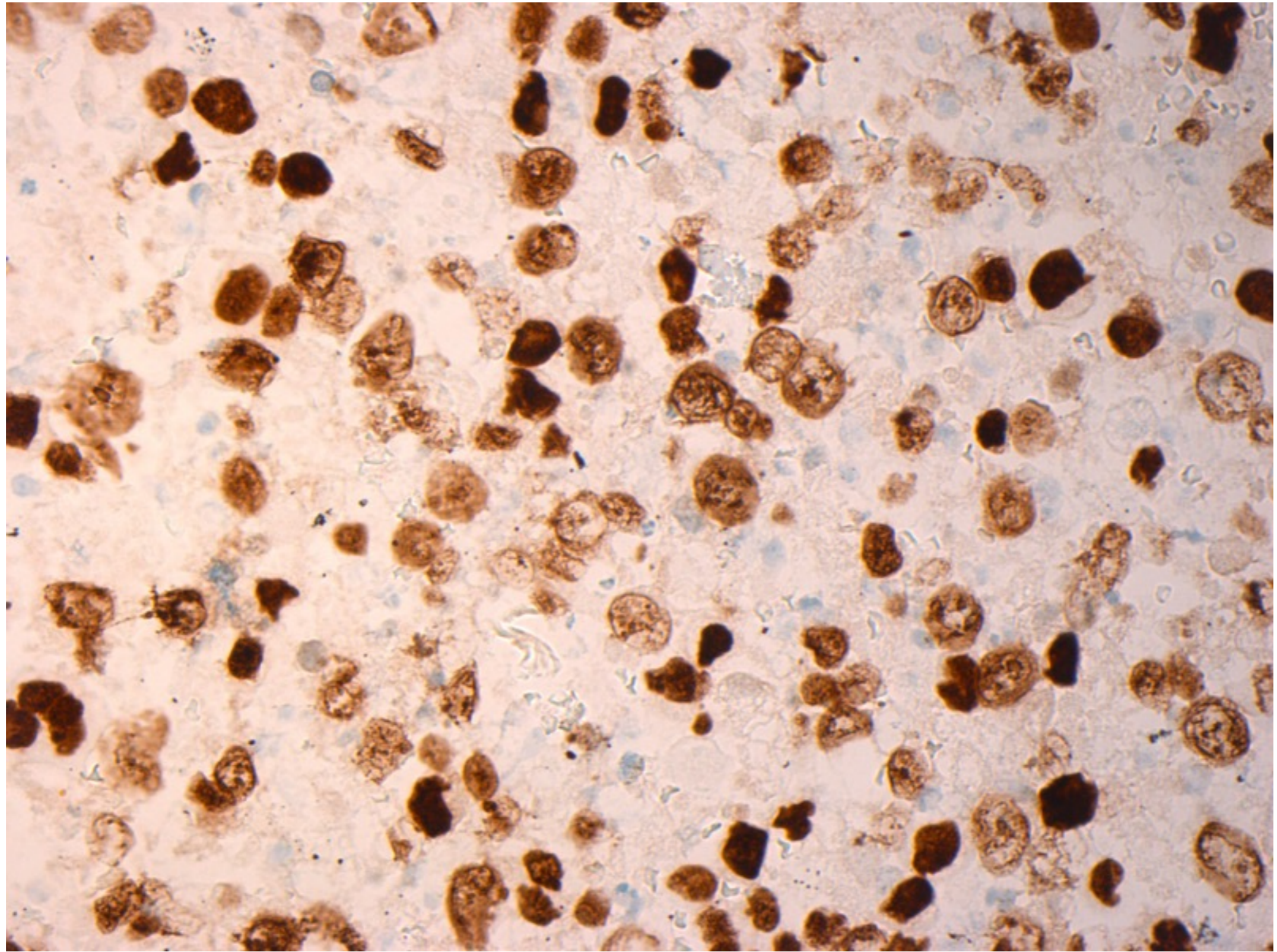
70 årig mand. Central lungetumor.
EBUS undersøgelse fra station 7.



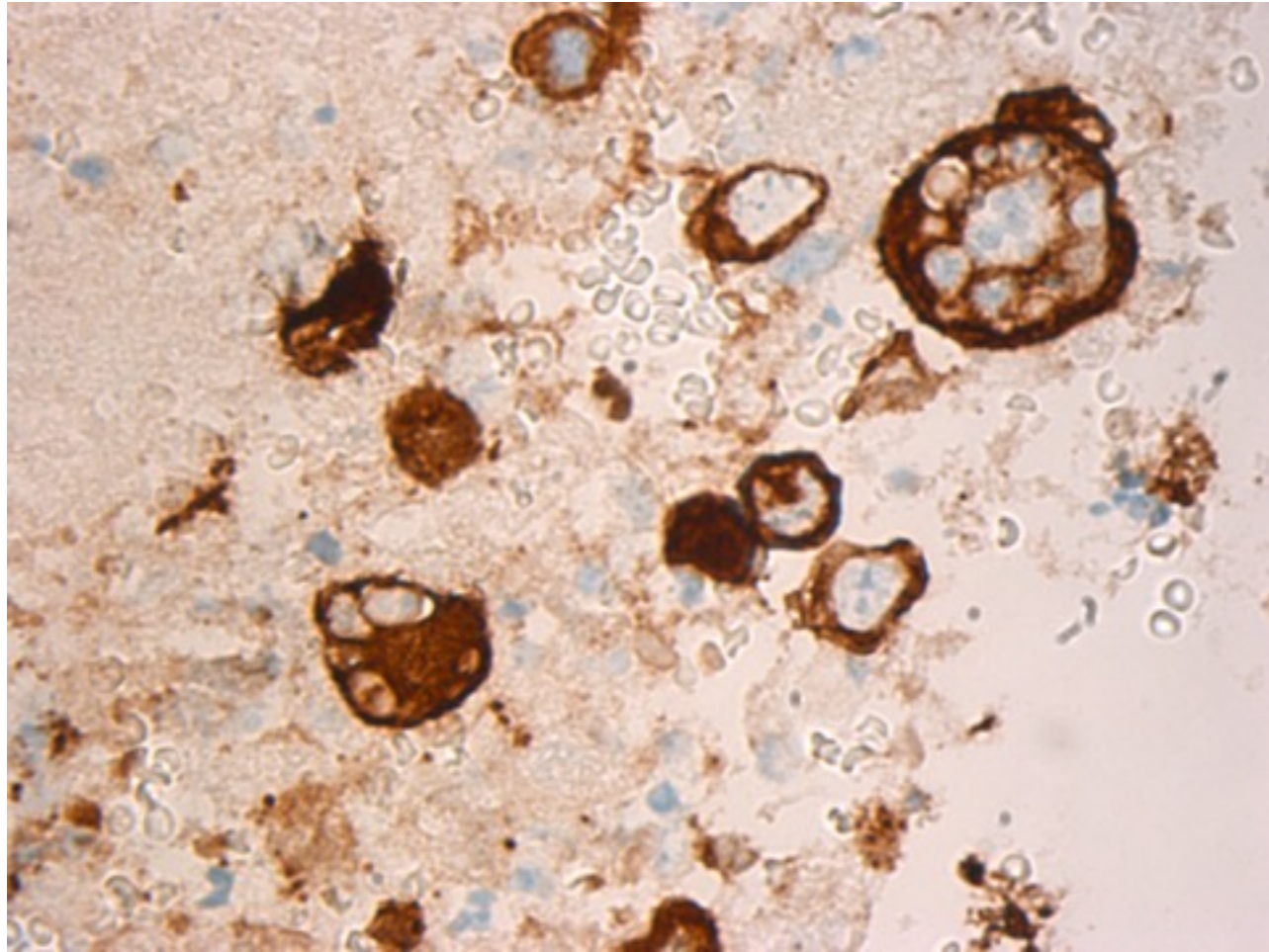
Udstrygning, giemsa x 63



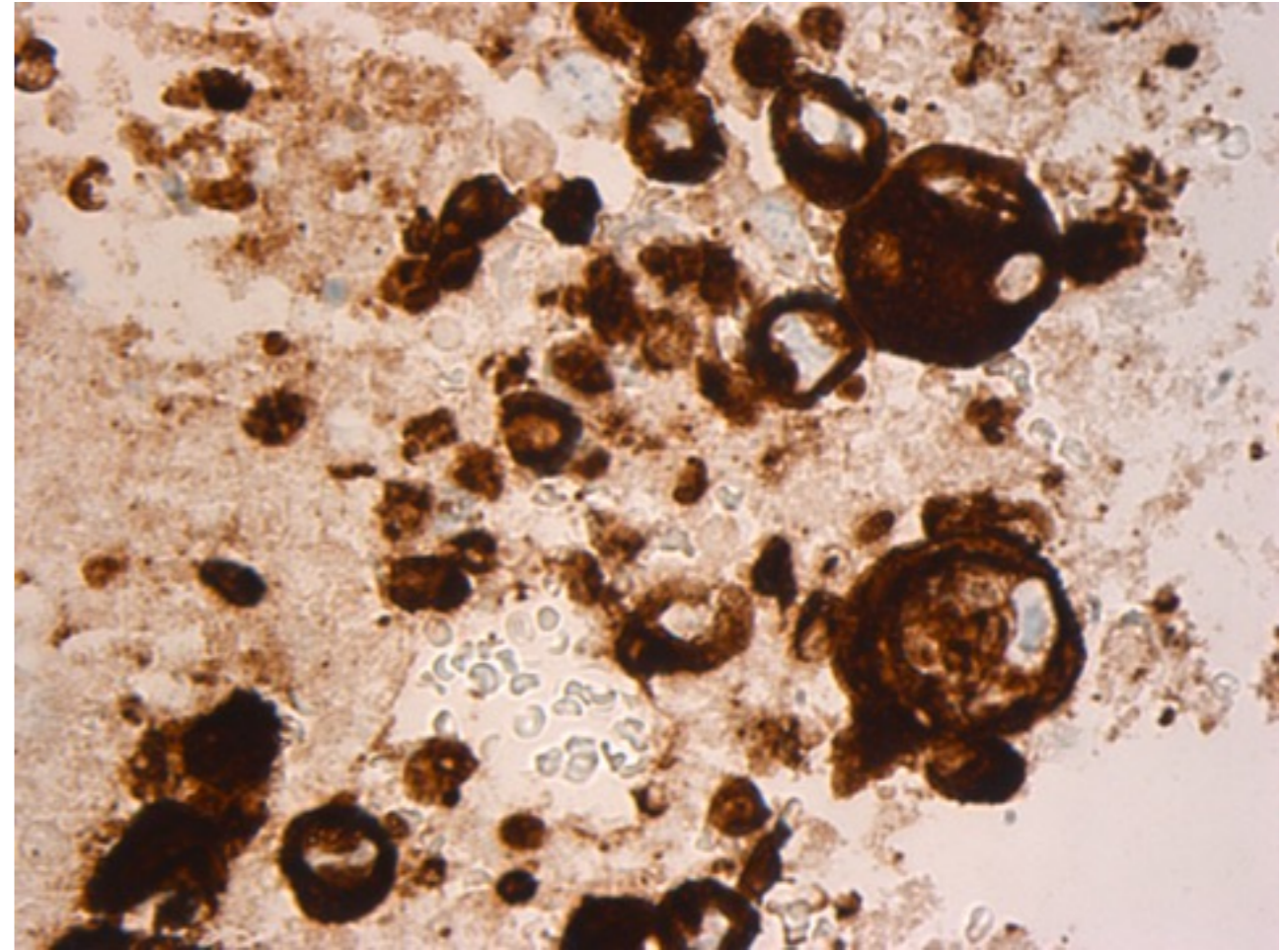
Koagel, HE x 63



Koagel, ttf1 x 63



Koagel, cytokeratin x 63



Koagel, vimentin x 63