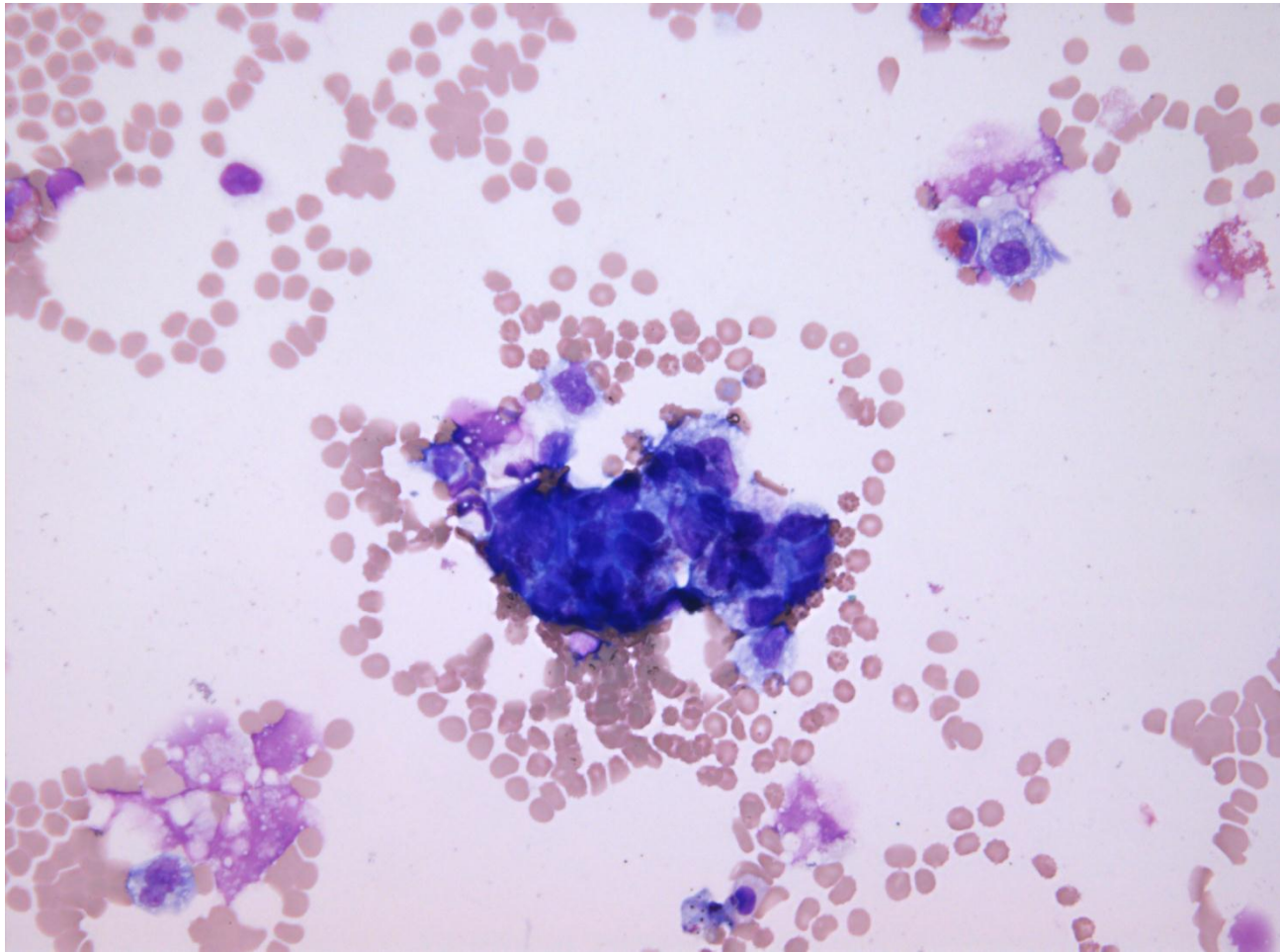


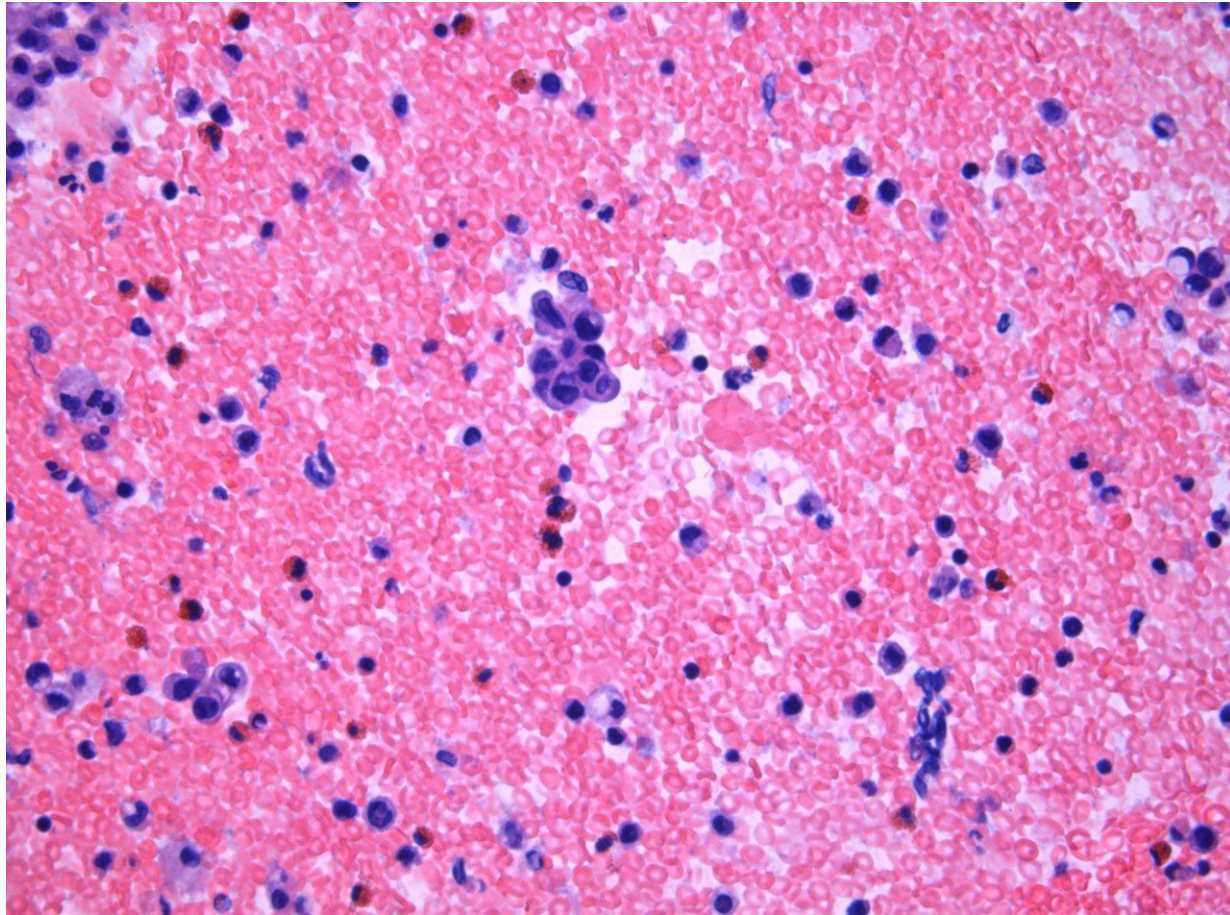
# Netcase 5

- 58 årig kvinde med 4 cm multicystisk ovariecyste
- Peritoneal skyllevæske

# Peritoneal skyllevæske, cytospin

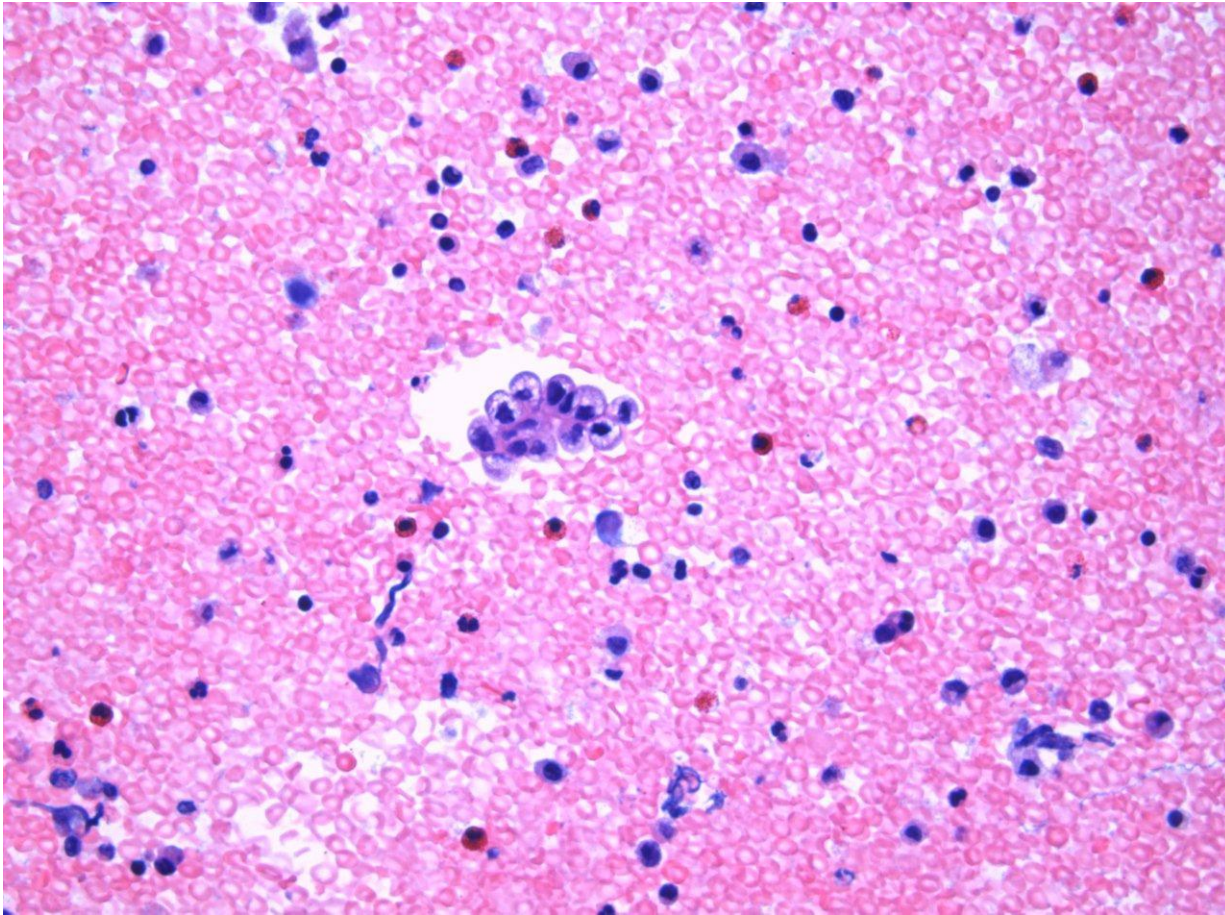


# Peritoneal skyllevæske, koagel

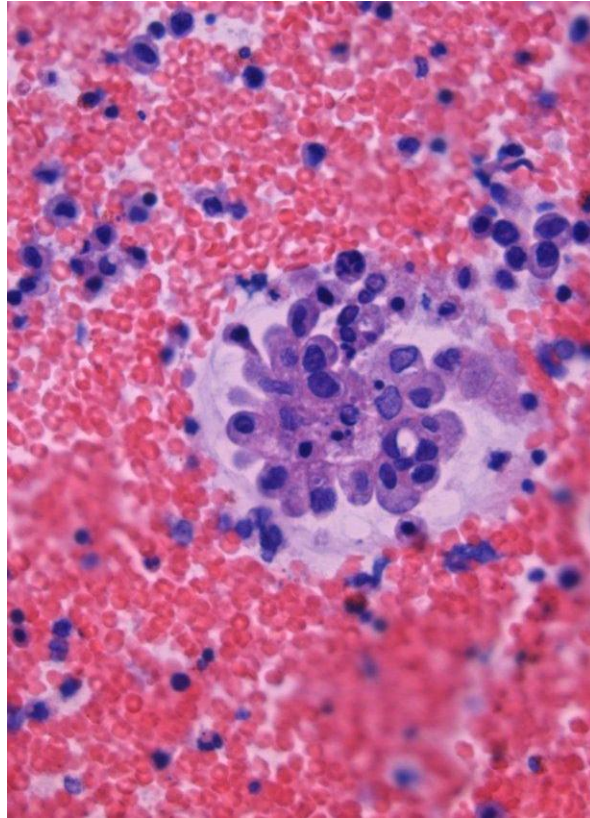




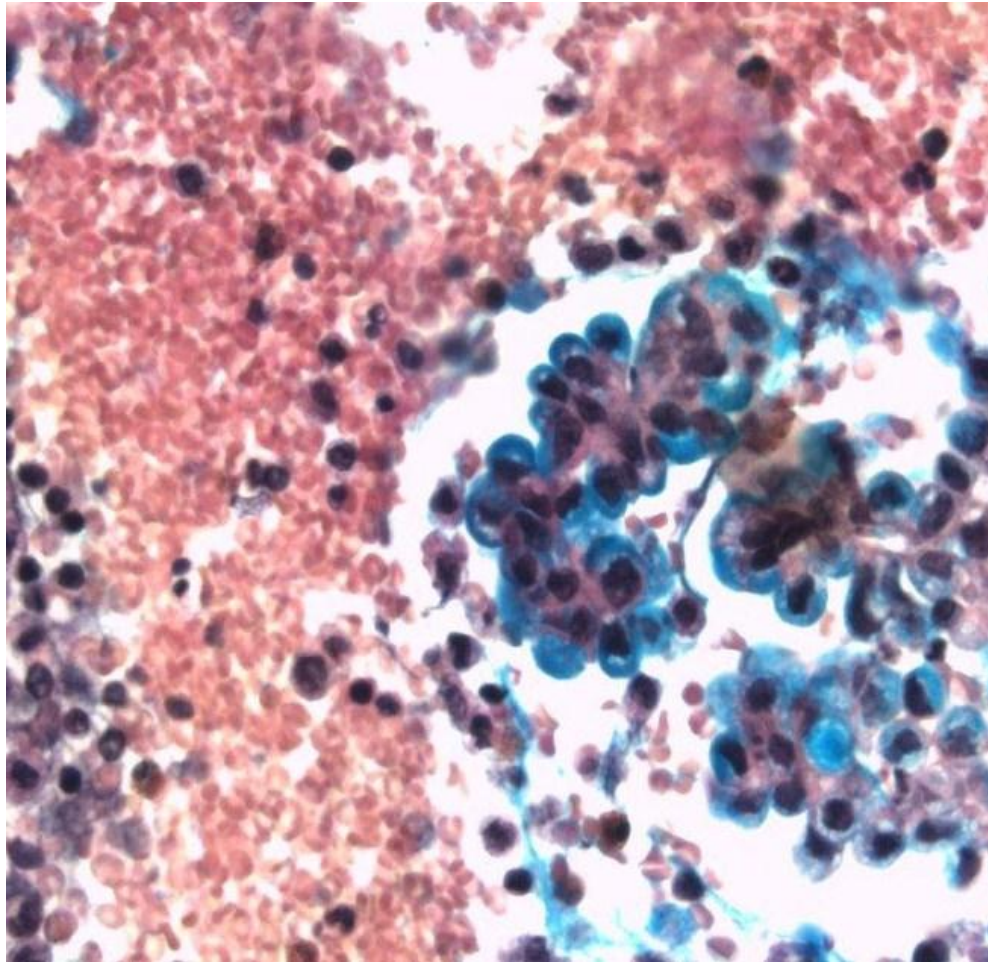
# Peritoneal skyllevæske, koagel



# Peritoneal skyllevæske, koagel

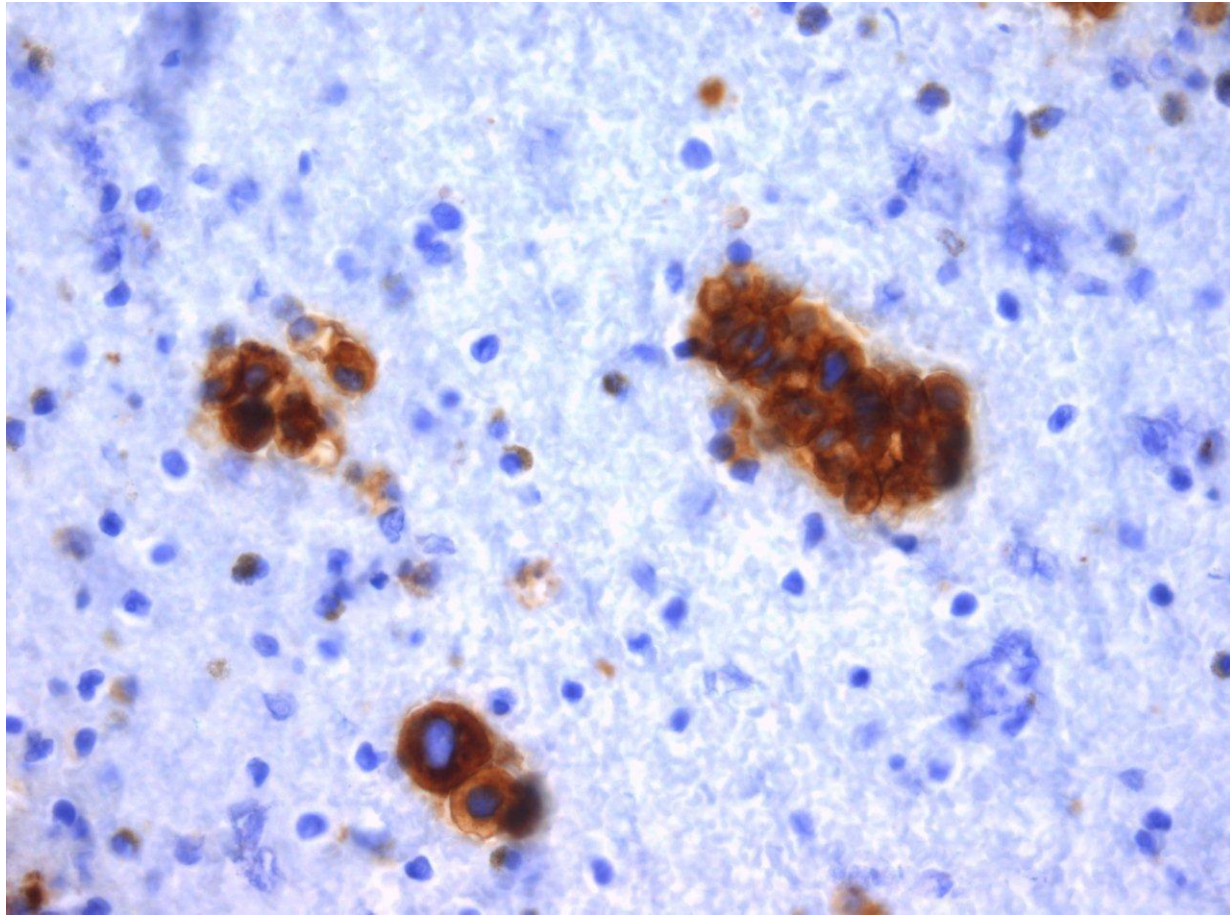


# Peritoneal skyllevæske, slimfarvning

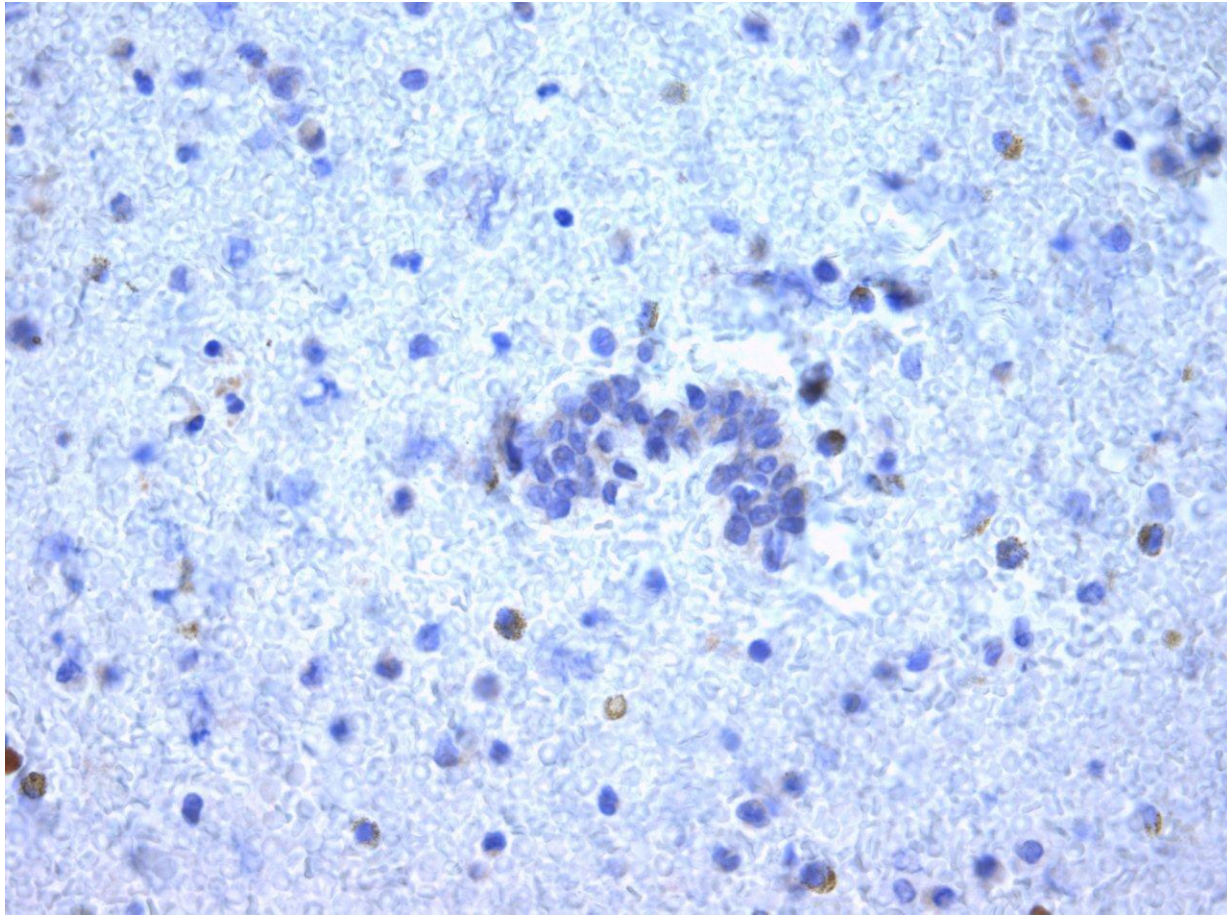




# CEA, immunfarvning på koagel

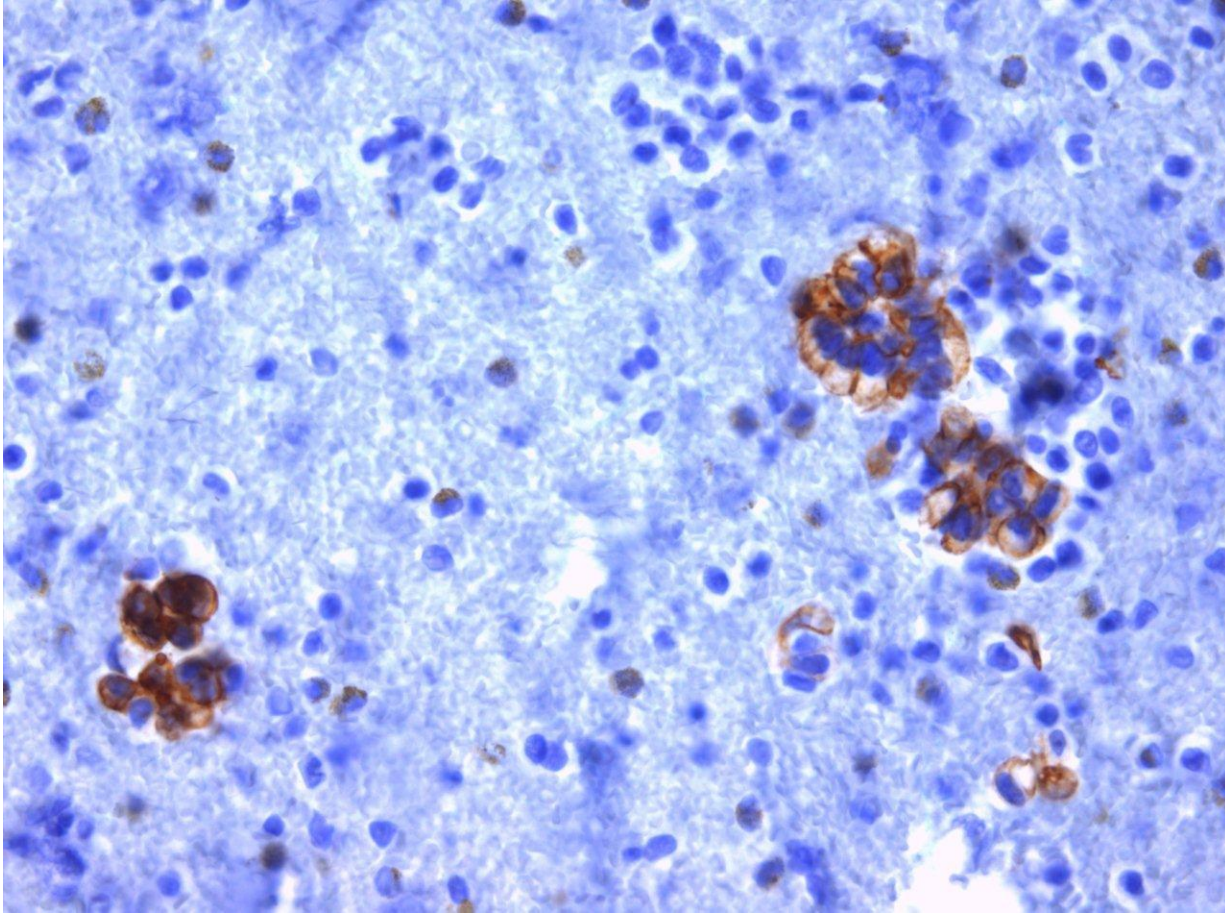


# PAX8

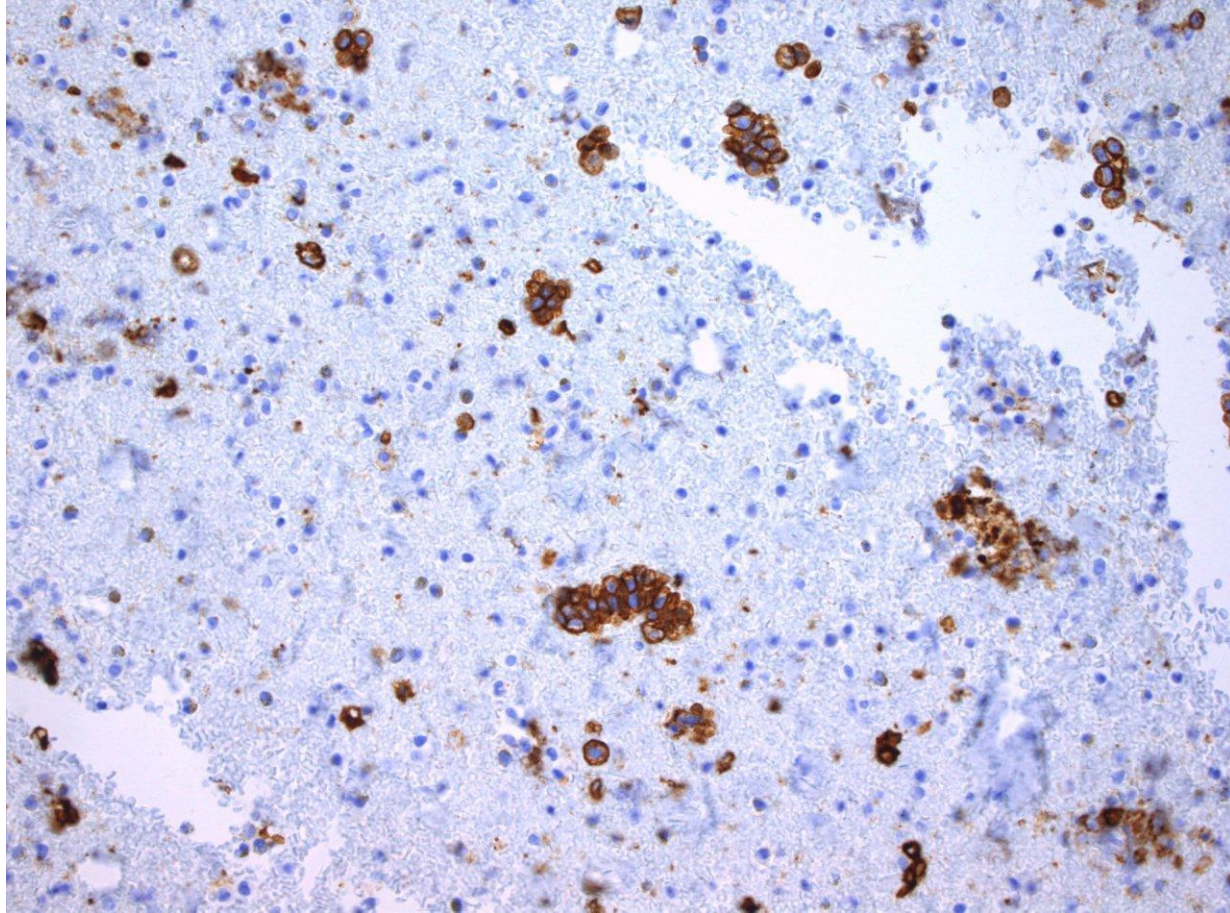




# CK20

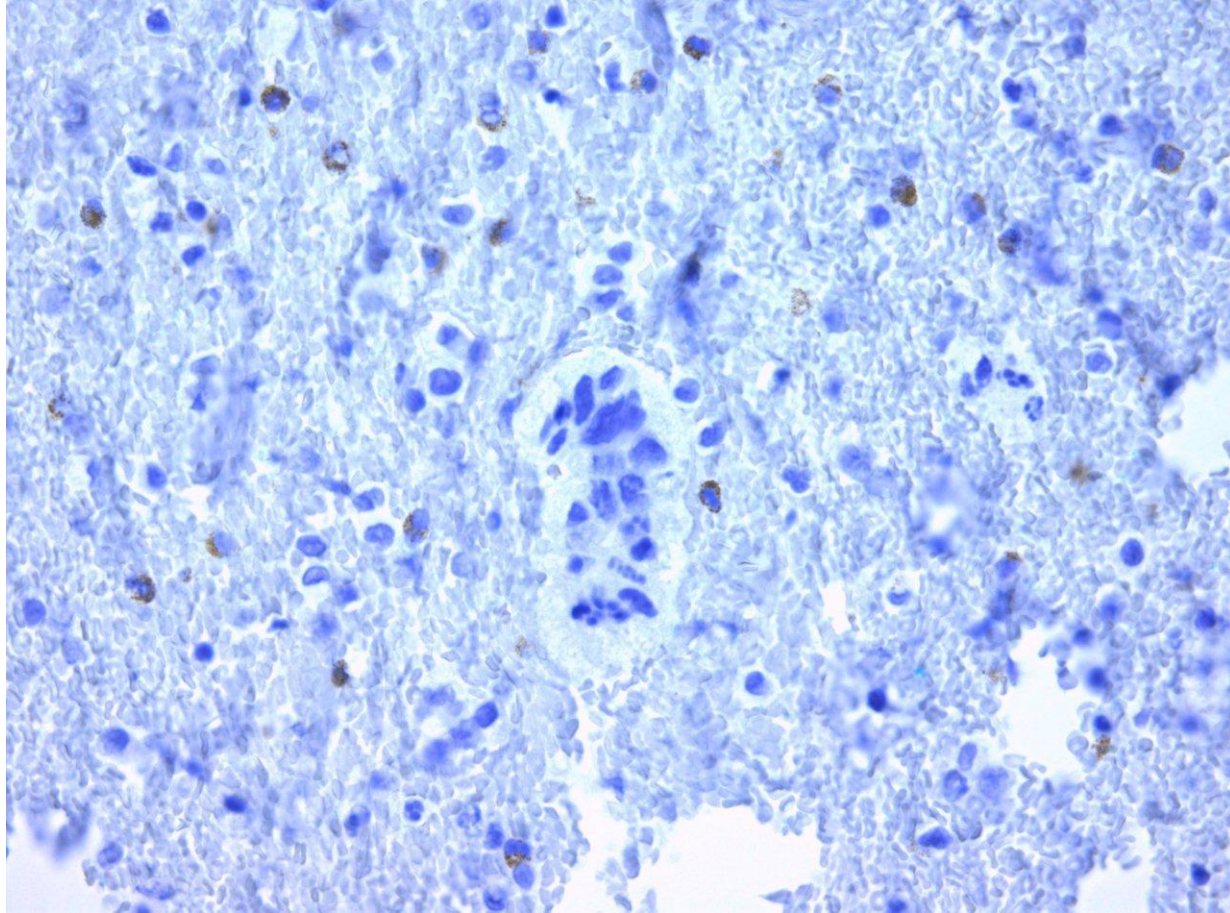


CK7



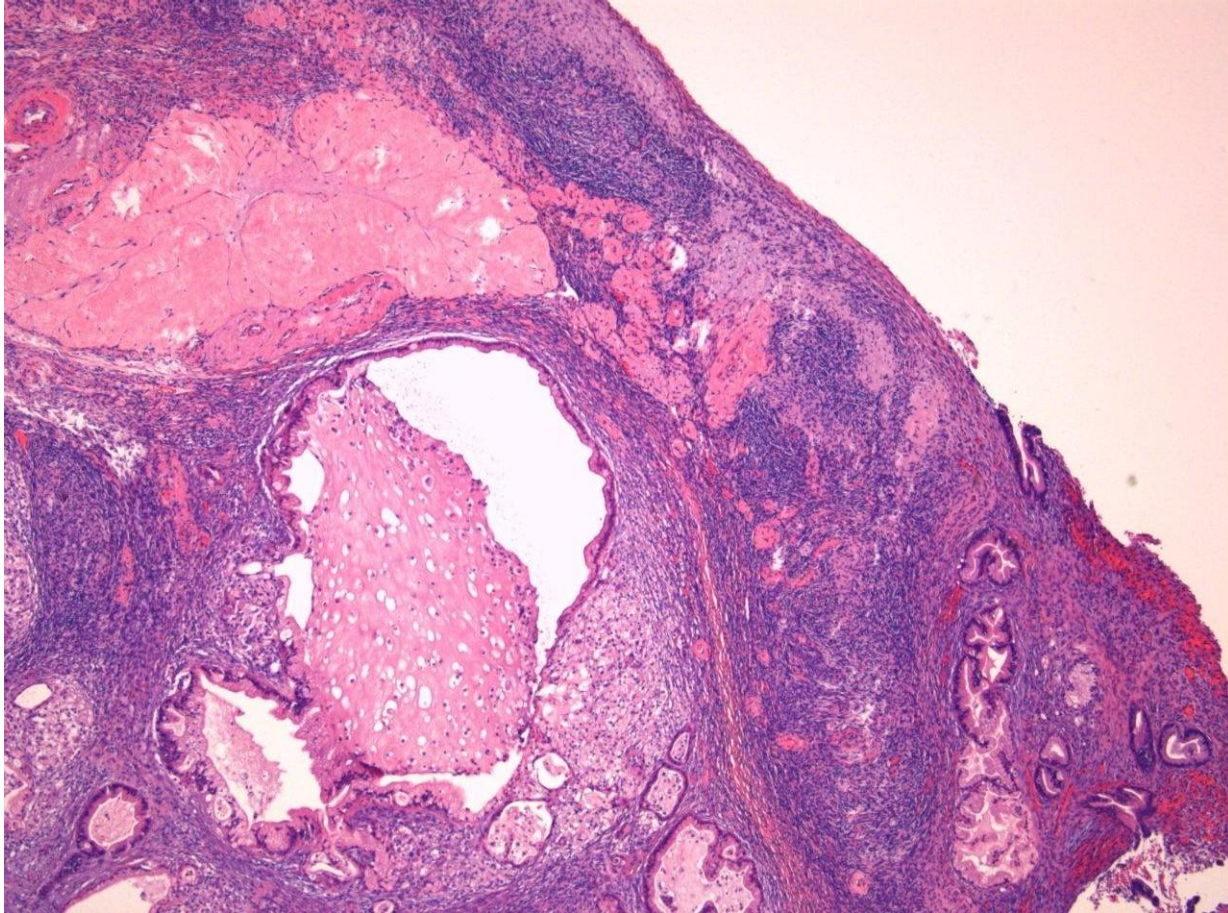


# Calretinin

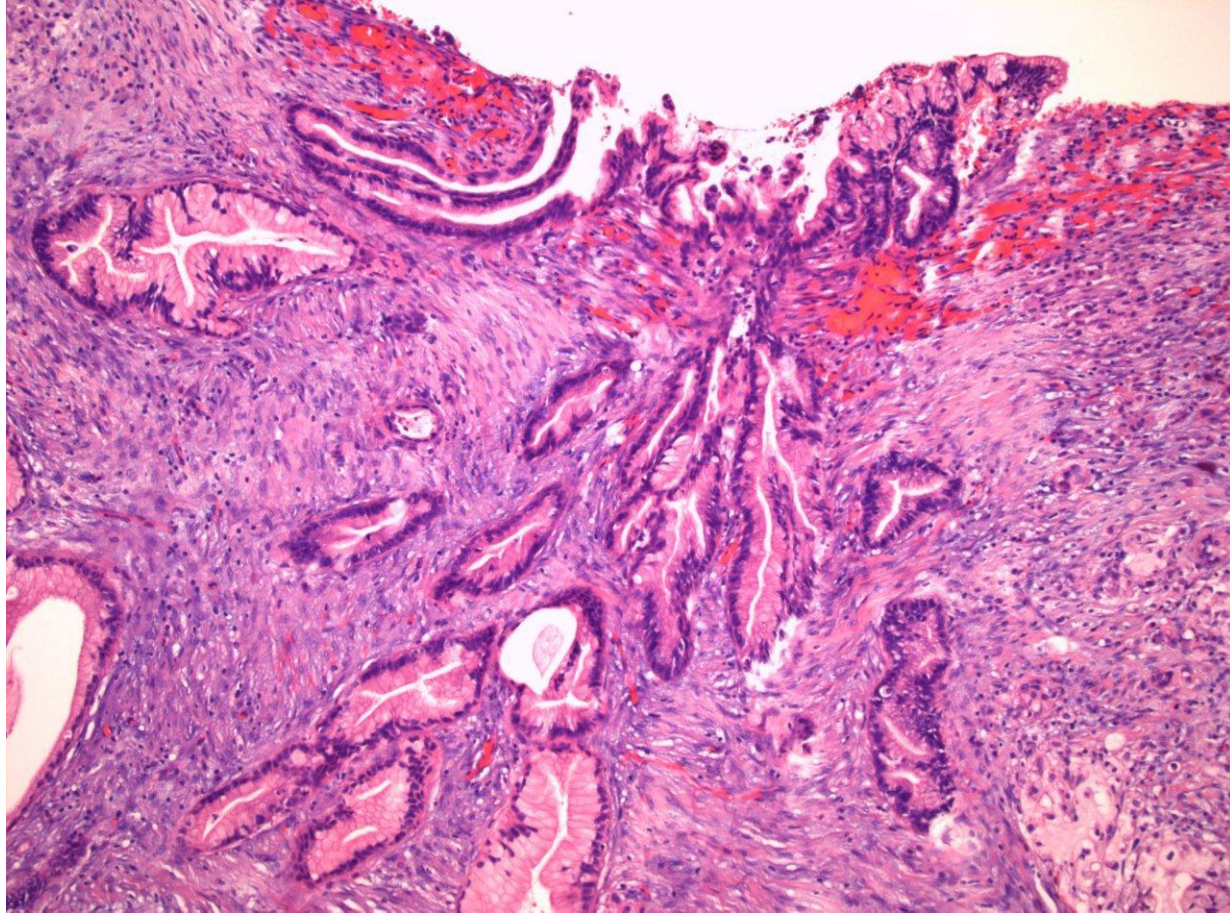




# Ovariet



# Ovariet, overflade



Diagnose?