

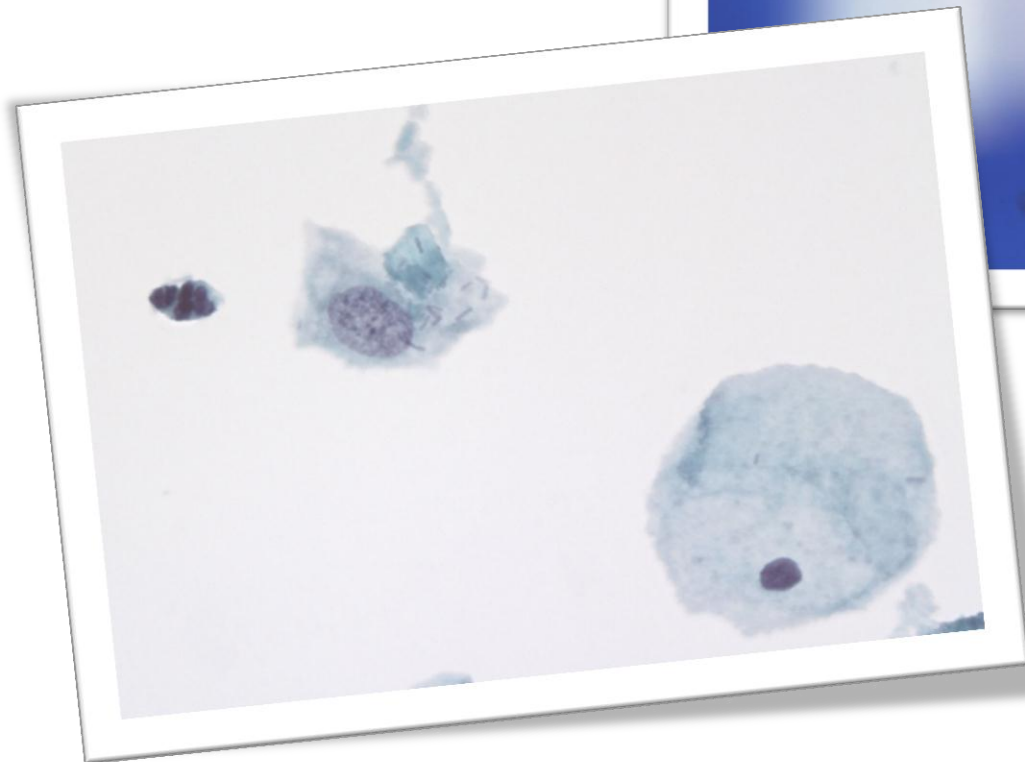
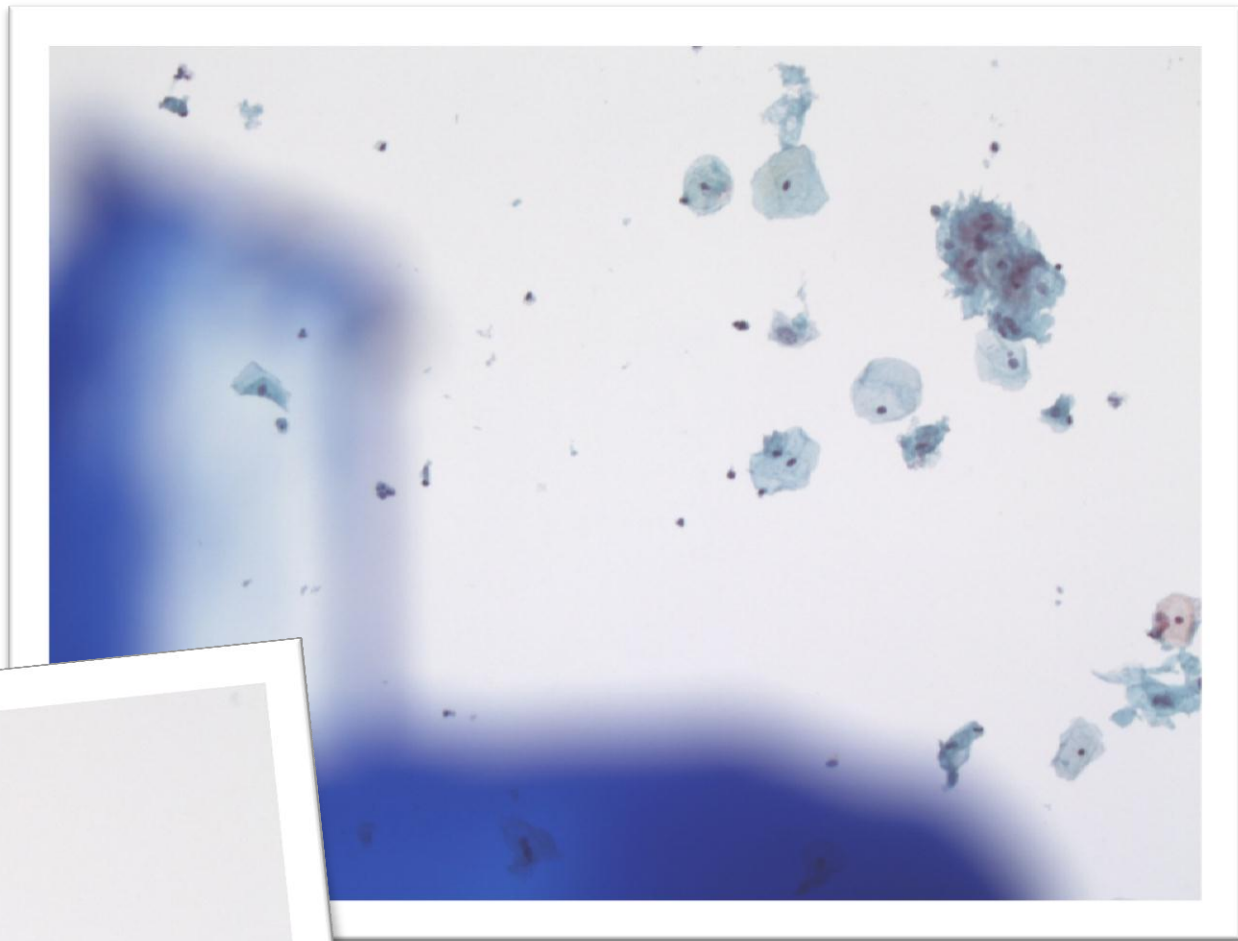
# NETCASE 1

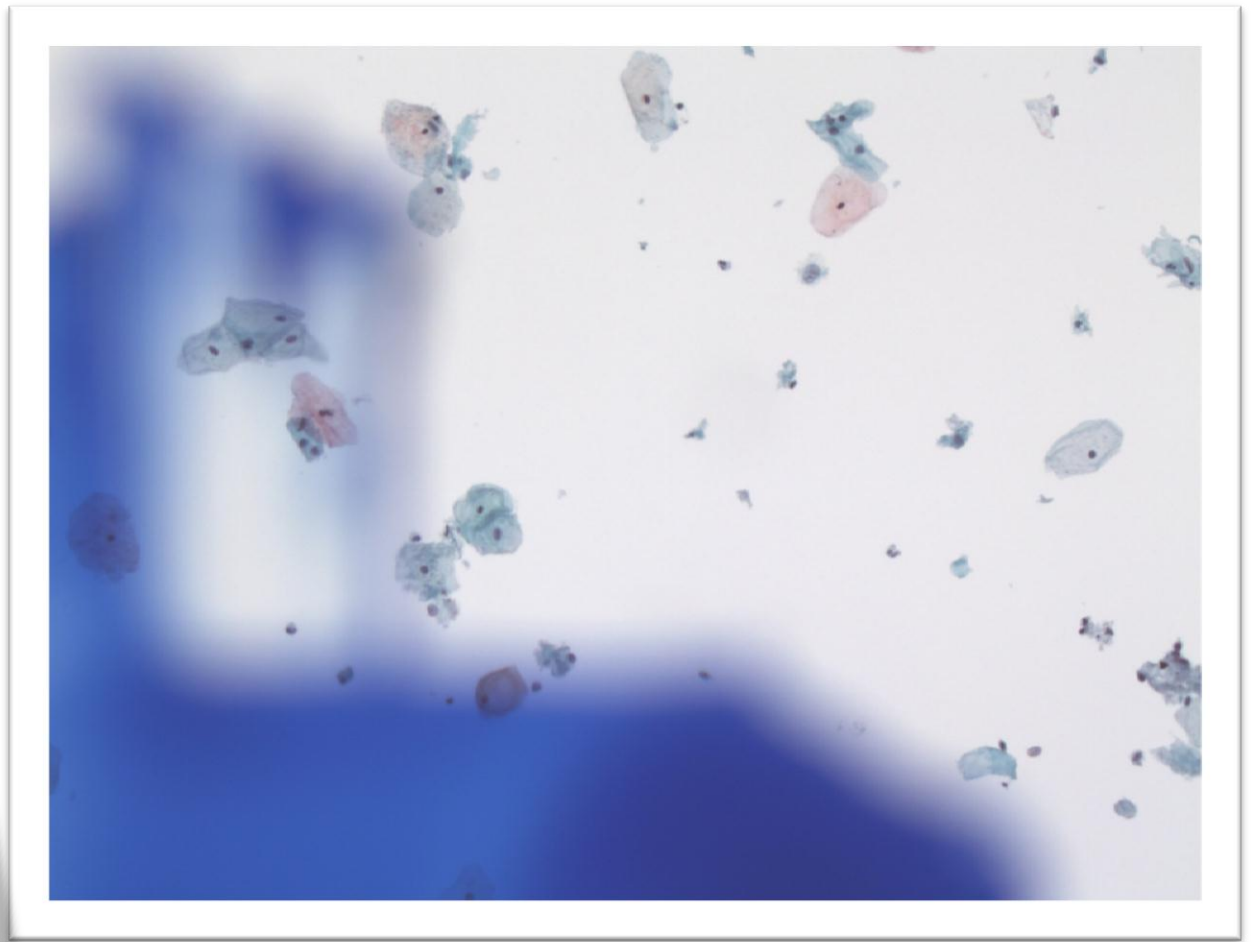
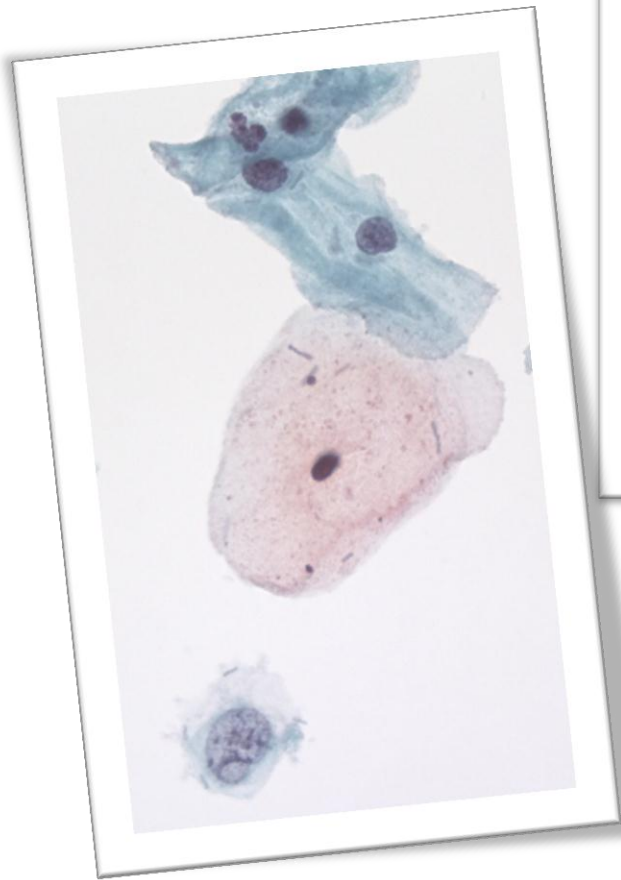
## OUH

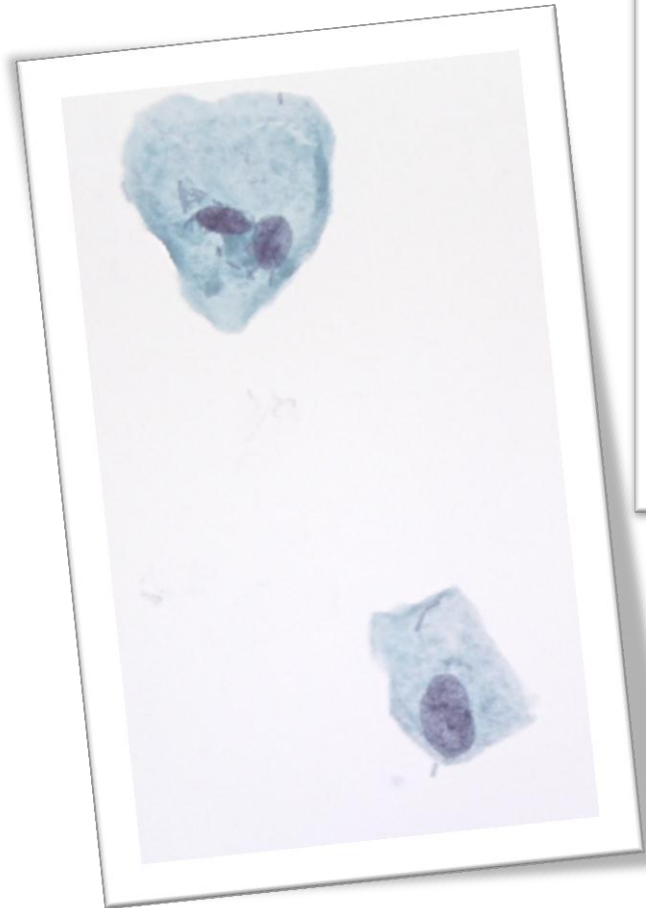
Cervixcytologi

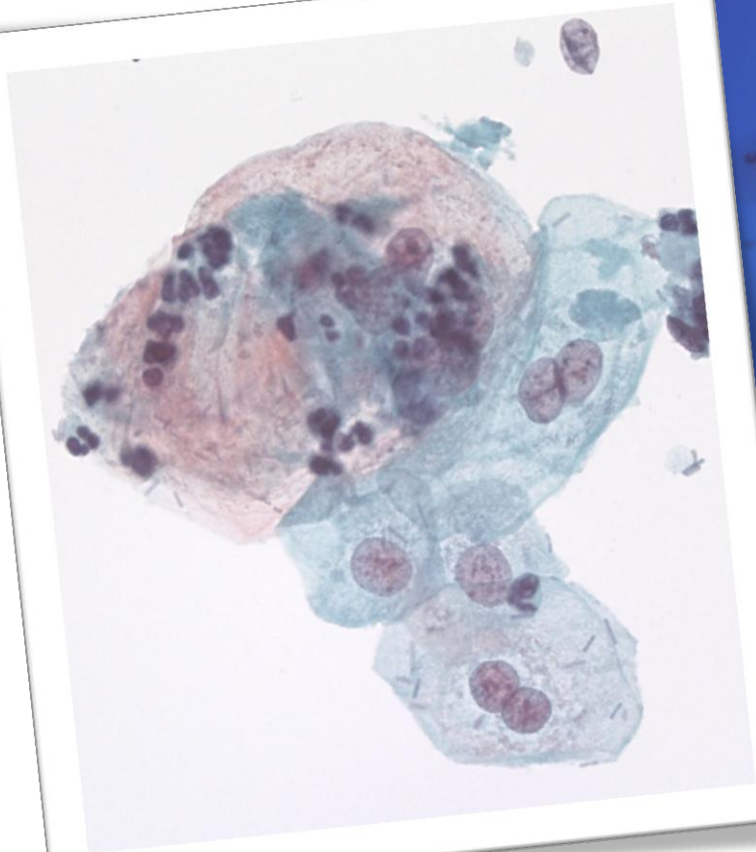
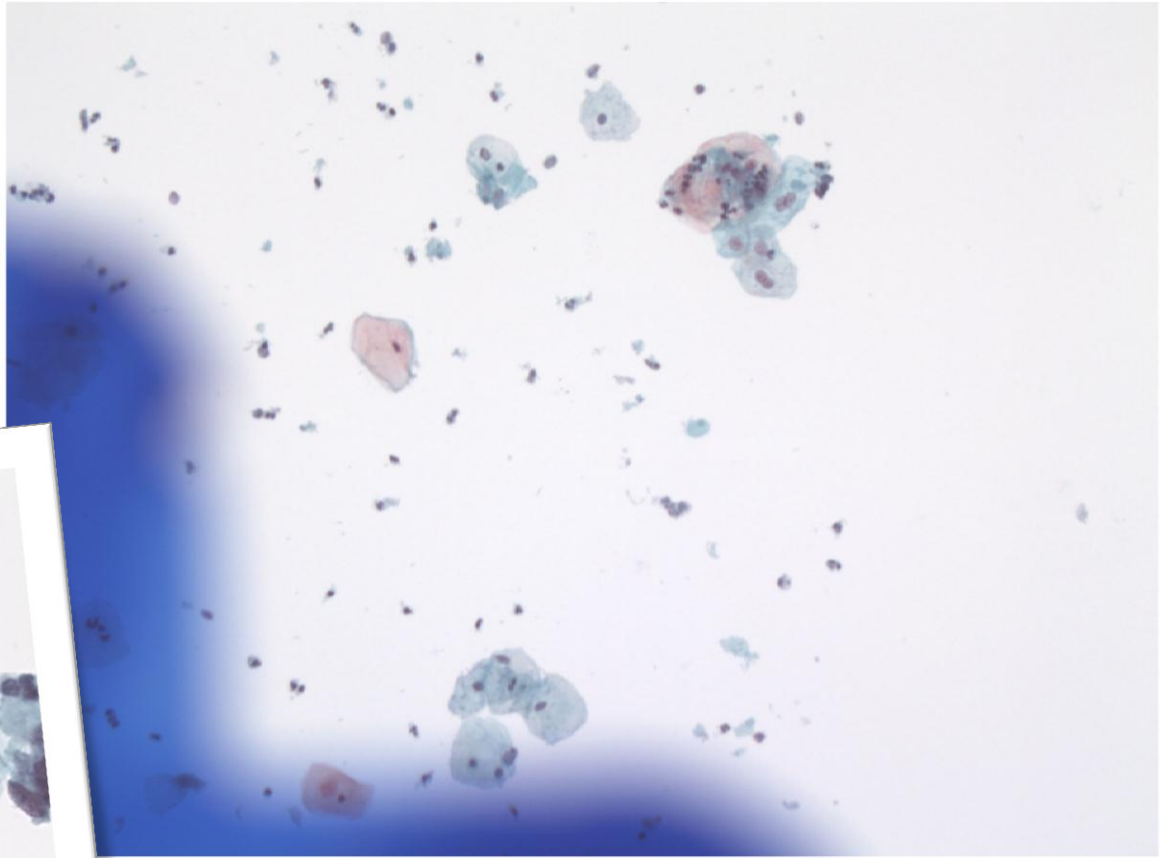
ThinPrep +Imaging Systemet, nov. 2010.

29 år, debutprøve, sidste mens. 9 dage siden.









**DIAGNOSE?**