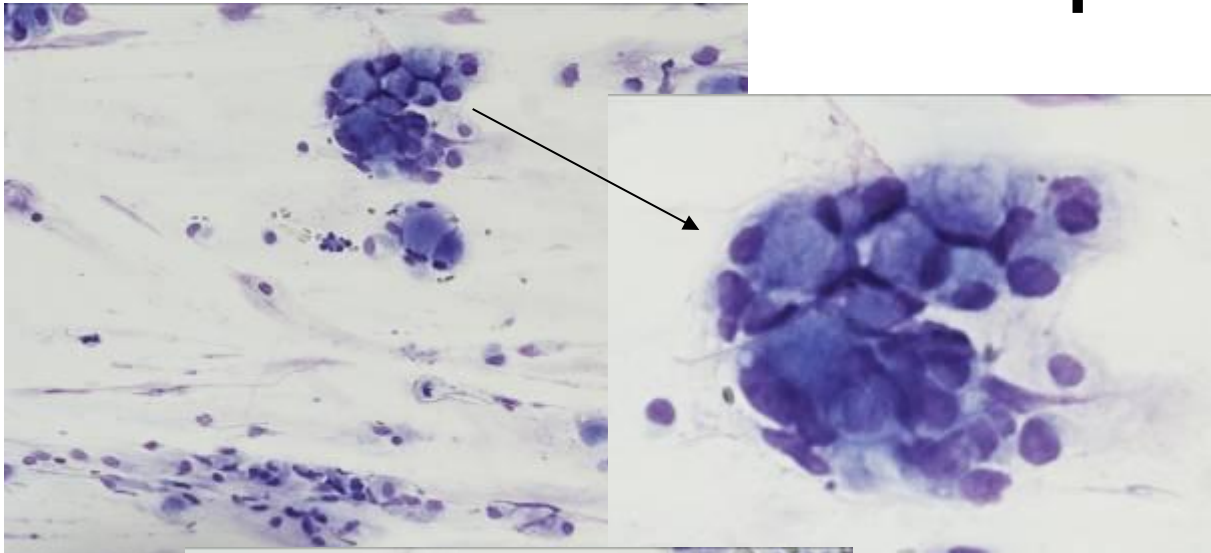


# Netcase 6

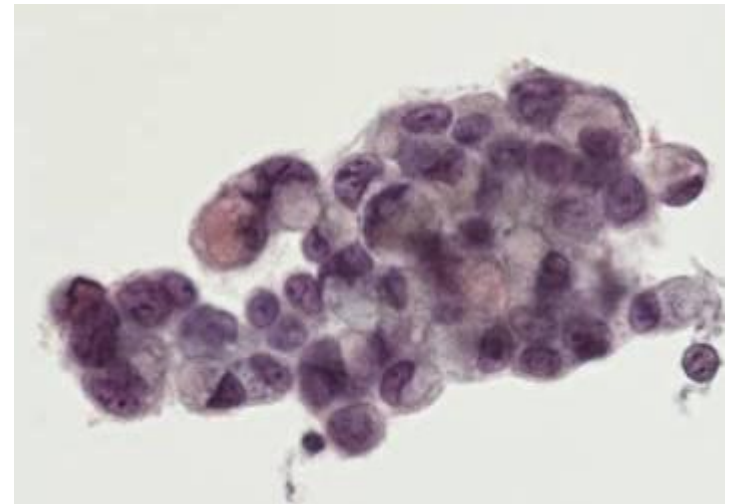
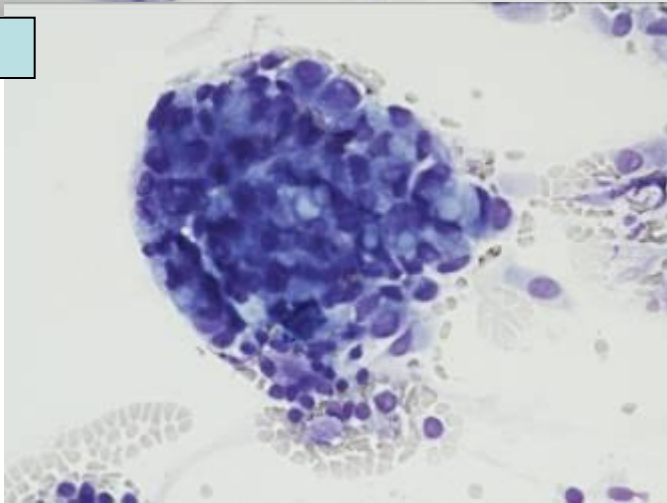
Mand 33 år

Børstebiopsi og  
broncials skyllevæske

# børstebiopsi



MGG



PAP

# broncialskylløvæske

