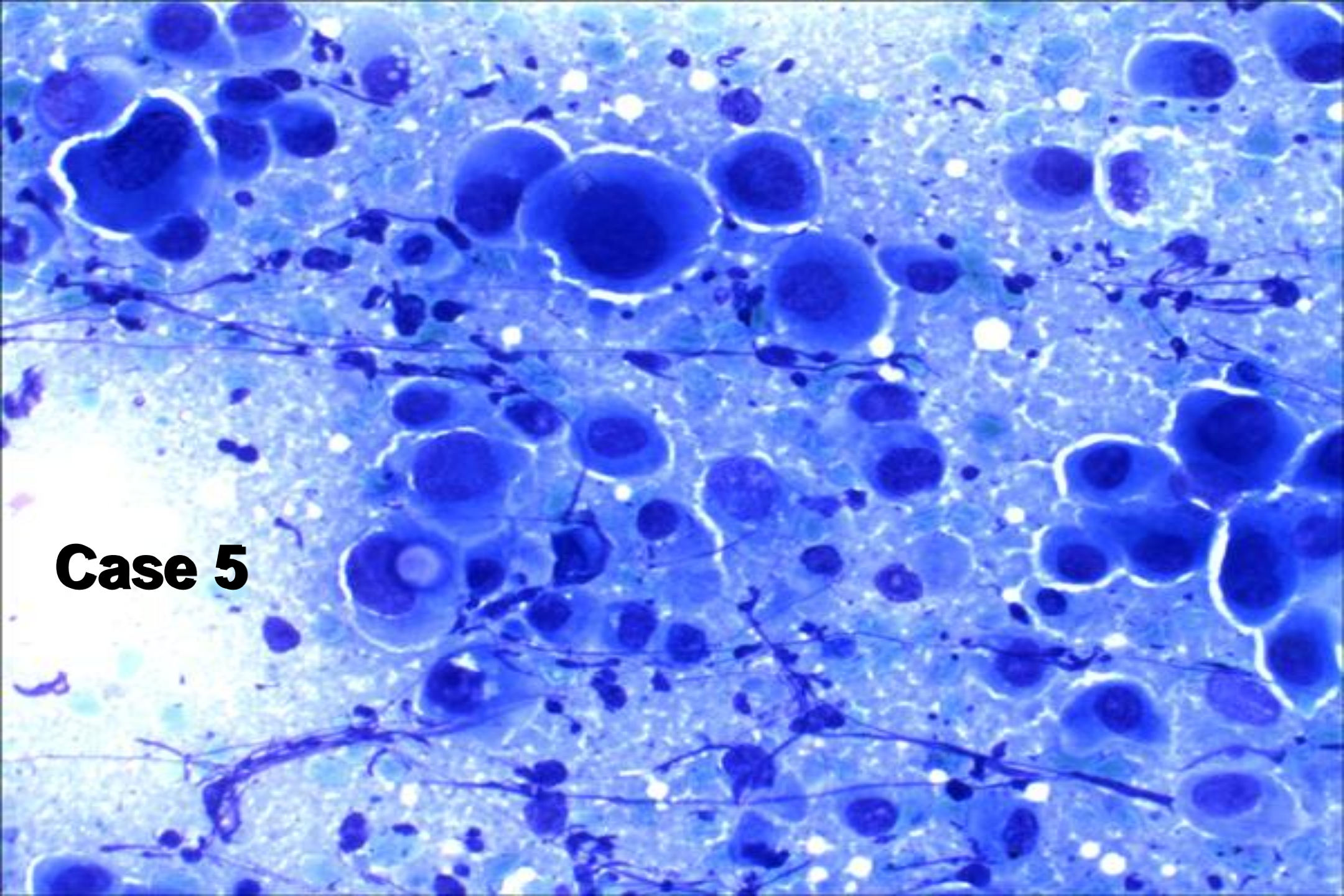
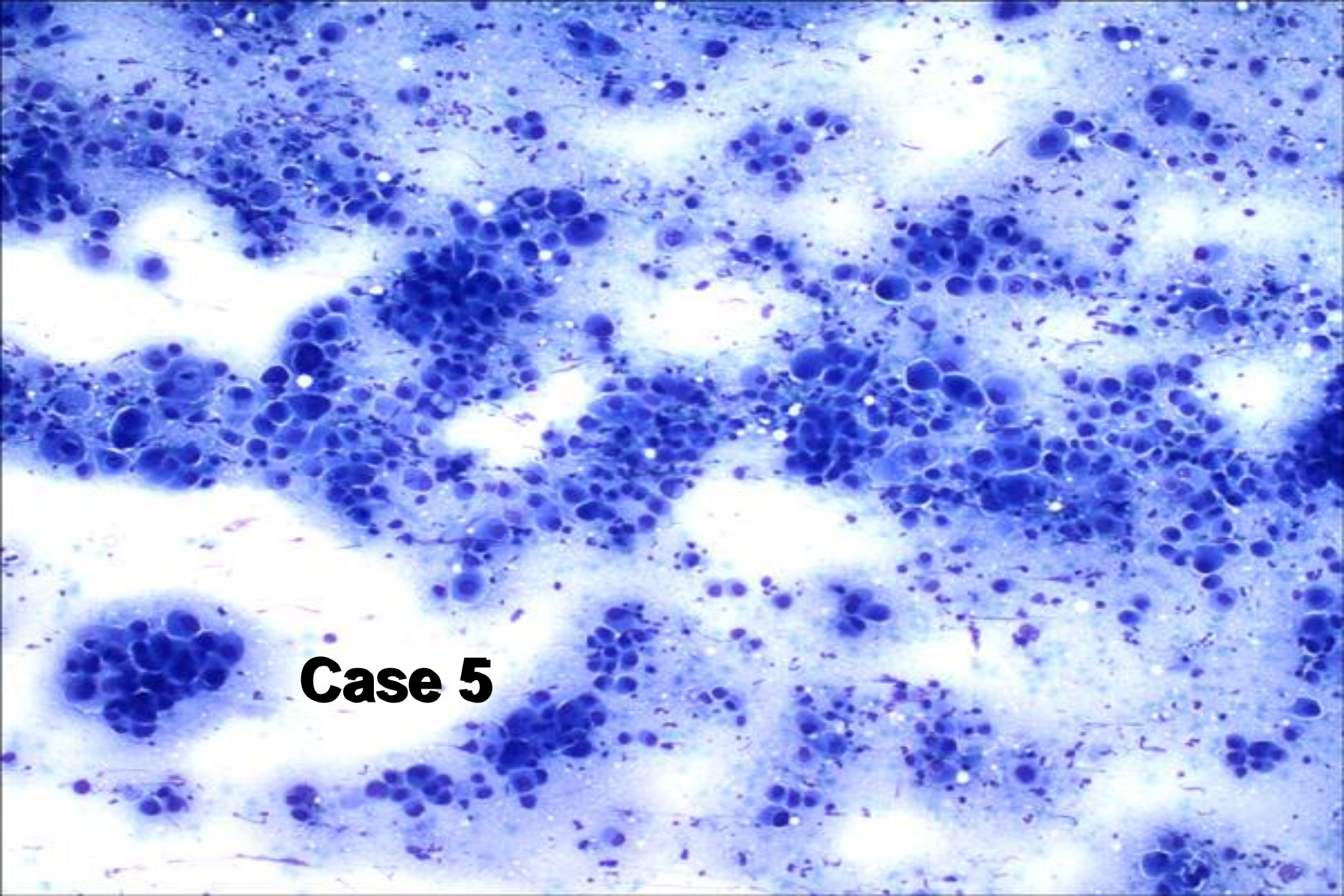


Case 5

**64-year-old woman with enlarged
lymph node
in the neck region**

Case 5





Case 5

Case 5

