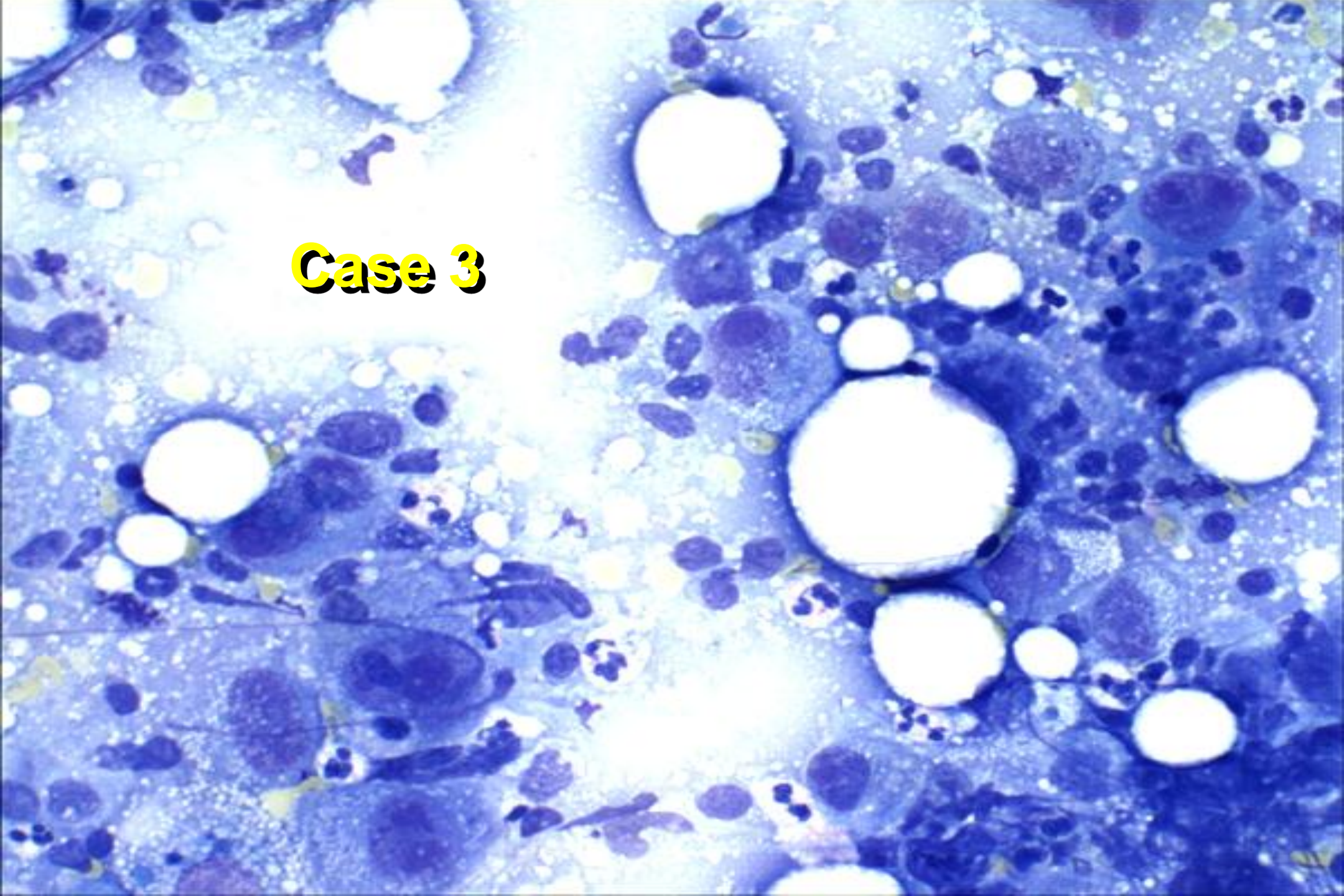


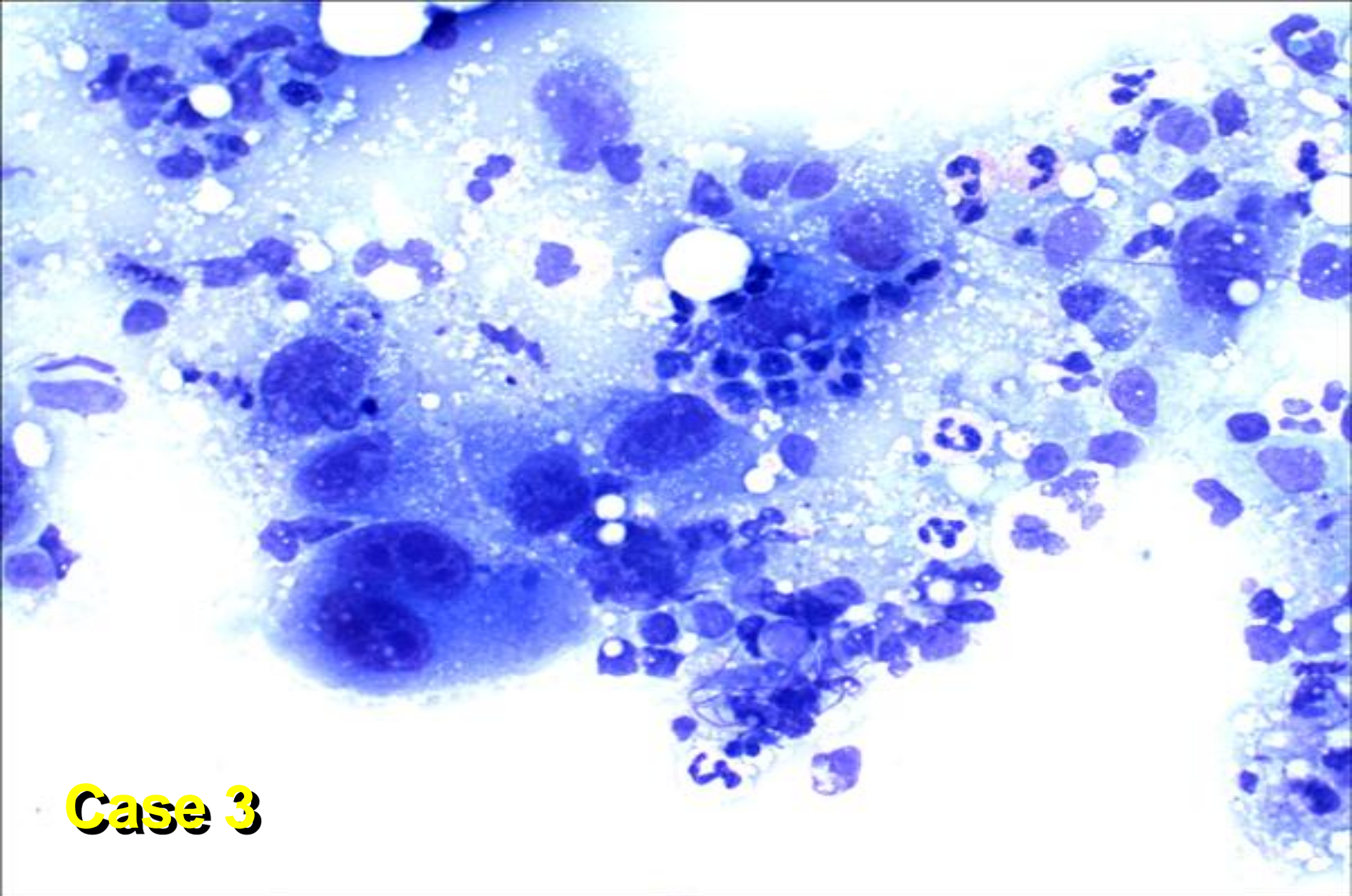
# Case 3

**53-year-old man with enlarged  
lymph node  
in the neck region**

**Case 3**







**Case 3**

**Case 3**

