

# For all cases:

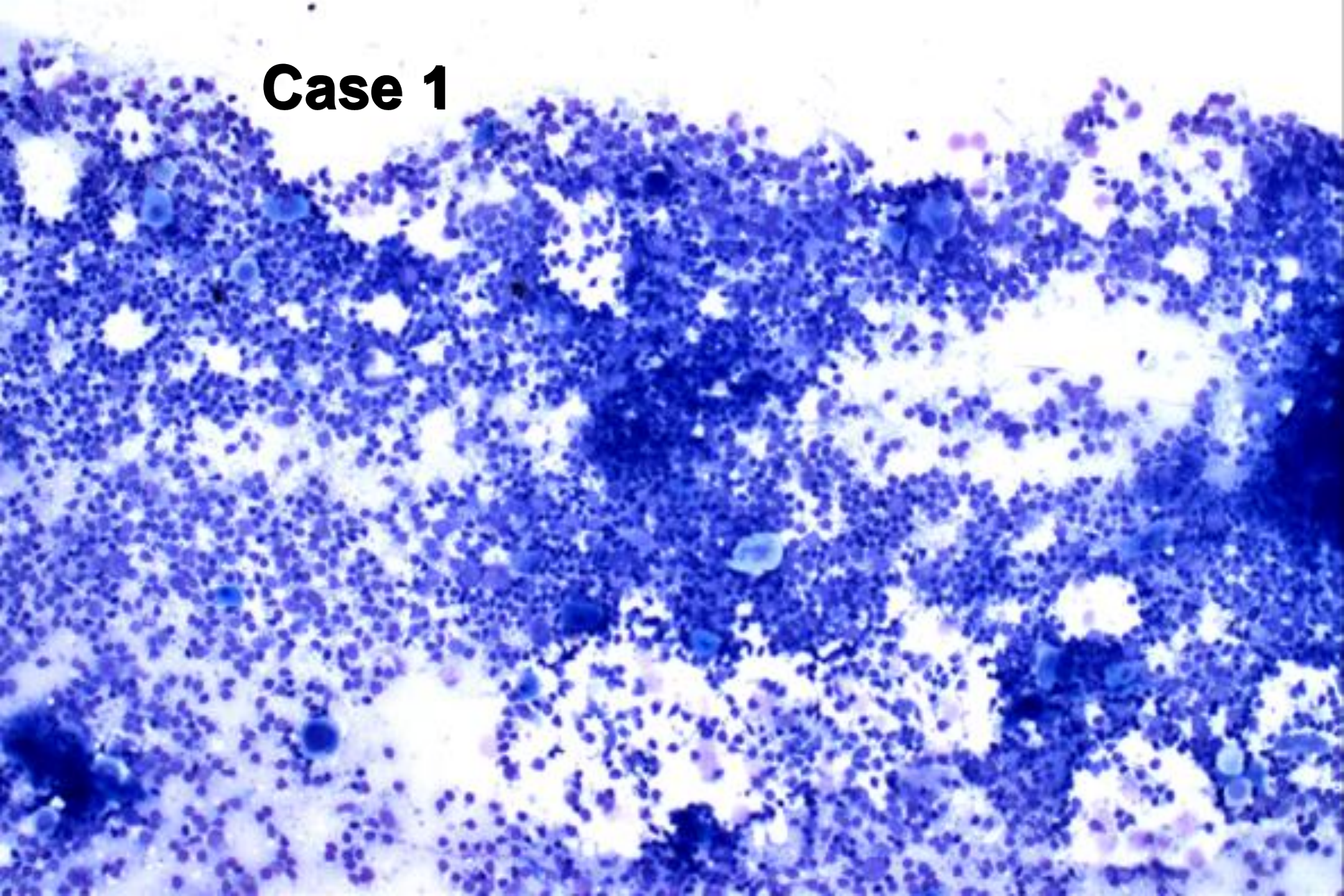
- What primary tumor can this be?
- If you think immunocytochemistry is needed for the diagnosis, which markers would you choose (maximum three markers)

# Case 1

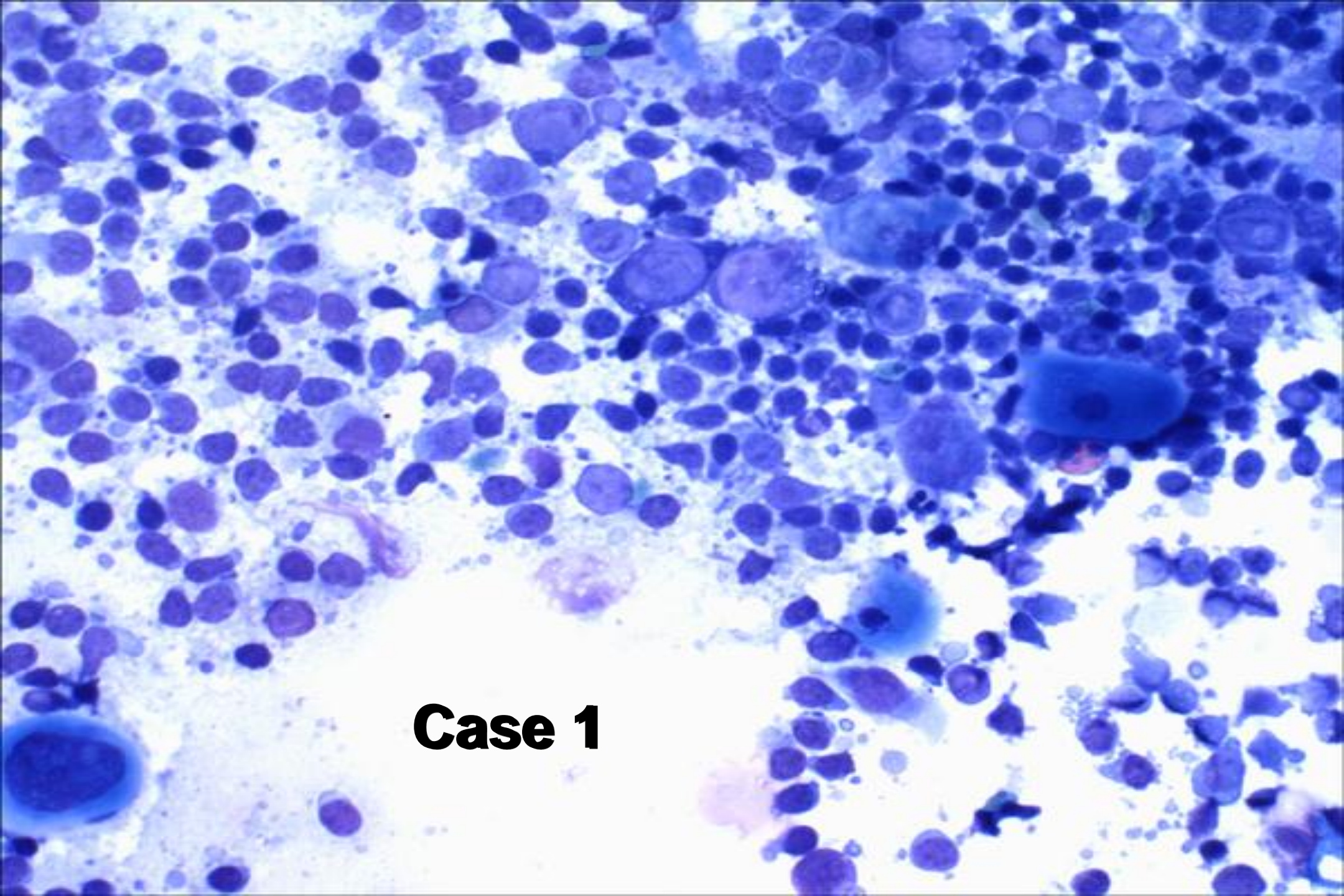
**53-year old man with enlarged  
lymph node  
in the neck region**



# Case 1







**Case 1**



**Case 1**

