CASE 1

42 årig man. Opererad för högersidig testikelcancer (seminom).

2010 spridning retroperitonealt. Fått kemoterapi.

CT thorax, tillkommit en körtelförstoring i vänster hilus.
(Ökat från en till två centimeter.)

EBUS punktioner mot position 11L.

Spridning av testikelcancer? Reaktiv lymfkörtel?

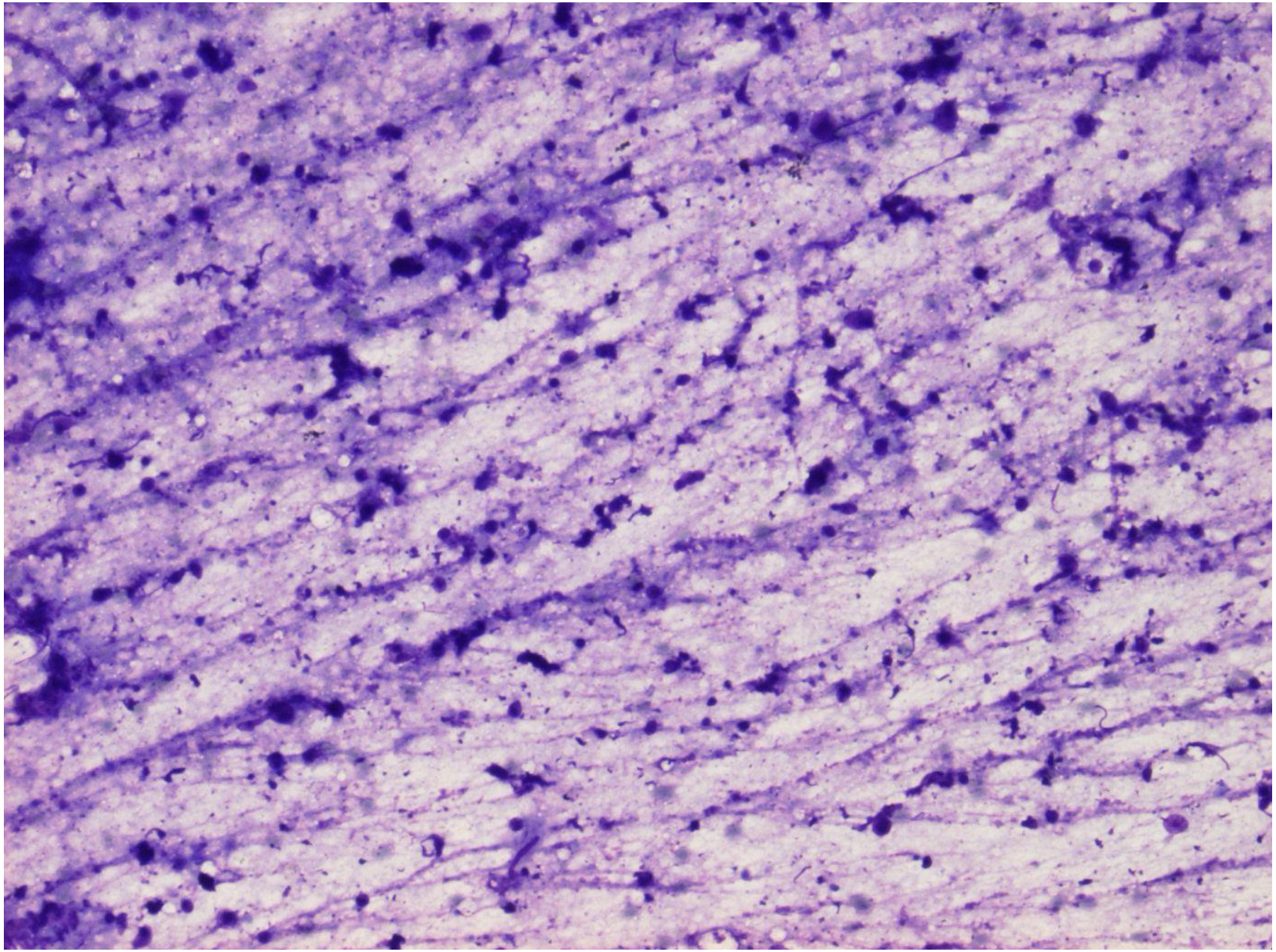

DQ x 10 pos 11L

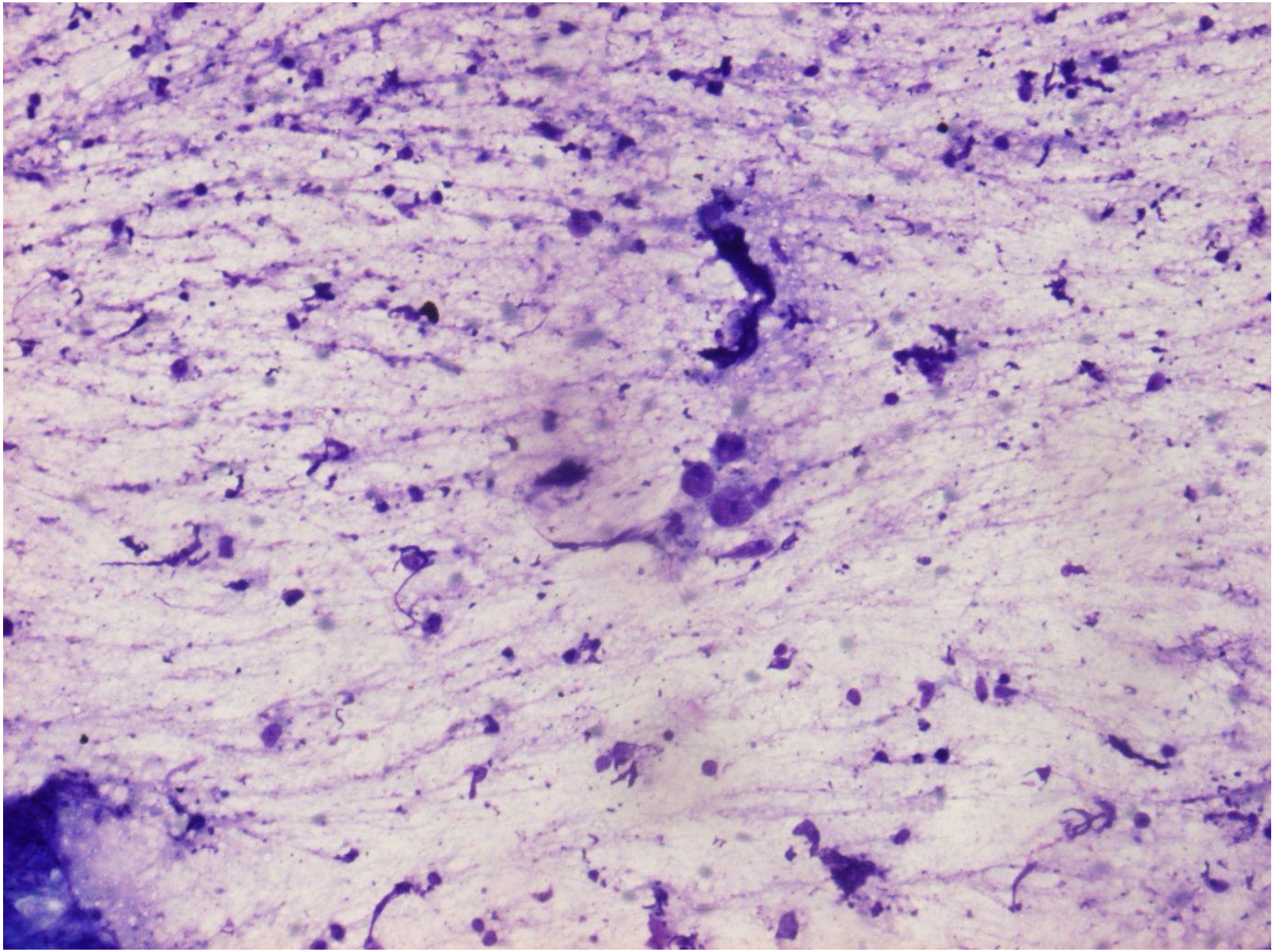

DQ x 10 pos 11L

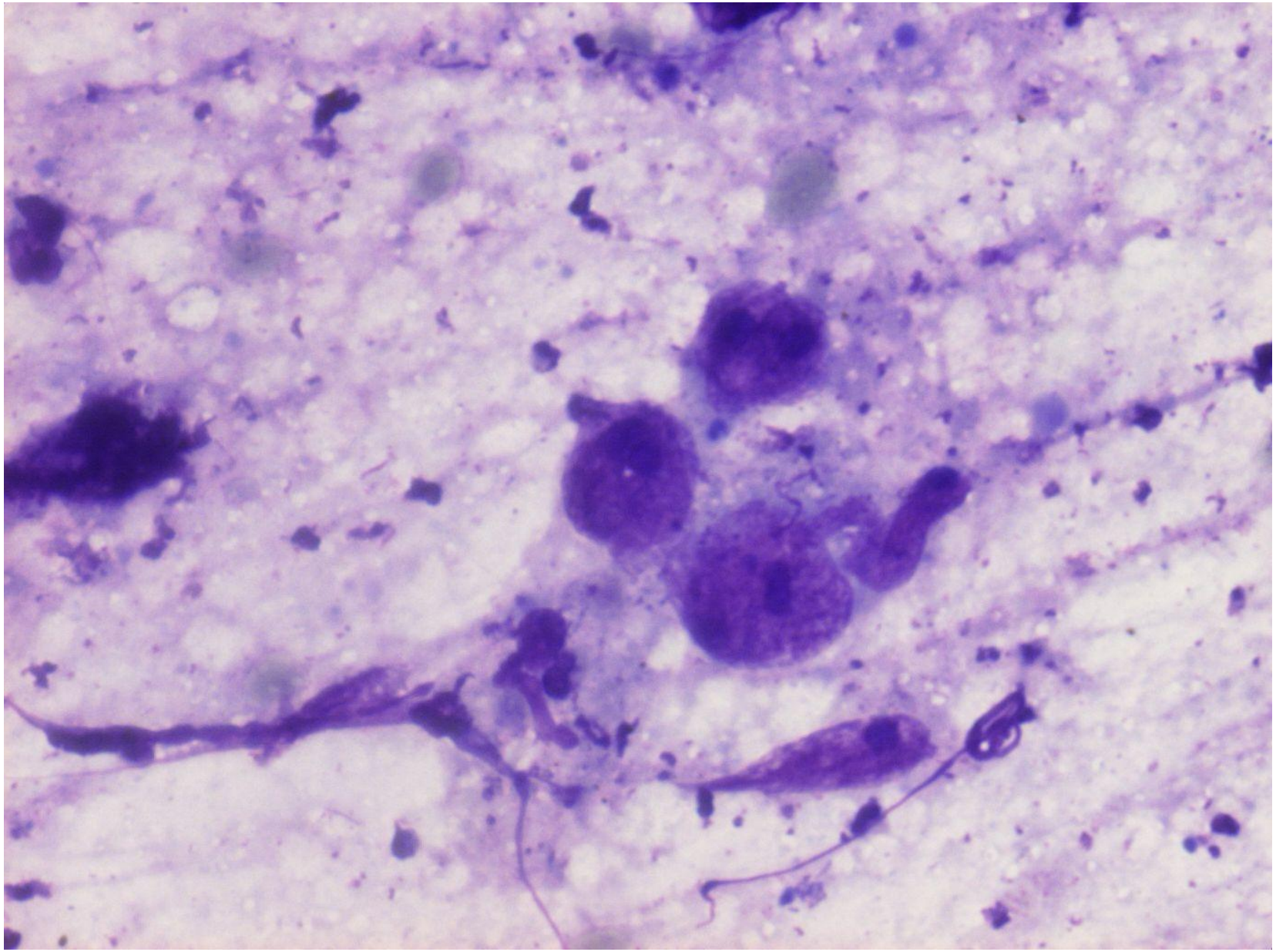

DQ x 60 pos 11L

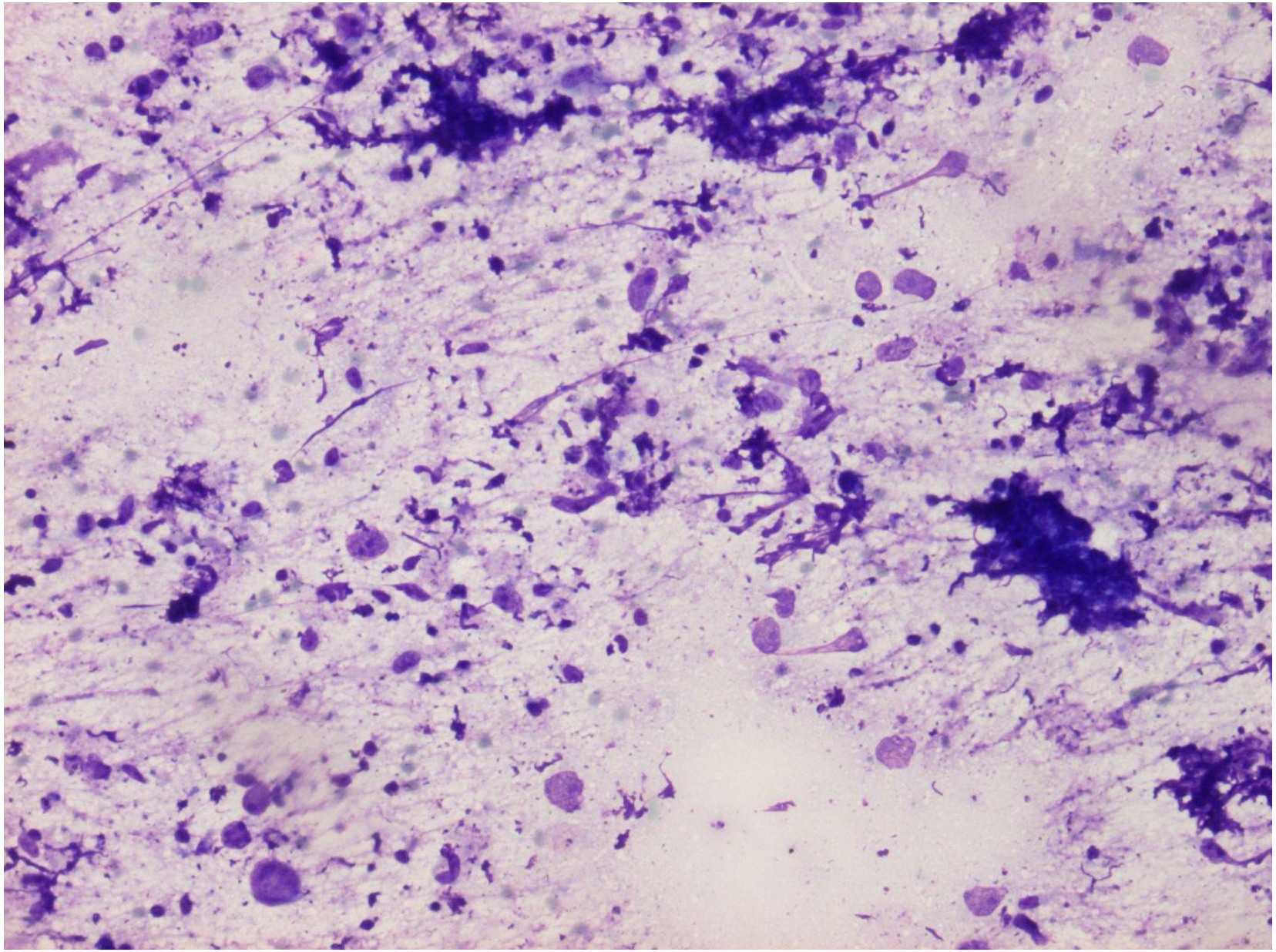

DQ x 10 pos 11L

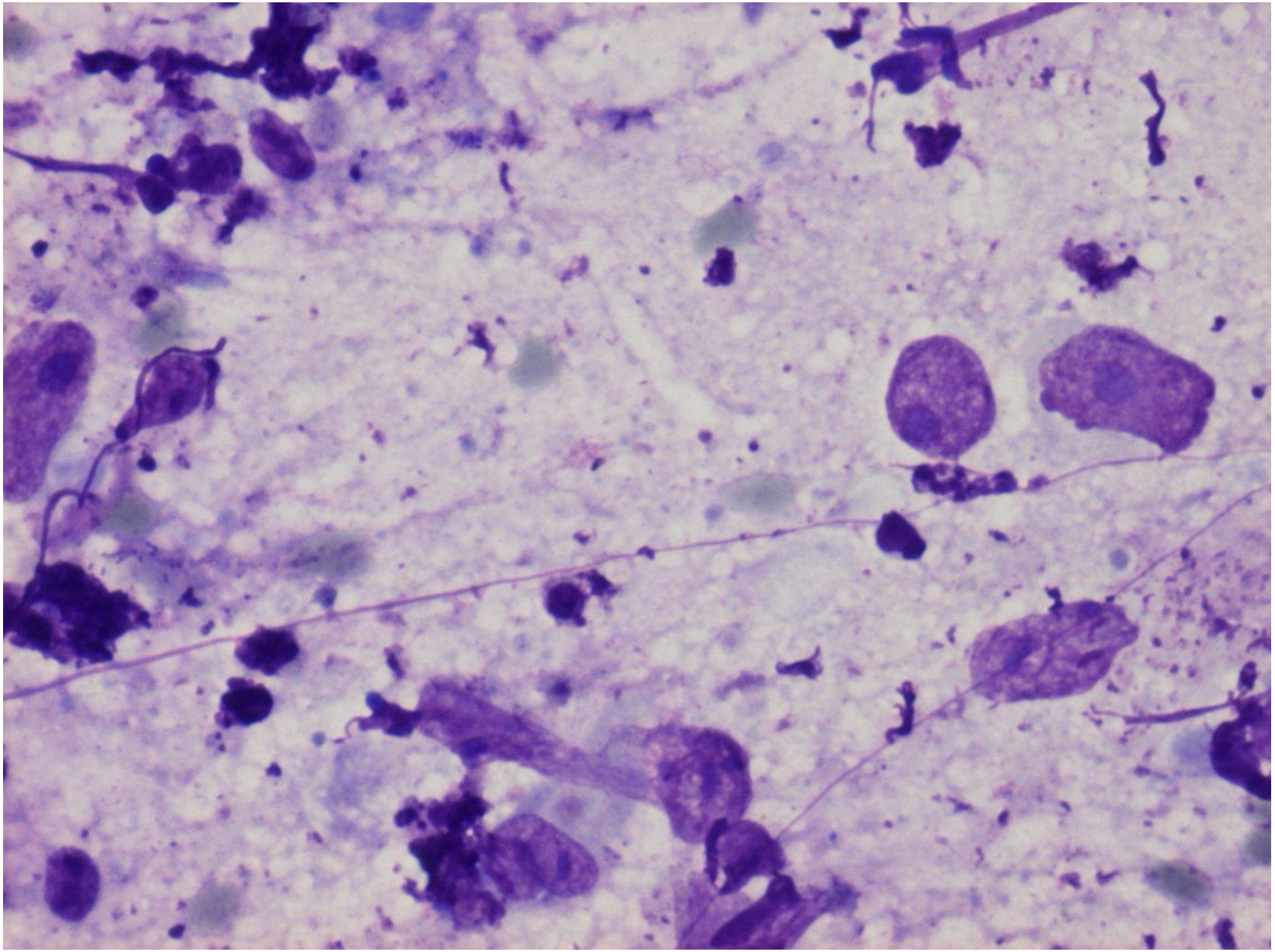

DQ x 40 pos 11L

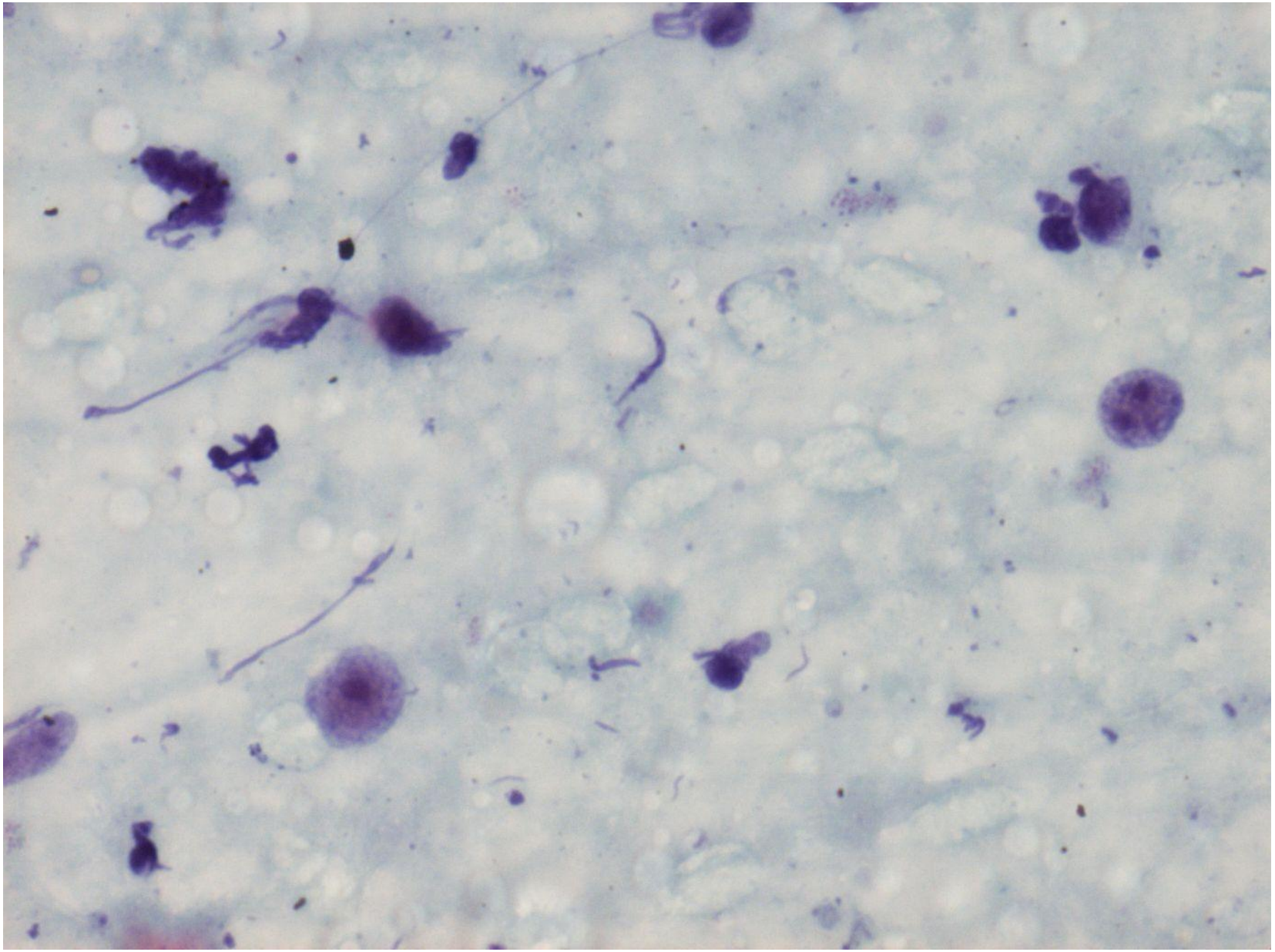

pap x 40 pos 11L

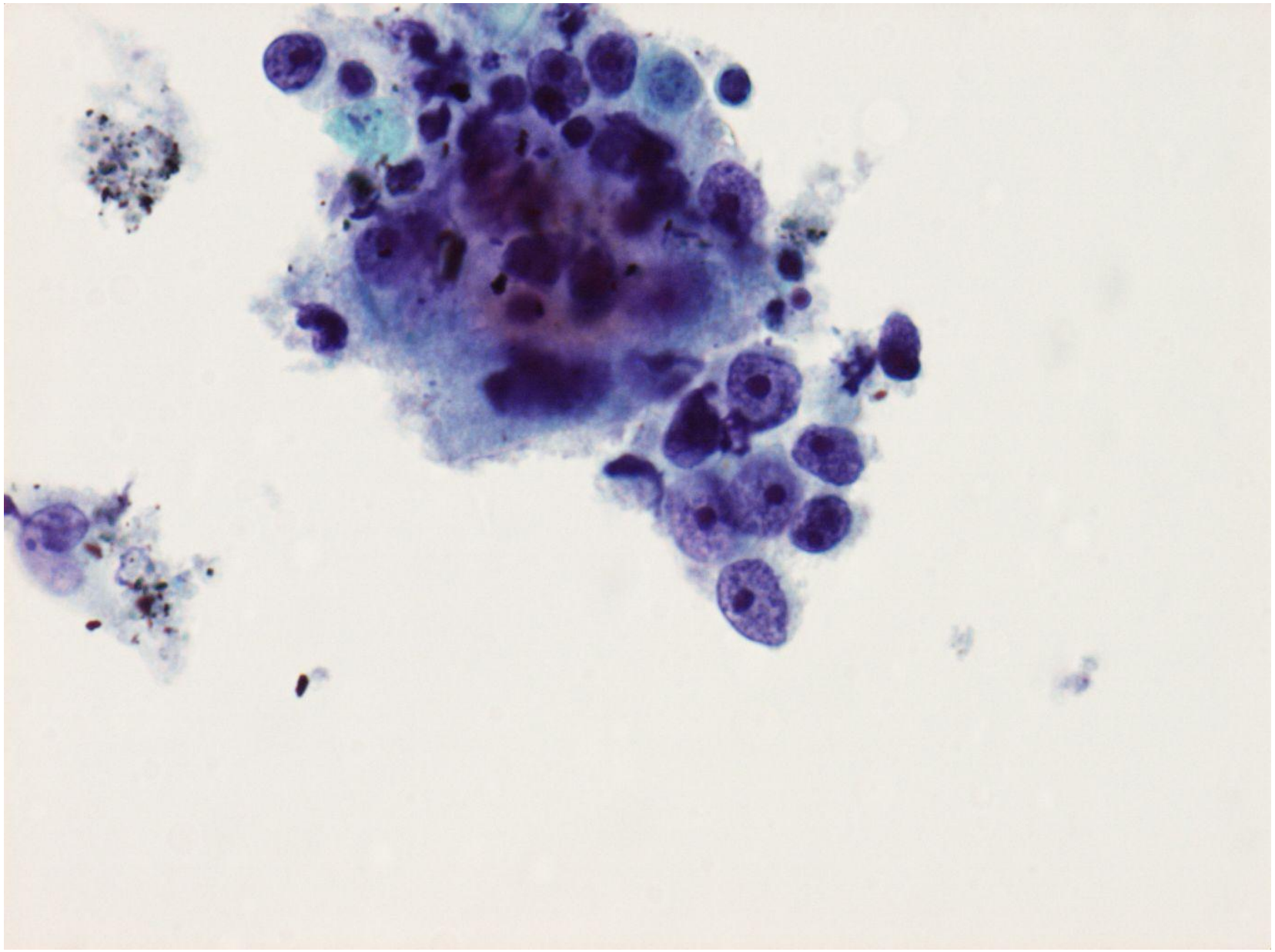

thinprep x 40 pos 11L

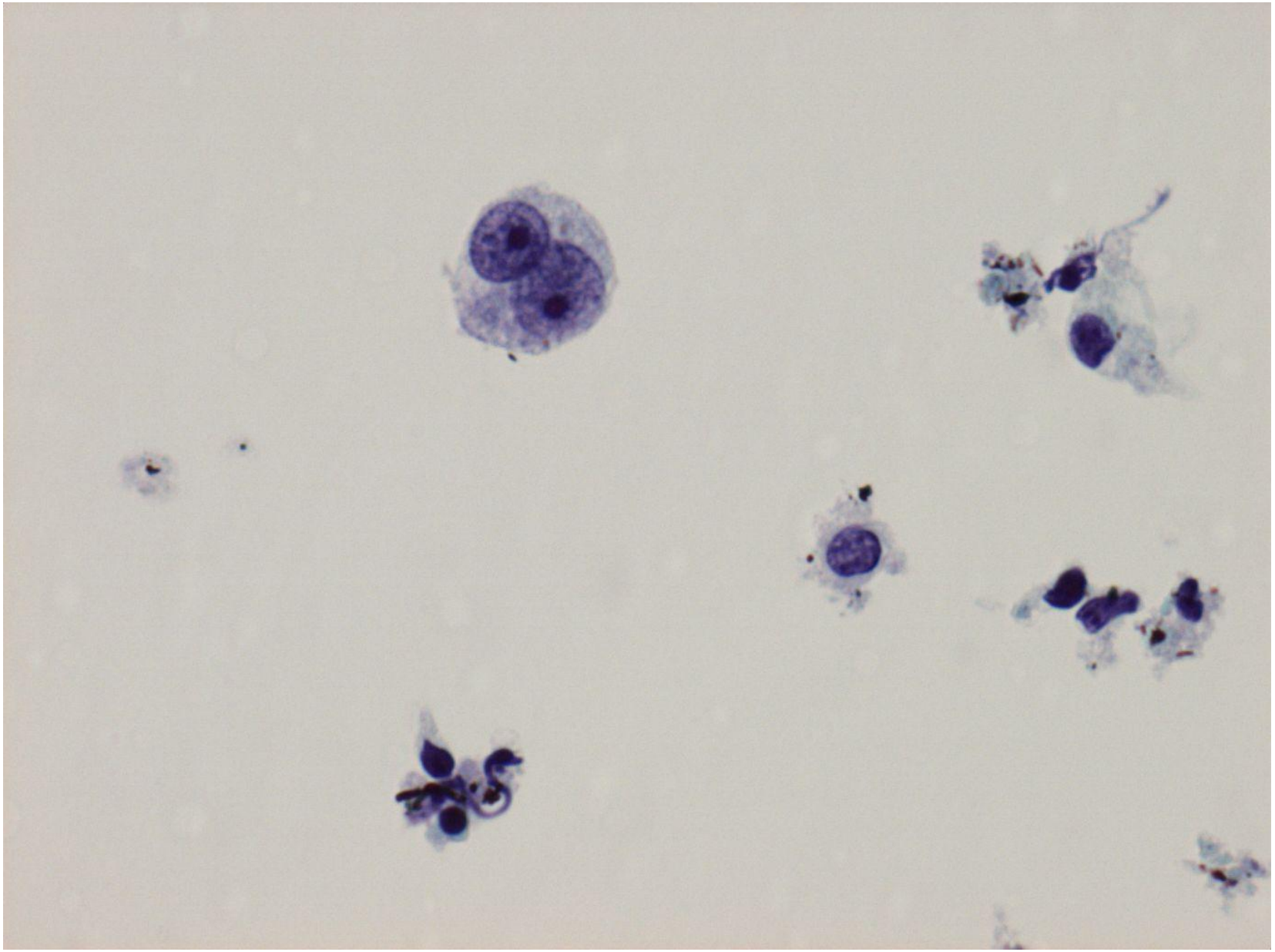

thinprep x 40 pos 11L

CD117 och PLAP positiv

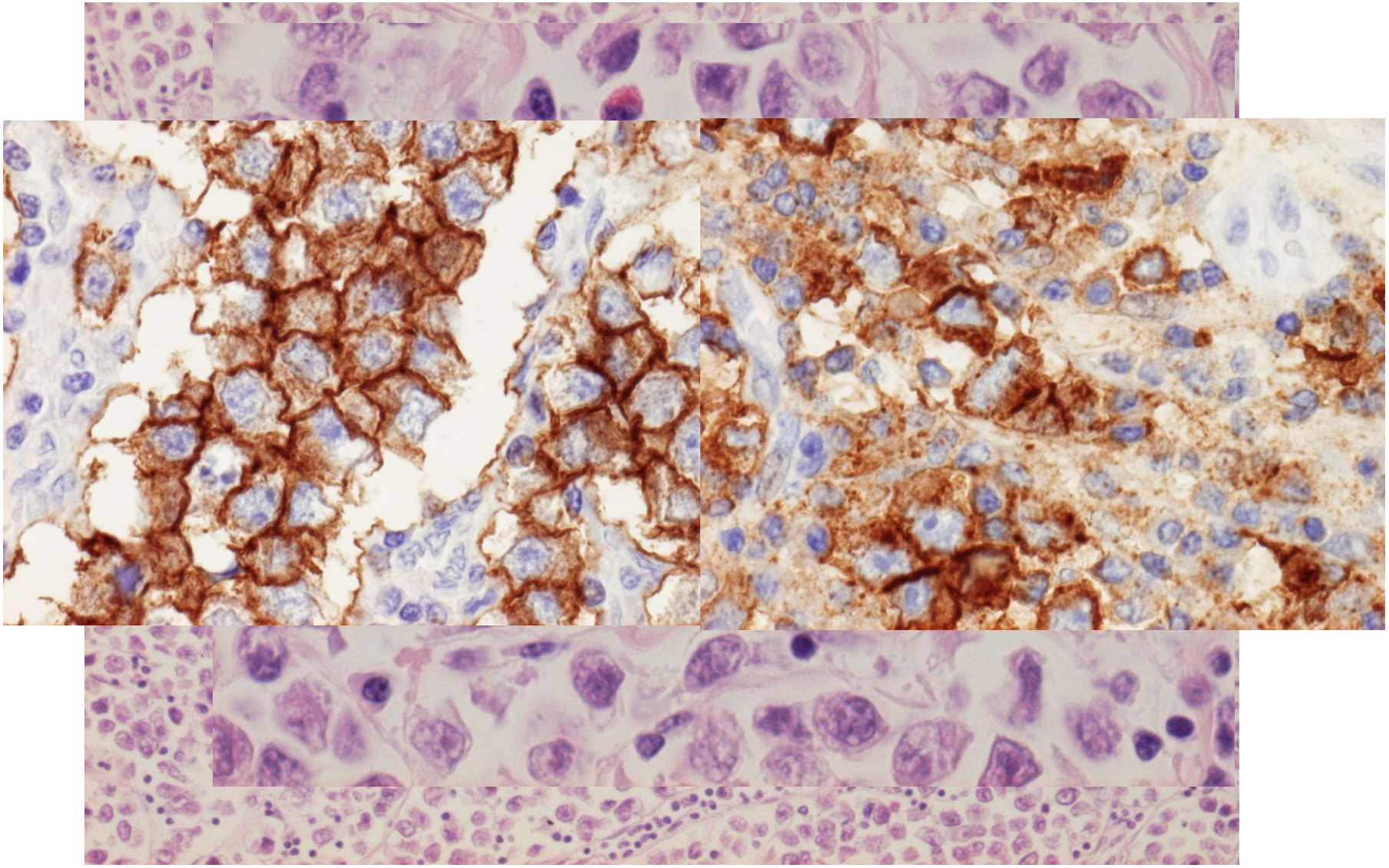

Histologi testis 2009 seminom

Finnålspunktion paraaortal mjukdelsmassa (bløddelsmasse) – seminom januari 2010

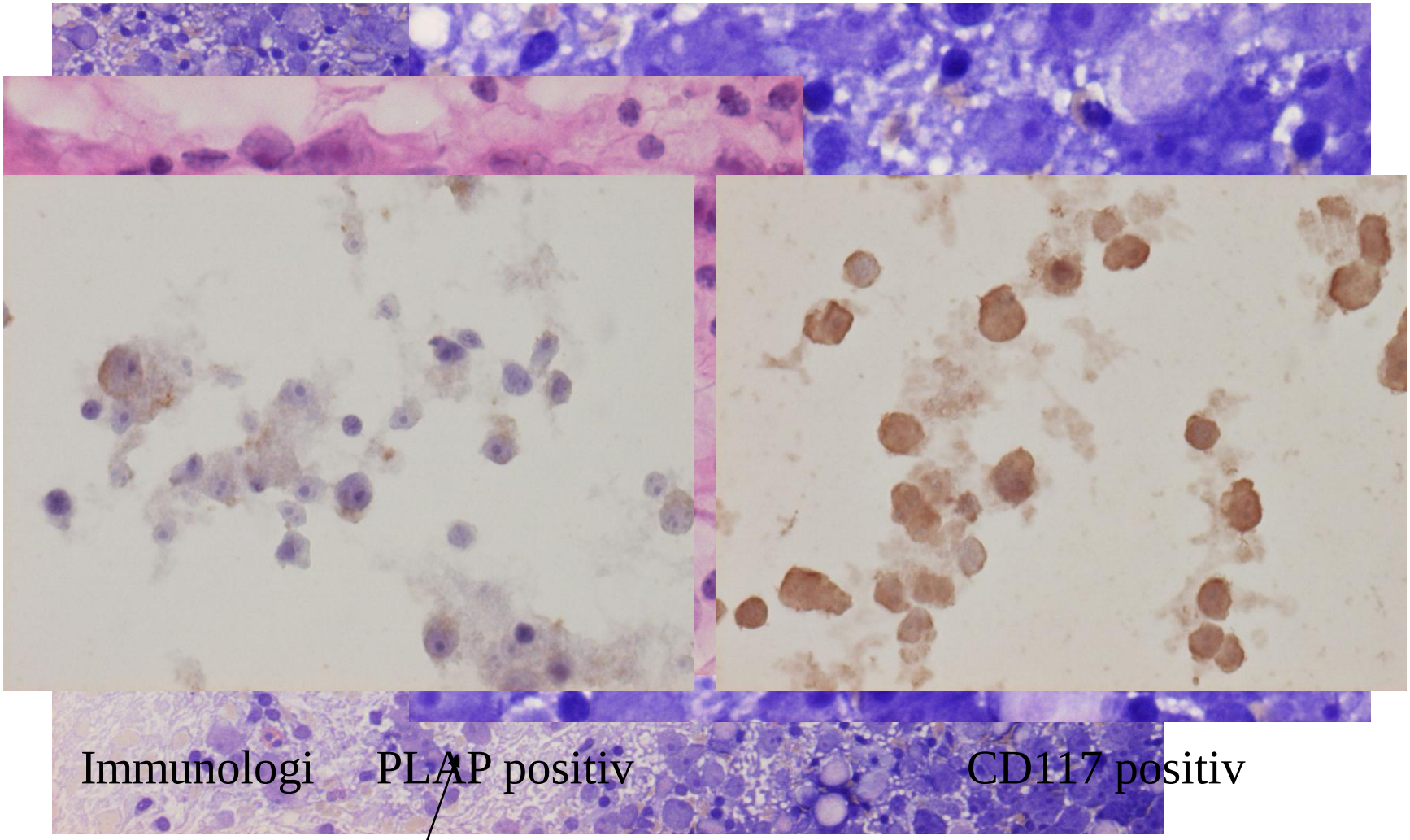

Immunologi PLAP positiv CD117 positiv

Tigroid bakgrund – klassiskt vid seminom.

Diagnose

Mikroskopisk undersökning visar nekrotisk bakgrund och tumörceller med stora nukleoler. Bild förenlig med spridning av patientens tidigare seminom.

EBUS

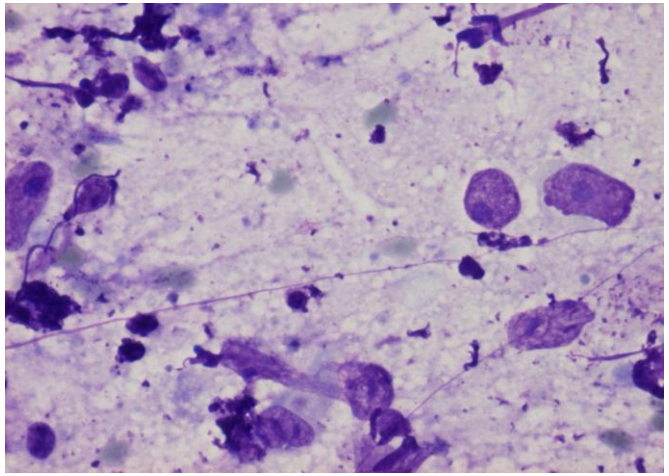

Punktion paraaortral

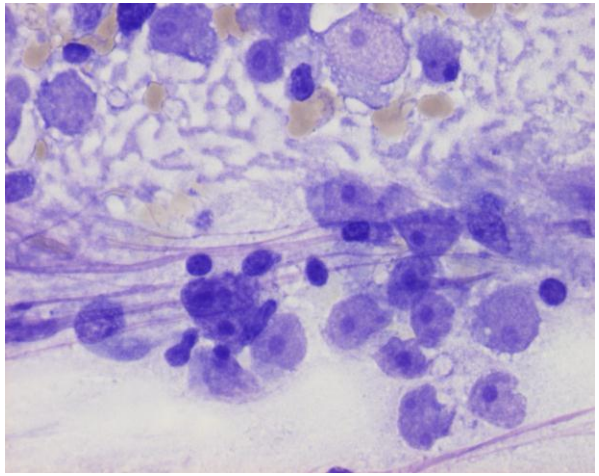
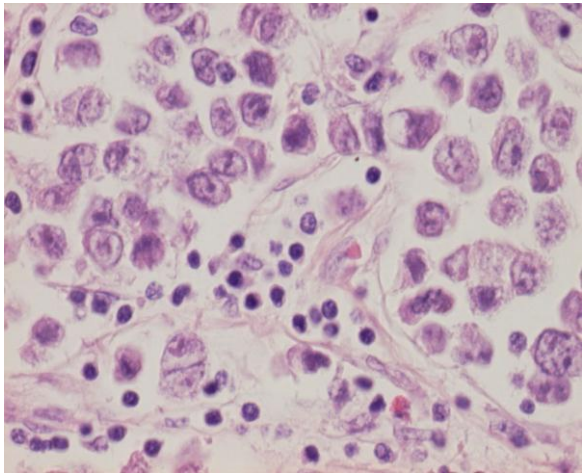
Testis