Herlev Hospital

Cytologi fra nedre luftveje

Birgit Guldhammer Skov, Overlæge, dr.med.
Patologi afdelingen, Herlev Sygehus, Afsnit Gentofte,

- Dansk Cytologiforenings´s årsmøde, Odense 29.2. 2008

Herlev Hospital

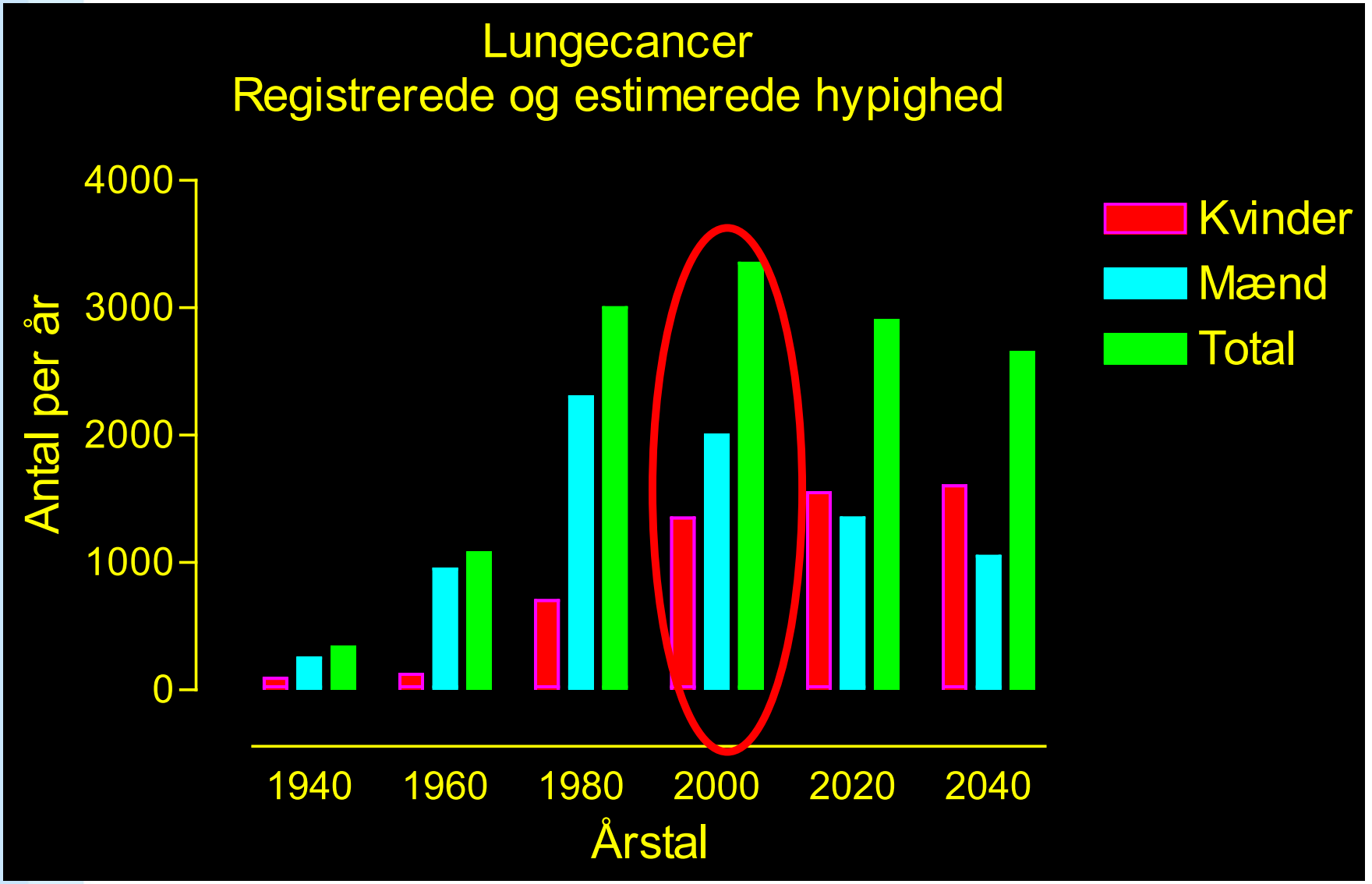

Figur 3A **Cancer incidens i 2000. Mænd. 10 hyppigste lokalisationer.**
Incidence of cancer in 2000. Males. 10 frequent sites.

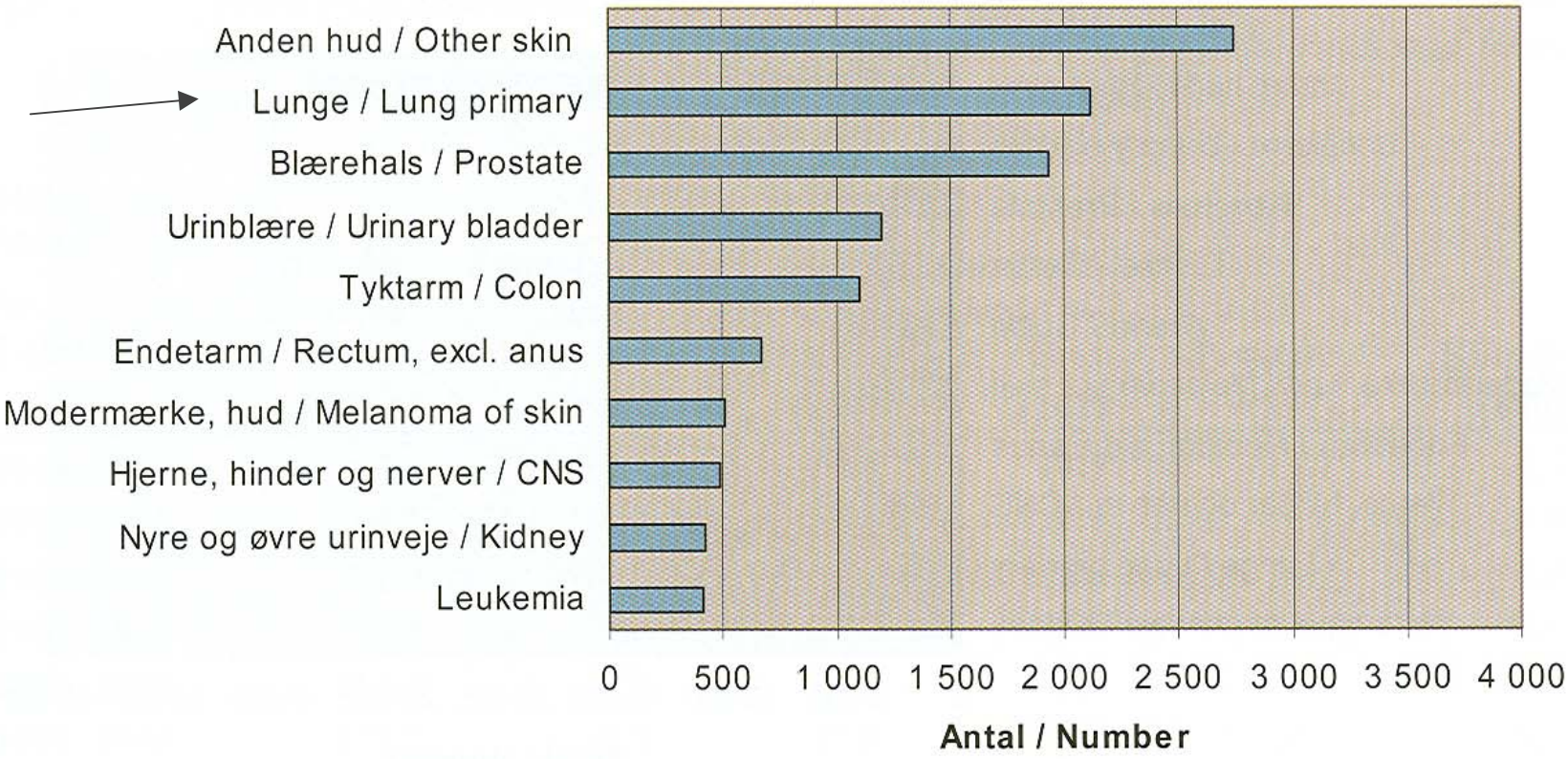

Figur 3B **Cancer incidens i 2000. Kvinder. 10 hyppigste lokalisationer.**
Incidence of cancer in 2000. Females. 10 frequent sites.

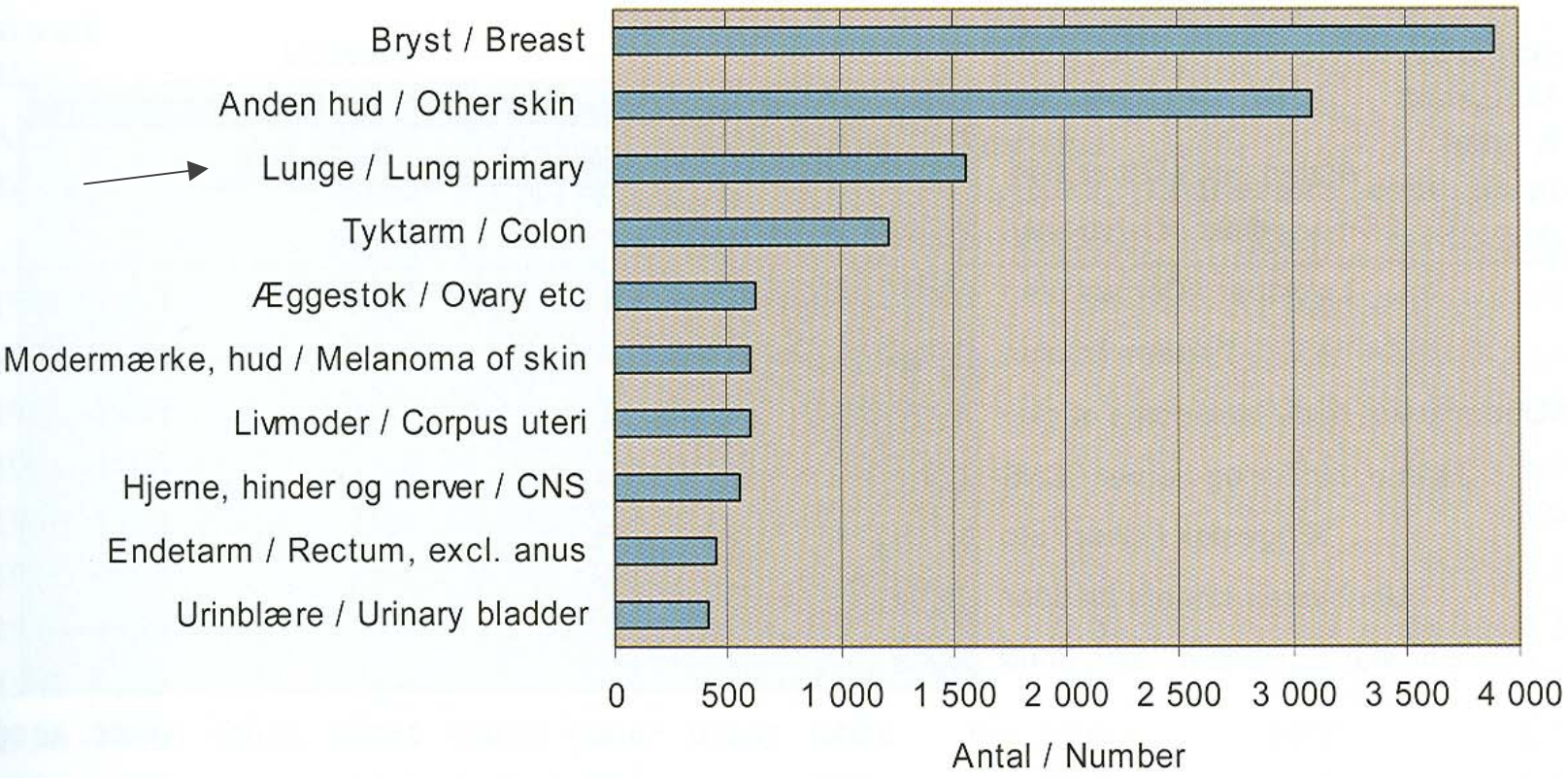

Herlev Hospital

Incidens (%) af c. Pulm NSCLC

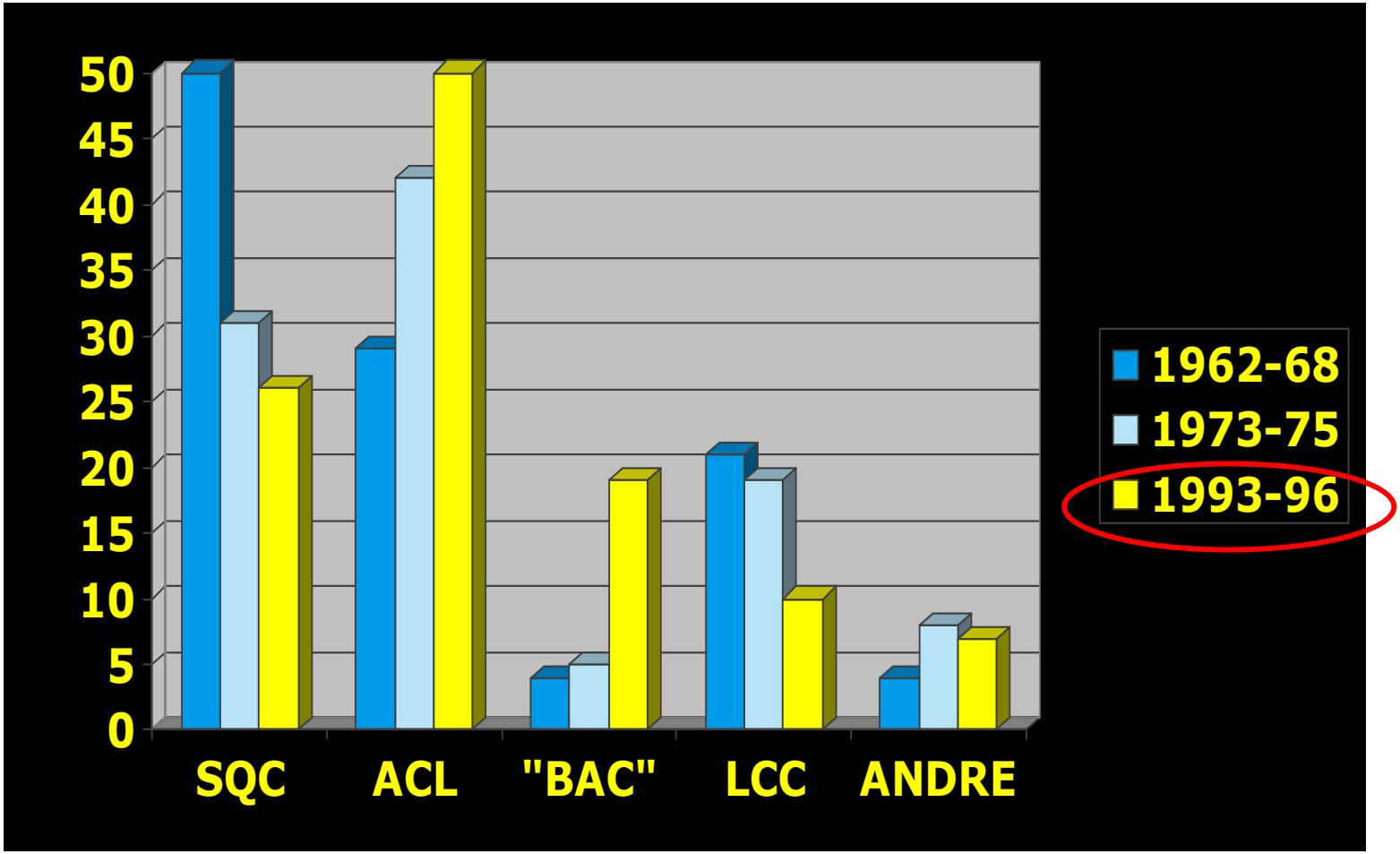

Bioptiske procedurer

- Fiberbronkoskopi – **FB (BW, BB, MB)**
- Transbronkial nåleaspirationsbiopsi - **TBNAB**
- Endobronkial nåleaspirationsbiopsi - **EBNAB**
- Mediastinoskopi
- Transthorakal nåleaspirationsbiopsi - **TTNAB**
- Endoskopisk transøsofagal ultralydsvejledt finnålsbiopsi -**EUS**
- Endoskopisk transbronkial ultralydsvejledt finnålsbiopsi -**EBUS-TBNA**

BW og BB (og ekspektorat)
Normale strukturer

- Pladeepitel
- Bronkialt epitel
  - Goblet og cilieret
- (Alveolært epitel)
- Makrofager
- Inflammatoriske celler

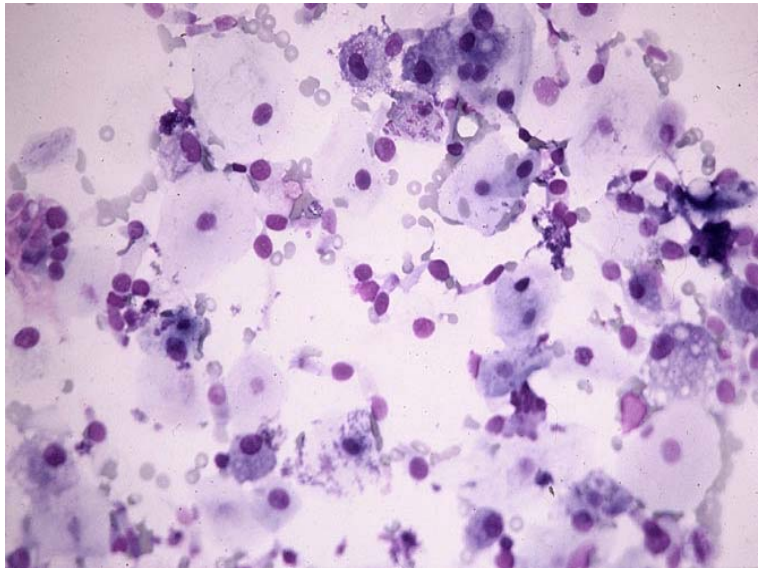

FNAB
Normale strukturer

- Bronkialt epitel
- Alveolært epitel
- Mesotel
- Makrofager
- Hud, bindevæv og fedt væv (thoraxvæg)
- Brusk/knoglemarv (ribben)
- Inflammatoriske celler

FNAB

Inflammatorisk non-neoplastisk proces

- Klumper af purulent materiale
- Mange granulocytter
- Granulært debris
- Makrofager, granulocytter, lymfocytter og plasmaceller
- Mikroorganismer
- *Udeluk bl.a.*: SQC, kaseøs nekrose, svampe

Keratiniserende celler kan ses ved:

- Primær pulmonal SQC
- KOL (Bronkitis)
- Infektioner fx Aspergillom
- Pneuminitis
- Infarkter
- Metaplasi, dysplasi, CIS
- Metastaserende SQC
- SQC i øvre luftveje
- Thymom

FNAB

Planocellulært karcinom

Kriterier for diagnose

- Enkeltcelle præsentation (især keratiniserende)
- Celleklumper/grupper
- Keratiniserende maligne celler (pearls, dyskeratoser)
- Perinukleær halo
- Bizarre former (aflange kerner i non-keratiniserende)
- Irregulær, kantet, hyperkromatisk kerne
- Nekrose
- N/C lav til høj
- Kan have prominerende nucleoler (især nonkeratiniserende)

Sensitivitet og specificitet i BB, BW og FNA afhænger bl.a. af:

- Tumor størrelse
- Tumor type
- Tumor lokalisation
- Antal prøver
- Bronkoskopørens erfaring
- Bioanalytikerens/Patologens erfaring

Falsk negative BB, BW og FNA kan skyldes:

- Sampling error
- Udtalt autolyse versus betydelig nekrose
- Perifert beliggende tumor (BW og BB)
- Små tumorer
- Benigne tumorer
- Bioanalytikerens/patologens fejlfortolkning

Falsk positive BB, BW OG FNA :

- Atypisk planocellulær metaplasi og dysplasi/CIS fortolket som SQC
- Regenerative forandringer
- Inflammations nekrose opfattet som tumor nekrose
- Atypiske cylinderepitel/pneumocytter
  - TB/sarkoidose, infarkter, viruspneumonier, KOL, astma, abces, DAD, interstitielle lungesygdomme, vaskulitis, kemo/stråle behandling m.fl.

CIS versus SQC – oftest ikke mulig - men

- Bizare former
- Udtalt keratinisering
- Irregulær kromatinisering
- Makronukleoler
- Høj cellularitet
- Tumor diatese
- Klinik
  - Synlig billeddiagnostisk tumor

Støtter SQC

Benigne versus maligne læsioner

Benigne

- Få atypiske celler
- Spektrum af atypi
- Velorgasiserede grupper
- Kohæsive – få enkeltliggende celler
- N/C normal (begge ofte øget)
- <4-6x kerneforstørrelse
- Glat kernemembran
- Fin/grov regelmæssig kromatinisering
- Cilier
- Regredierer

Maligne

- Mange atypiske celler
- Diskret population
- Disorganiserede grupper
- Dyskohæsive
- N/C høj
- <6x kerneforstørrelse
- Ireg. kernemembran
- Grov, ireg. kromatinisering
- Ingen cilier
- Progredierer

FNAB

Planocellulært karcinom

Vanskeligheder i diagnosen

- Nekroser i andre karcinomer
- Andre lavt differentierede NSCLC
- Inflammation med nekrose
- Giant celle reaktion på tumor
- Meget højt differentierede planocellulære karcinomer
- Metaplasi og dysplasi
- Mukoepidermoidt karcinom
- SCLC

SQC versus reaktive celler (FNAB)

	SQC	***Reaktiv atypi***	***Mesothel celler***	***Histio-cytter***
Celle arrange-ment	Clusters, enkeltlig-gende	Clusters, få/ingen enkeltlig-gende	Cohæsive sheets	Enkelt liggende, granulomer
Nuclei	Hyperkromati-ske, grov kromatini-sering	Smudgy kromatin (nusset)	Fin kromatini-sering	Bønneformet fin kromatini-sering
Nucleoli	Ofte fraværende	Fraværende (+ i repair)	Små	Meget små
Cytoplas-ma	Tæt	Tæt	Tæt	Kan være tæt (degenera-tion)

Diff. mellem primær og sekundær SQC

- ***Støtter primær***
  - Ingen kendt anden
  - Solitær, central
  - Endobronkial
  - Mod-lavt. diff.
  - Ikke keratiniserende
  - Evt. mucin prod. celler
- ***Støtter sekundær***
  - Kendt anden
  - Multiple, perifere
  - Extrabronkial
  - Højt-mod diff.
  - Keratiniserende
  - Ren plano.

Planocellulært karcinom BW og BB

Skyl (BW)/Ekspekt.

- Abnorm N/C
- Udtalt pyknose af kerner
- Enkelt liggende celler
- Næsten ingen sheets
- Ingen kernedetaljer
- Ingen nukleoler

Børstebiopsi (BB)

- Abnorm N/C
- Ofte ingen pyknose
- Få enkelt liggende celler
- Mange sheets -dårligt defineret cellegrænser
- Ofte kernedetaljer
- Ofte nukleoler

REGION H
Herlev Hospital

RESPIRATORY MEDICINE (2001) 95, 374–378
doi:10.1053/rmed.2001.1051, available online at http://www.idealibrary.com on IDEAL®

Value and accuracy of cytology in addition to histology in the diagnosis of lung cancer at flexible bronchoscopy

A. M. JONES*, I. M. HANSON†, G. R. ARMSTRONG† AND B. R. O'DRISCOLL*

*Departments of *Cardio-Respiratory Medicine and †Histopathology, Hope Hospital, Salford, U.K.*

There is still disagreement as to the value and reliability of wash and brush cytology, in comparison with histology, for the diagnosis of malignancy at flexible bronchoscopy. The present study compares the yield and concordance of findings from the two modalities for visible tumours at flexible bronchoscopy.

A single-centre study of 514 consecutive flexible bronchoscopy procedures, in which a lesion suspicious of cancer was seen and bronchial wash cytology, brush cytology and forceps biopsy samples were taken. All equivocal or suspicious results were taken as negative.

An overall yield of 89·3% was achieved using a combination of all three tests. This was greater for endobronchial than submucosal (95% *vs.* 86%) tumours. Cytology alone diagnosed 17·7% of cases. Use of all three modalities allowed tumours to be differentiated between small and non-small cell types in all but 5/459 positive cases (98·9%). There were only 3/313 cases in which there was a difference in cell type (small cell *vs.* non-small cell) between the two modalities.

We conclude that wash and brush cytology are valuable tools, in addition to forceps biopsy, at flexible bronchoscopy. All three tests should be performed routinely in cases of suspected malignancy.

Key words: bronchoscopy; cytology; lung cancer.

RESPIR. MED. (2001) 95, 374–378

© 2001 HARCOURT PUBLISHERS LTD

Introduction

Lung cancer has become the most common fatal malignancy in adults in the United Kingdom, with about 35 000 new cases per year (1). The British Thoracic Society guidelines for the care of patients with lung cancer state that histological or cytological confirmation should be sought in all cases unless a respiratory physician or other specialist has given an explicit opinion that this would be inappropriate (2). Histological or cytological confirmation is known to be associated with a higher rate of specific oncology treatment for lung cancer patients (3). The most commonly used procedure for establishing the diagnosis is flexible bronchoscopy. It is important that the maximum amount of diagnostic information is obtained at every bronchoscopy procedure, as if the test is negative the patient will usually require further investigations, incurring time delays and possible discomfort. Some authors suggest cytology does not add to the diagnostic yield from biopsy for endobronchial tumours (4), whilst others consider the two modalities as complementary (5,6).

This study examined the yield from cytology and histology in cases where a suspected endobronchial (exophytic) or submucosal (intra-mural or ulcerative) lesion was seen at flexible bronchoscopy. The results from the two modalities were directly compared. For those cases with negative or discrepant results, the patient's case notes were retrieved to try to establish the eventual outcome.

Materials and methods

Hope Hospital is a 1000-bed teaching hospital in inner-city Salford. This area has one of the highest standardized mortality ratios (SMR) for lung cancer in the U. K. (SMR 160—Salford and Trafford Health Authority 1994–1996 data). The Respiratory Unit at Hope Hospital performs approximately 400 flexible bronchoscopy procedures each year. The majority are undertaken in the investigation of a suspected underlying lung cancer (64%) or haemoptysis (14%). The records of all flexible bronchoscopy procedures performed in the respiratory unit from 1992 onwards are recorded in a computerized database.

Received 26 October 2000 and accepted in revised form 29 January 2001.

Correspondence should be addressed to: Dr Andrew M. Jones, Department of Cardio-Respiratory Medicine, H3 Teaching Block, Hope Hospital, Salford, M6 8HD, U.K.
E-mail: andmarkj@hotmail.com

0954-6111/01/050374+05 $35·00/0

© 2001 HARCOURT PUBLISHERS LTD

%-vis diagnostisk værdi af MB, BB og BL

Respir.med. (2001)95,374-78

- 514 cases med suspekt endobronkial eller submucøs tumor
- Alle fik foretaget MB, BW, BB
- Bronkoskopier lavet af 1 ud af 6 erfarne bronkoskopører
- Histologisk og cytologisk materiale vurderet af 1 ud af 3 erfarne patologer
- Flg. kategorier anvendt: SCLC, NSCLC, SQC, ACL, lymfom
- Alle suspekte/atypiske prøver er kategoriseret som negative

%-vis diagnostisk værdi af biopsi, BB og BL

Respir.med. (2001)95,374-78

Biopsi alene	10,7
Biopsi + BB	25,5
Biopsi + BL	4,7
Biopsi + BB + BL	30,7
• BB alene	8,0
• BB + BL	7,6
• BL alene	2,1
• Alle negative	10,7 (virker højt!)

(n=514)

%-vis diagnostisk værdi af biopsi, BB og BL

Respir.med. (2001)95,374-78

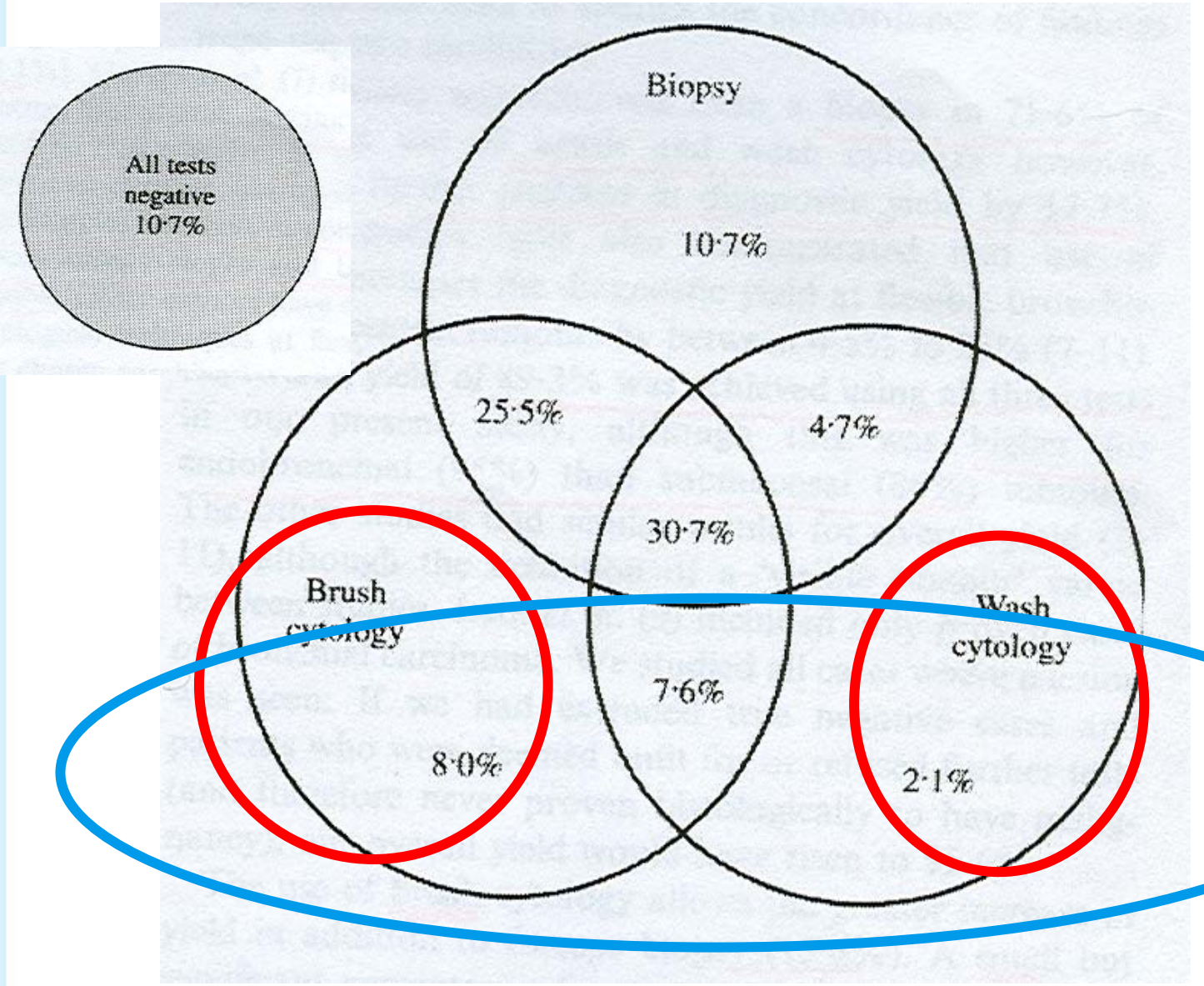

%-vis diagnostisk værdi af biopsi, BB og BW

Respir.med. (2001)95,374-78

- 17,7% havde positiv cytologi og negativ histologi
- Er det kun hos patienter med negativ MB man skal ofre tid på at undersøge BB og BW???

- Hvor mange MB og BB skal der tages?
- Blandingstumorer
- Erfaring fra ”de positive” cytologier
- Logistiske problemer
- Andre?

(n=514)

FNAB

- Sensitivitet: 75-95%
- Specificitet: 95-100%
- PV pos: 99%
- PV neg: 70%
- Overenstemmelse mellem cytologisk og histologisk diagnose: 70-85%
- SCLC versus NSCLC: 95-100%

Elongerede/spindel celler kan ses ved:

- Epiteloide celler
- Mesenkymale benigne og maligne tumorer
- Thymom
- Primær SQC
- Metastaserende SQC og evt. adenocarcinom

Vacuoliserede celler kan være:

- Primær ACL og (BAC)
- Reaktive glandulære celler (pneumoni)
- Pneumocystis carini
- Histiocytter
- Reaktion til kemo/stråle terapi
- Metastaserende adenocarcinom
- Mesotel

FNAB

Adenokarcinom

Kriterier for diagnosen

- Mellemstore til store celler med rigeligt cytoplasma, evt. vakuoliseret
- Sheets
- Rosetter, acinære/papillifere strukturer, clusters/balls
- Cylindroide epitelceller
- Runde til ovale, excentrisk placerede, vesikulære kerner med stor nukleole
- Ingen cilier

Papillære formationer kan ses ved:

- Adenocarcinom incl. BAC
- Reservecelle hyperplasi
- Creola bodies hos astma patienter
- Bronchieektasier

FNAB

Adenokarcinom

vanskeligheder i diagnosen af

- Andre lavt differentierede NSCLC
- (BAC)
- Metastatiske adenokarcinomer
- Neuroendokrine tumorer
- Udtalte inflammatoriske processer

Diff. mellem SQC og ACL
(lavt differentierende)

- ***SQC***
  - Irregulære sheets
  - Enkeltliggende celler
  - Cell-in-cell (”kanibalisme”)
  - Tæt cytoplasma
  - Tydelige cellegrænser
  - Central kerne
  - Grov, tæt kromatin
  - Små nucleoler
  - Keratin
- ***ACL***
  - Cell balls, acini
  - Enkeltliggende celler
  - Vacuoliseret cytoplasma
  - Utydelige cellegrænser
  - Ekcentrisk kerne
  - Fin kromatinisering
  - Store nucleoler
  - Mucin

Adenokarcinom BW og BB

Skyl (BW)/ Ekspekt.

- Store runde, polygonale tumor celler i clusters
- Ofte papiller med tredimentionalt lejrede celler
- Rigeligt cytoplasma
- Fine cytoplasmatiske vakuoler
- Indkærvning af kernen
- Nukleoler – evt. flere

Børstebiopsi (BB)

- Store (cylindride) celler
- Papillifere/glandulære clusters
- Sheets af store polygonale celler - overlapning
- Rigeligt cytoplasma - vakuoler
- Vesikulære kerner evt. inklusioner
- Ingen cilier
- Store nukleoler – evt. flere

Differentialdiagnoser
Primært pulmonalt Adenokarcinom

- Hyperplastisk bronkieepitel
- Viruspneumoni
- BOOP
- Harmartom
- COLD (ofte cilierede celler)
- Medikamenter (busulfan)/stråleforandringer
- SQC
- Metastase (mamma, nyre, GI, genitalia, prostata, lymfomer, MM)

Adenocarcinom versus reactive type 2 pneumocytter (FNAB)

	ACL		*Reactive pneumocytter*
Celle arrangement	Cellerig grupper, 3-D,acini, papiller, enkelt celler		Ikke så cellerige, tætte, irreg. grupper, få enkelt liggende
Celle ensartethed	Ensartede og atypiske		Polymorfe – normal/atypiske
N/C	Høj		Variende lav
Nucleus	Grov, granulær el. vesikulær, ireggulære		Varierende hyperkromasi, multinucleære
Nucleoli	Prominerende		Evt.
Cytoplasma	Basofil, vaculiseret		Cyanofilt, evt. vaculisering, cilier

”Små” celler kan være:

- SCLC
- Lymfocytter
- Degenererede bronkieepitelceller
- Reservecelle hyperplasi
- Lymfom/leukæmi
- Karcinoid tumor
- Metastase, især fra mamma og prostata

FNAB
SCLC

Kriterier for diagnosen

- Små til middelstore celler med intet eller sparsomt cytoplasma, ofte cellerig
- Spredte celler, nogle grupper
- Moulding og irregulære kerner, mitoser
- Tear drop celler, smadrede celler, tråde af kernemateriale
- Grov kromatinisering (evt. små nukleoler)

REGION
Herlev
Hospit

Birgit Guldhammer Skov
Overlæge, dr. med.
Patologisk-anatomisk institut
Amtssygehuset i Gentofte
2900 Hellerup - Tlf. 39 77 36 21

Anatomic Pathology/Original Article

Cytologic Features Useful for Distinguishing Small Cell From Non–Small Cell Carcinoma in Bronchial Brush and Wash Specimens

Charles D. Sturgis, MD,[1] Diana L. Nassar, SCT(ASCP),[1] Joyce A. D'Antonio, PhD,[2] and Stephen S. Raab, MD[1]

Key Words: Bronchial brush; Bronchial wash; Small cell carcinoma; Non–small cell carcinoma; Cytology/cytopathology; Regression analysis

Abstract

One blinded observer (C.D.S.) retrospectively reviewed 76 previously diagnosed and biopsy-confirmed malignant bronchial brush and wash specimens, 46 non–small cell and 30 small cell carcinomas, obtained from 55 patients. Each case was scored for the presence or absence of 36 standard criteria (architectural, cytoplasmic, and nuclear). Logistic regression analysis was used to determine which criteria were most useful for separating small cell from non–small cell lesions. Although no single criterion displayed 100% sensitivity and specificity for small cell cancer, univariate statistical analysis indicated that 3 individual criteria (nuclear molding, finely granular or "salt and pepper" chromatin, and scant delicate cytoplasm) were more than 90% sensitive and specific in cases of small cell carcinoma. The presence of nuclear molding alone provided the best fit for the logistic regression model. When nuclear molding was present, the odds of a small cell diagnosis increased more than 300-fold. Nuclear molding, finely granular or salt and pepper chromatin, and scant, delicate cytoplasm are the 3 most sensitive and specific cytomorphologic features traditionally used to separate small cell from non–small cell carcinoma. Nuclear molding alone represents the most significant cytomorphologic feature for distinguishing between these malignant lesions.

Lung cancer is the leading cause of cancer death for men and women in the United States, accounting for more cancer-related mortality since 1930 than all other cancer deaths combined.[1] Attempts

SCLC (BB og BL)

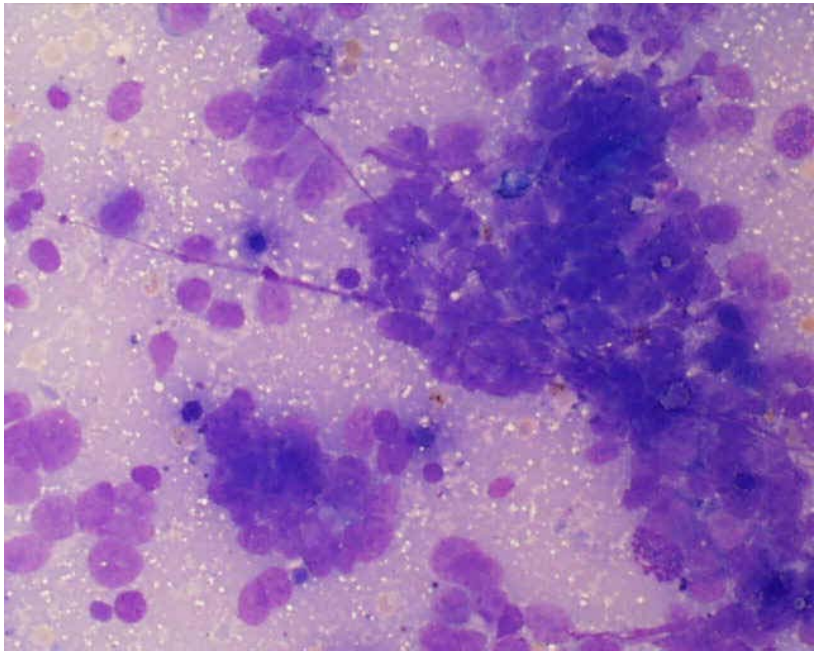

- Høj N/C
- Sparsomt cytoplasma *
- Basofilt cytoplasma *
- Moulding *
- Knusnings artefaktor *
- Apoptotiske celler
- Diatese/nekrose
- Granulært (”salt/peber”) kromatin *
- Utydelige/ingen nucleoler *
- Single-file anordning – løse grupper
- Cellerne 1,5 - 2 gange en lymfocyt *

* Kriterier brugt i regressions analyse, (AJCP, 2000 114(2) 197-202)

NSCLC - SQC (BB og BL

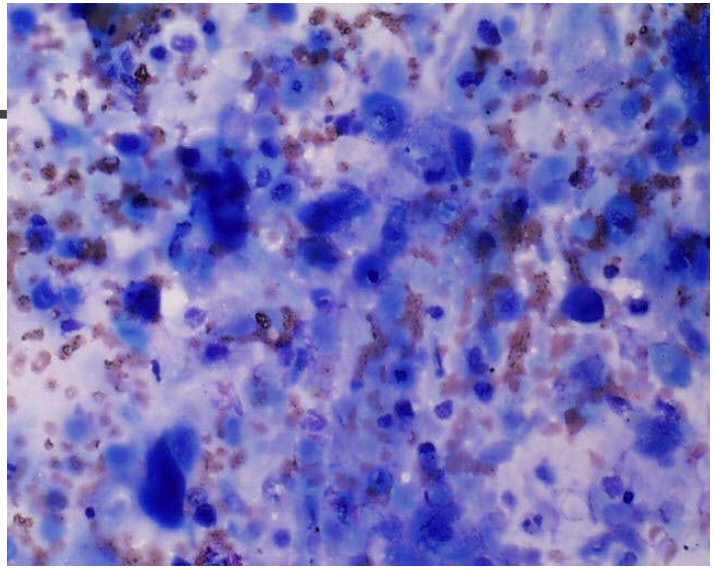

- Keratiniseret cytoplasma
- Intercellular broer
- Pearl formation
- Cell-in cell arangement
- Hyperkeratose
- Spindelceller
- Hyperkromatiske, regelmæssige kerner *
- Pyknotisk keratin
- Tydelige cellegrænser

* Kriterier brugt i regressions analyse, (AJCP, 2000 114(2) 197-202)

NSCLC – ACL (BB og BL)

- Utydelige cellegrænser
- Multiple nucleoler – macronucleoler *
- Intracytoplasmatisk mucin - skumagtigt cytoplasma *
- Vesikulære kerner - grov kromatinisering
- 3-dimentionelle grupper
- Irregulære kernemembraner
- Kerneoverlapning
- Kirtelformationer – papillifere s
- Tumor kæmpeceller

* Kriterier brugt i regressions analyse, (A

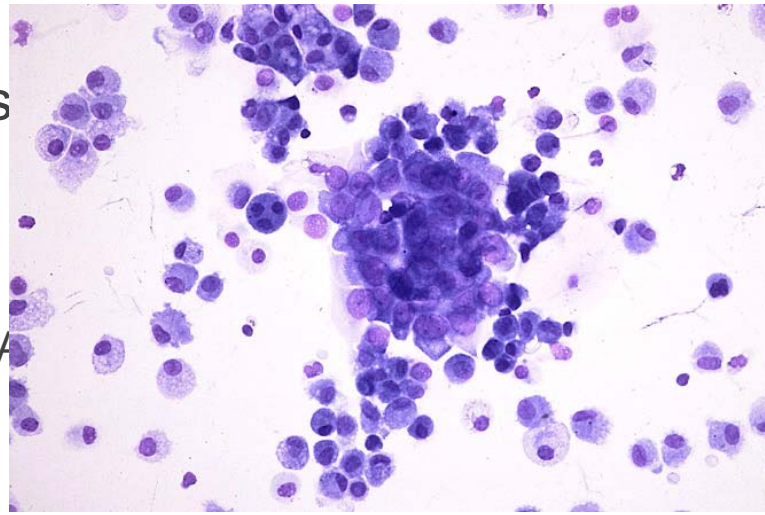

- **Moulding – bedste diskriminator**

- Fint granulært kromatin (”salt-peber”)

- Sparsomt cytoplasma

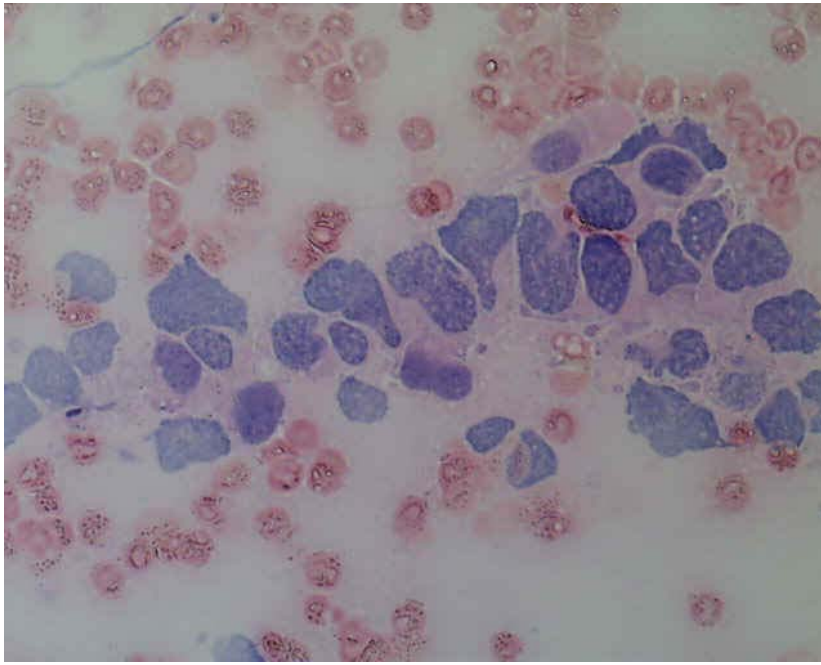

FNAB
SCLC
vanskeligheder i diagnosen

- ”Combined” karcinomer
- Andre dårligt differentierede, primære karcinomer
- Low grade tumorer (fx. karcinoider)
- Andre karcinomer med kvæstede celler
- Lymfomer, blastomer, tymom
- Metastaser

Diff. mellem lavt. diff. SQC og SCLC

- ***SQC***
  - Cell-in-cell
  - Ingen moulding
  - Nucleoler
  - Tydelige cellegrænser
  - Tæt cytoplasma
  - Ingen knusnings artefakter
  - Evt. granulomer
- ***SCLC***
  - Indian file
  - Udtalt moulding
  - Ingen nucleoler
  - Utydelige cellegrænser
  - Sparsomt cytoplasma
  - Knusnings artefakter
  - Ingen granulomer

Diff. mellem lavt. diff. SQC og SCLC IH

(Mod Pathol 2005;18:111)

	Negativ	Svag	Moderat	Kraftig
SCLC TTF1	7%	0	0	93%
SQC TTF1	96%	4%	0	0
SCLC Høj MW Keratin	100%	0	0	0
SQC Høj MW Keratin	0	0	0	100%

FNAB

Karcinoider

Kriterier for diagnosen

- Cellerig
- Enkeltliggende celler med nogle trabekler og små cellegrupper
- Ensartede celler med lidt cytoplasma
- Runde eller ovale kerner med fin kromatinisering og små nukleoler
- Baggrund med små kar

FNAB

Karcinoider

vanskeligheder i diagnosen

- Atypiske karcinoider (tumorlet)
- SCLC
- Lymfom
- ACL og BAC
- Hamartomer
- Andre småcellede tumorer
- BOOP

Multinucleære celler kan ses ved:

- NSCLC, fx sarcomatoidt karcinom
- MB. Hodgkin
- Metastaserende choriocarcinom
- Reaktion til kemo/stråle terapi
- Reaktive brokiale celler (efter bronkoskopi)
- Virale pneumonier fx herpes og mæslinger
- Granulomatøse sygdommer (TB, sarkoidose, svampeinfektioner)
- Interstitiel giant cell pneumoni
- Lipid/aspirations pneumoni
- Megacaryocytter
- Pneumothorax

Makronucleoler kan ses ved:

- Primær ACL
- (Lavt diff. SQC)
- Giant cell carcinoma i lunge
- Large cell carcinoma i lunge
- Metastaserende adenocarcinomer (fx. seminom, HHC)
- Malign melanom - MB. Hodgkin
- Tissue repair – visse infektioner
- Reaktion til kemo/stråle terapi

Pigmenterede celler kan være:

- Hæmosiderin holdige makrofager (rygere, kronisk blødning, infarkt, Mb. Cordis)
- DIP
- Kulholdige makrofager (rygere og byboer)
- Malignt melanom
- Vegetabilske celler

Infarkt – typiske fund

- Benigne, reaktive epitelcelelr
- 2-dimentionelle flager af epitelceller
- Få enkeltliggende epitelceller
- N/C øget, nucleoler, mitoser
- Pigmentholdige makrofager