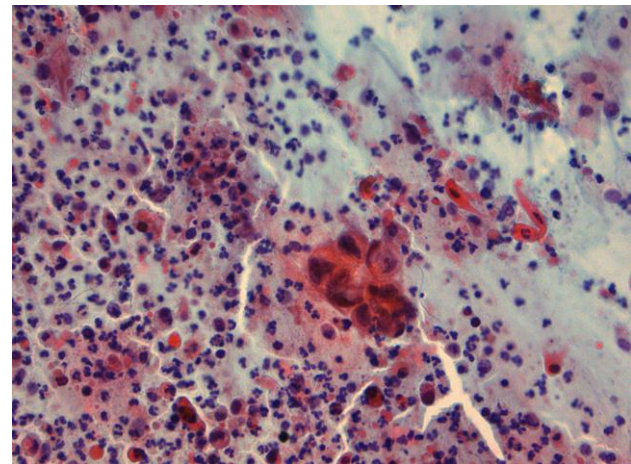
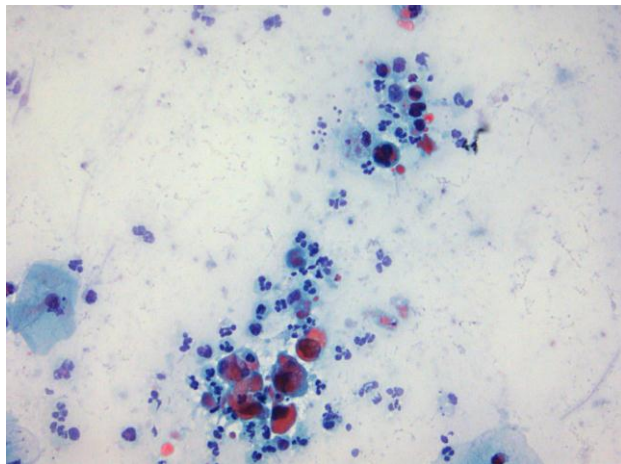
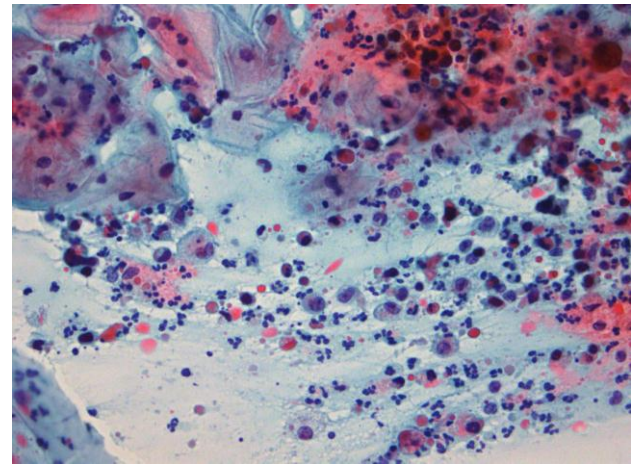
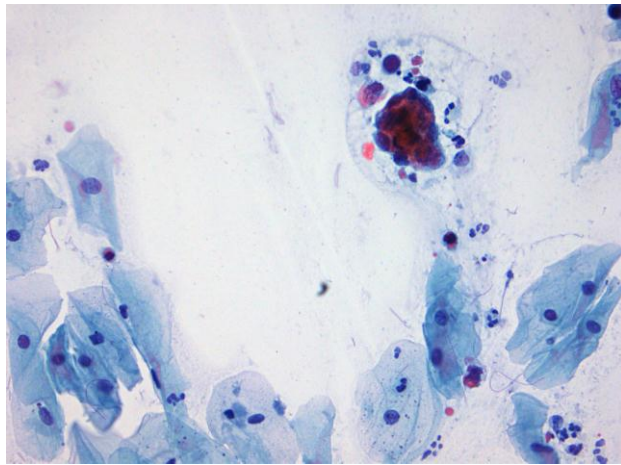


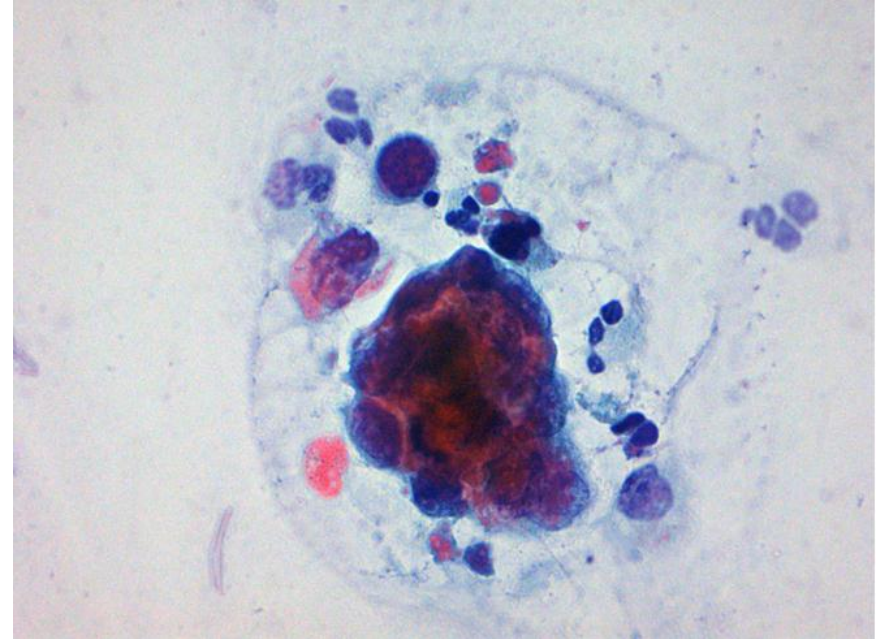
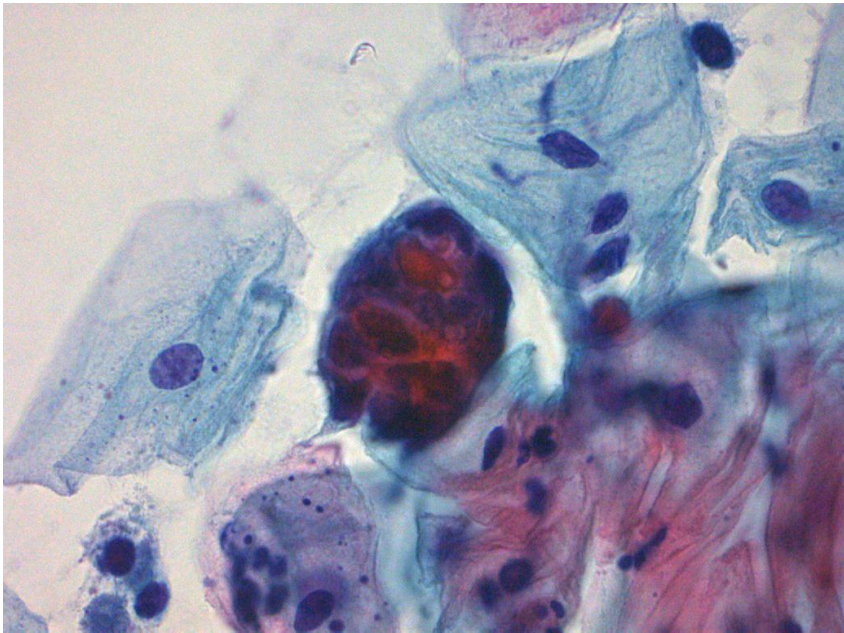
Case 2

69 år, postmenopausal blødning, ikke tidligere undersøgt



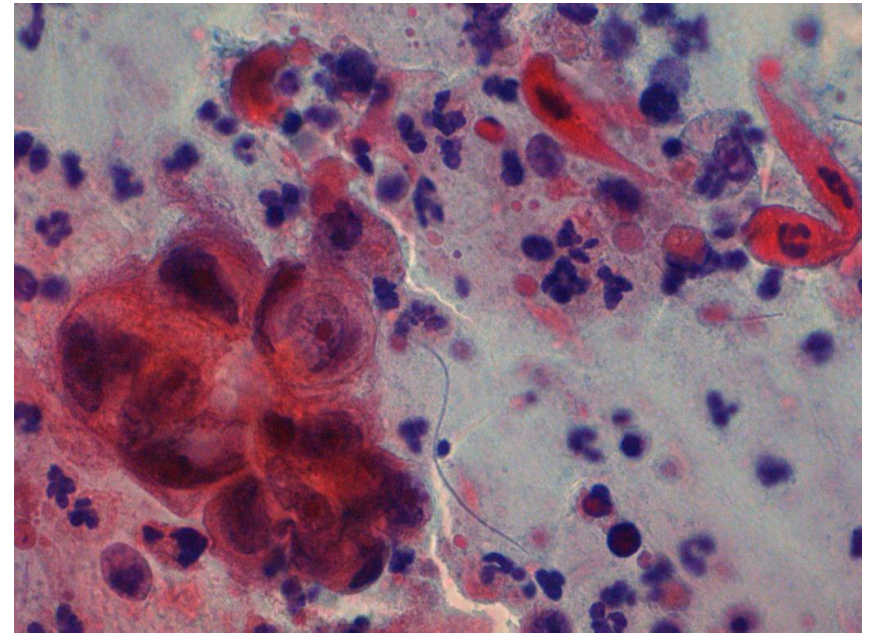
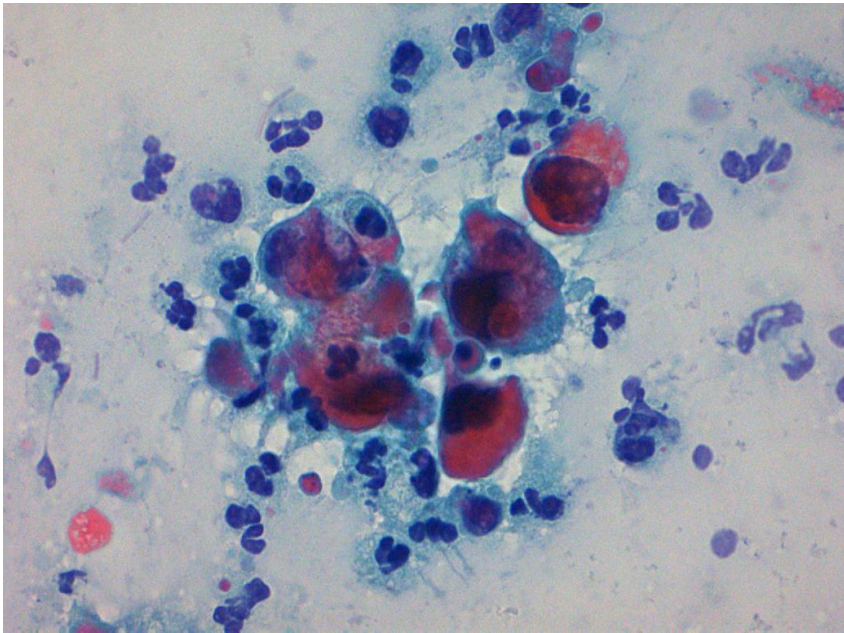
Case 2

69 år, postmenopausal blødning, ikke tidligere undersøgt



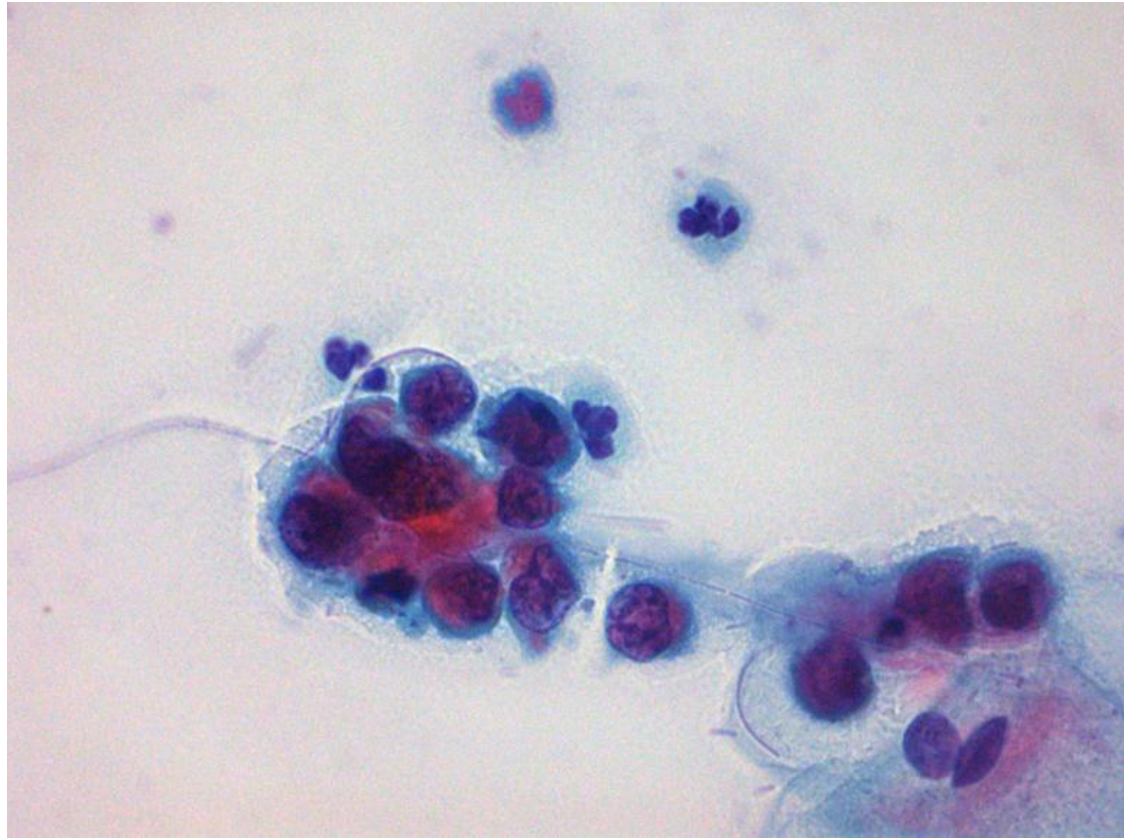
Case 2

69 år, postmenopausal blødning, ikke tidligere undersøgt



Case 2

69 år, postmenopausal blødning, ikke tidligere undersøgt



Case 2

Corpuskrab og uterus med adenokarcinom

