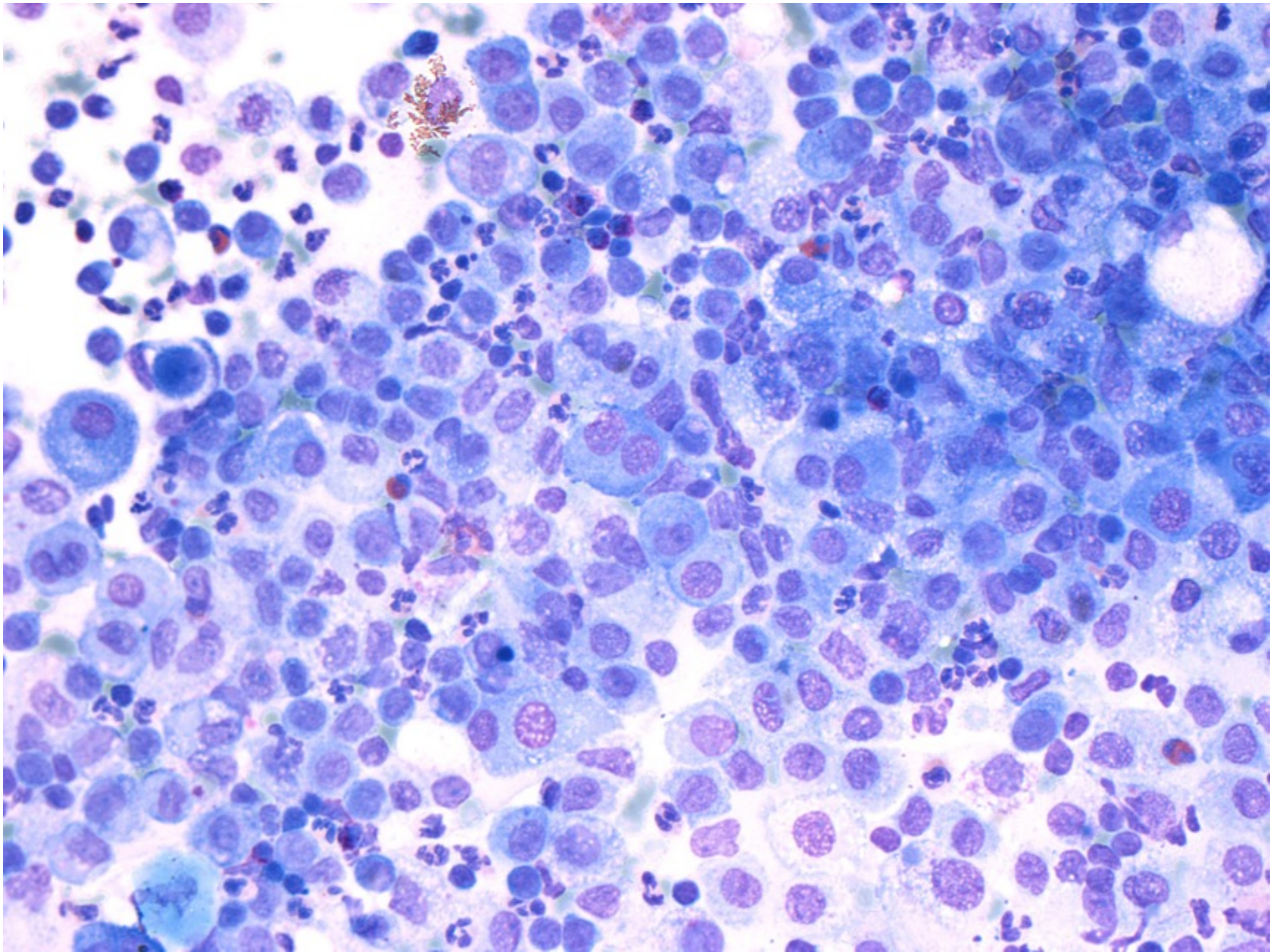
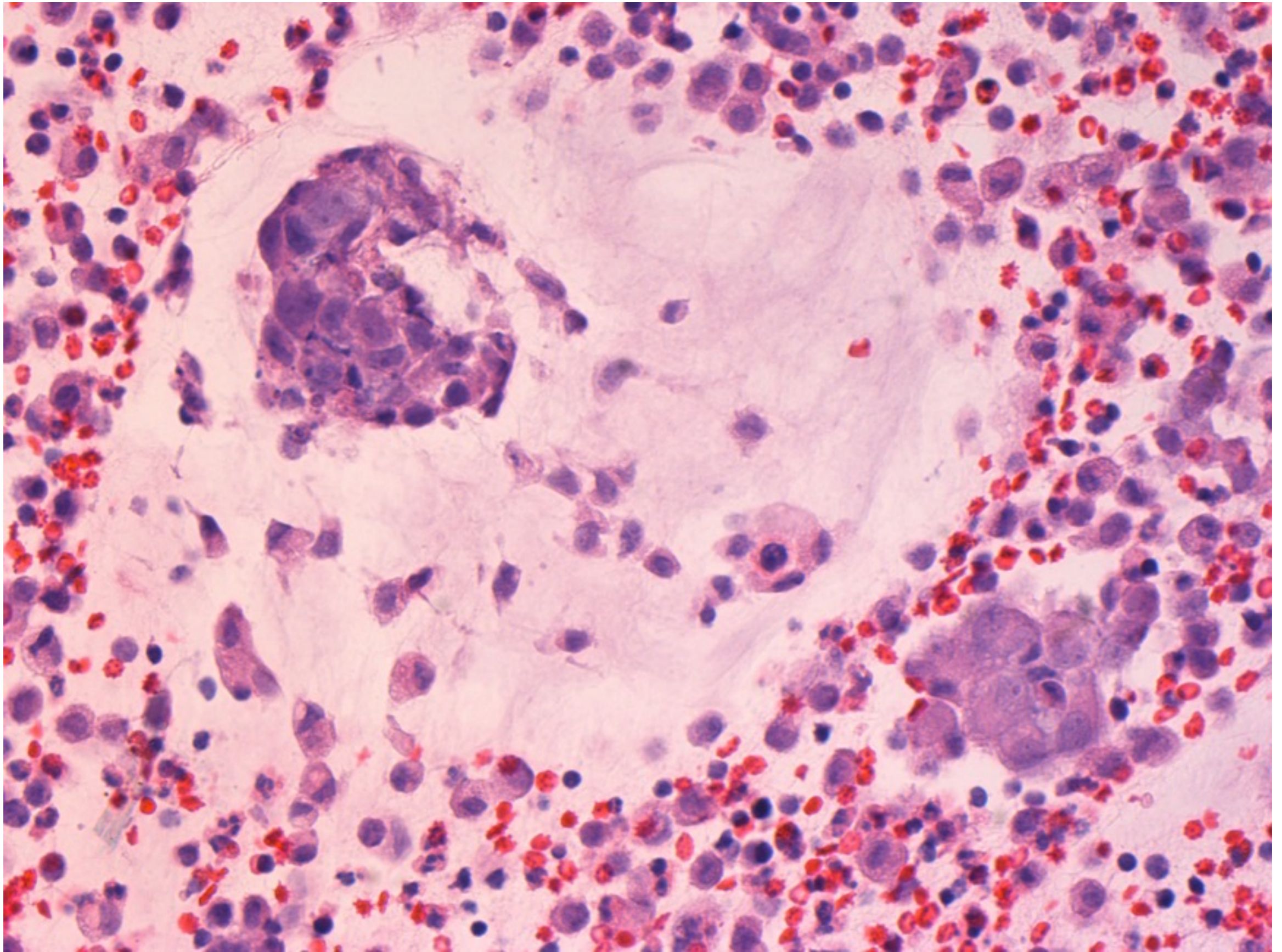


## **Kliniske oplysninger:**

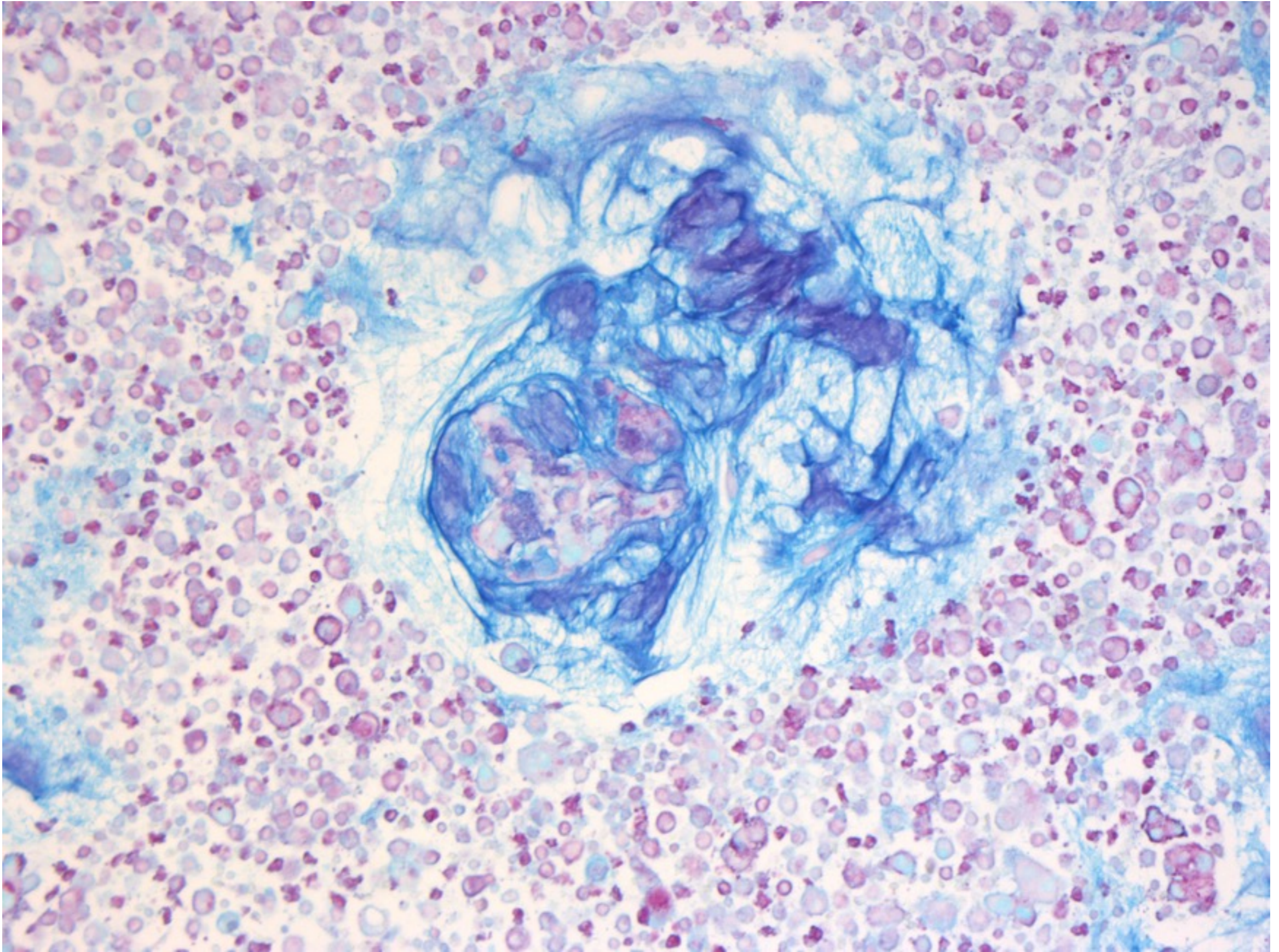
56 årig kvinde acites og pleuravæske. Dissimineret tumor  
Væske fra pleura.



Udstrygning, giemsa x 63



Koagel, HE x 63



Koagel, PAS x 63