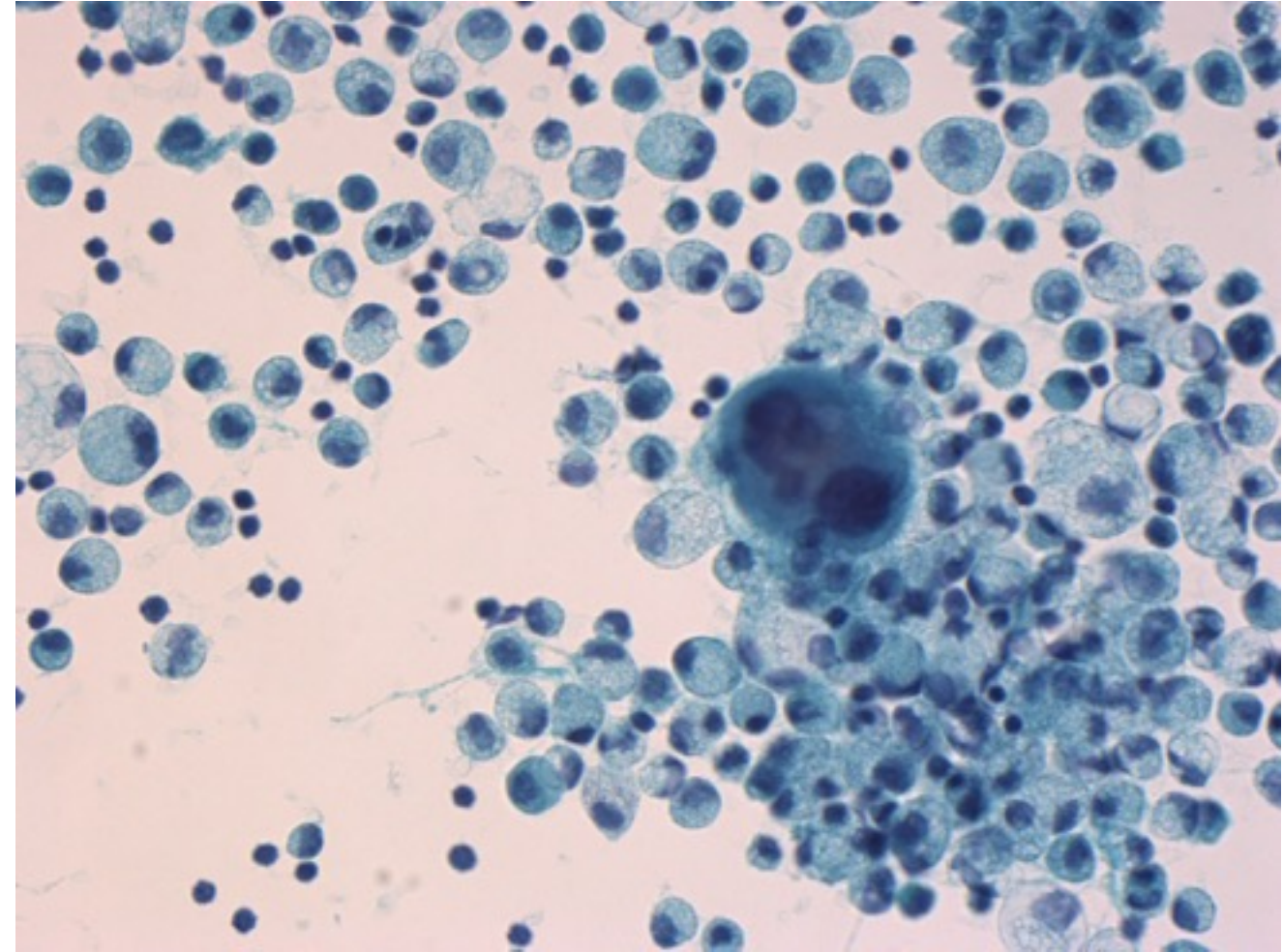
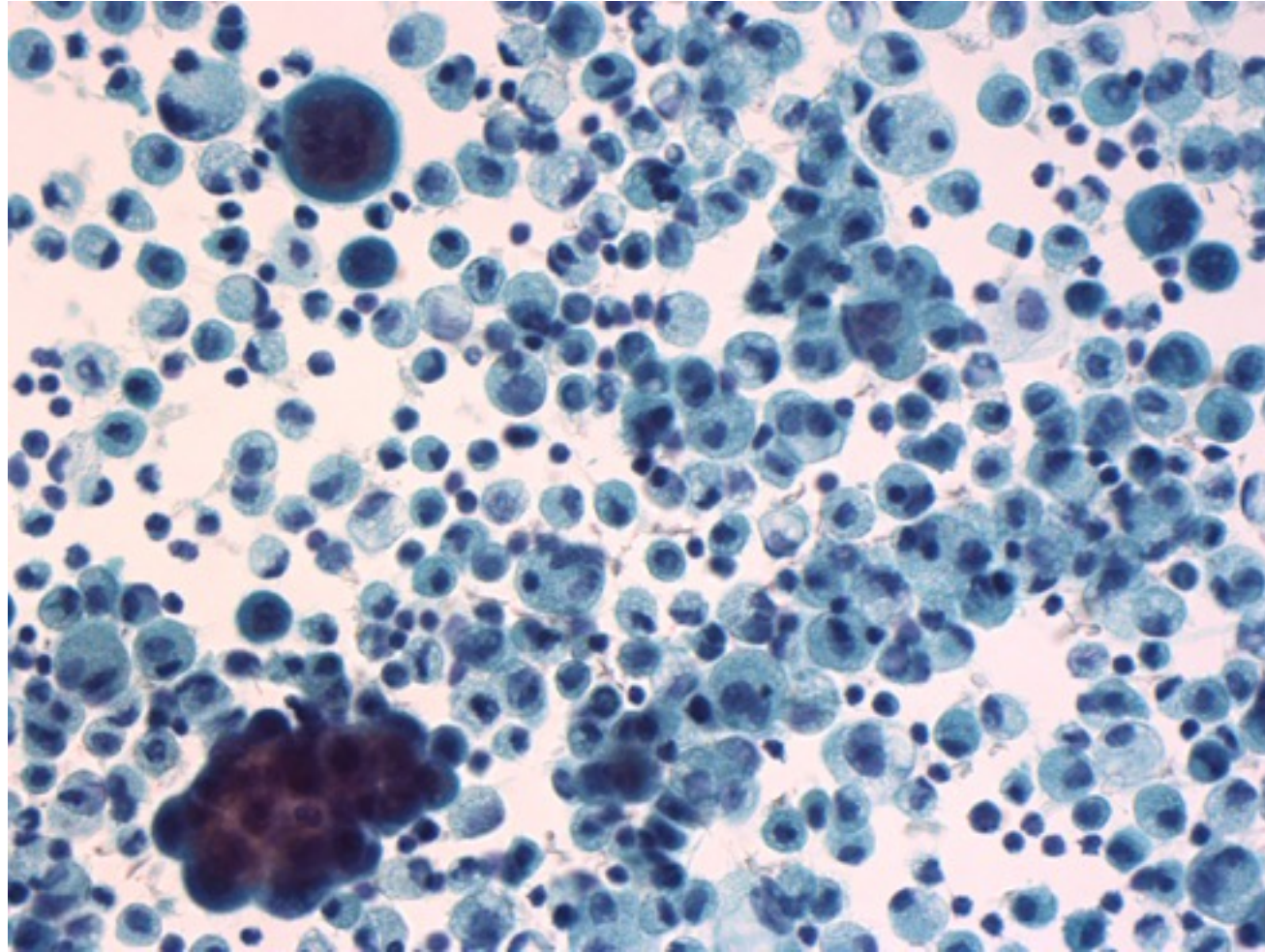
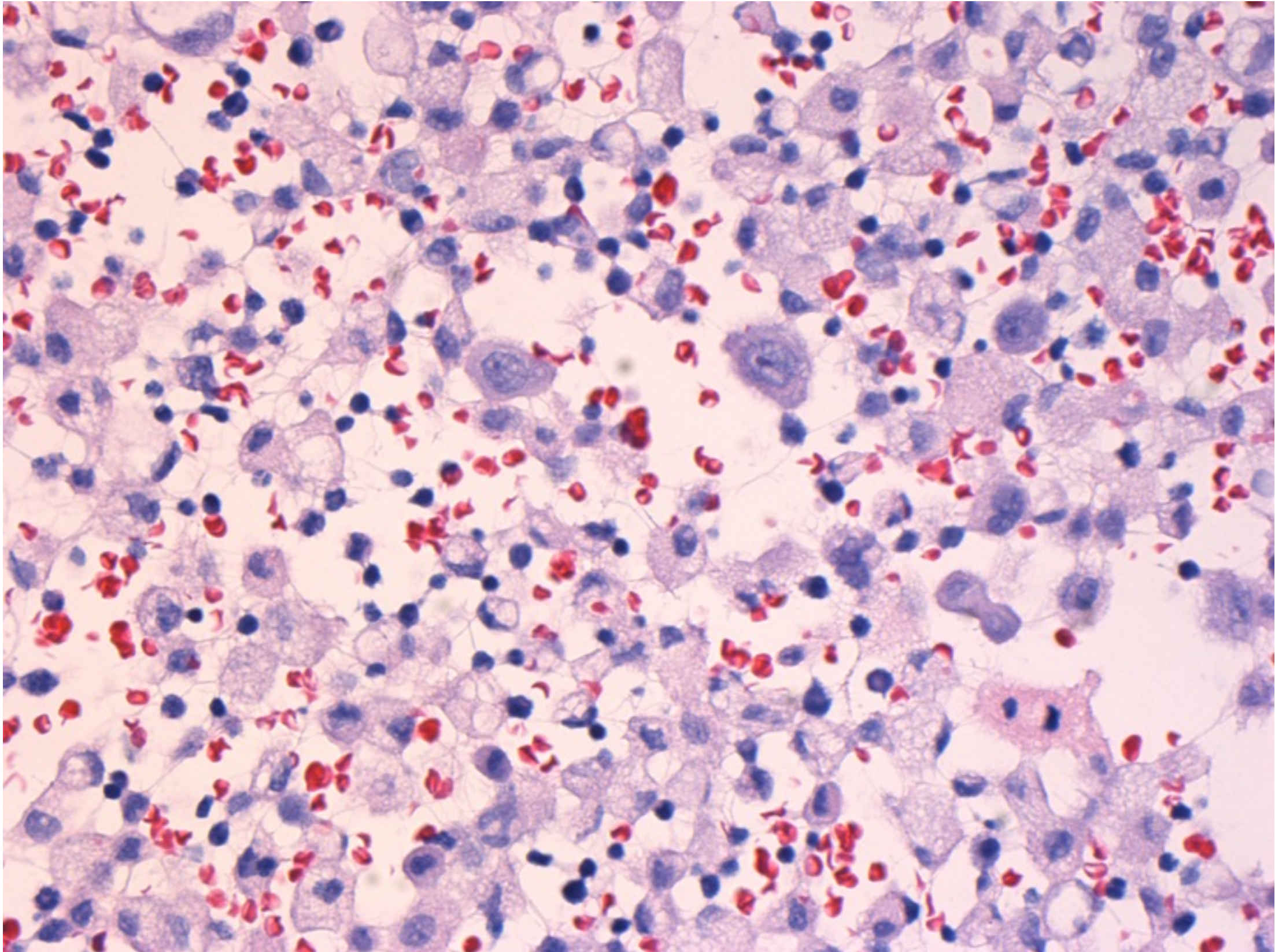


Kliniske oplysninger:

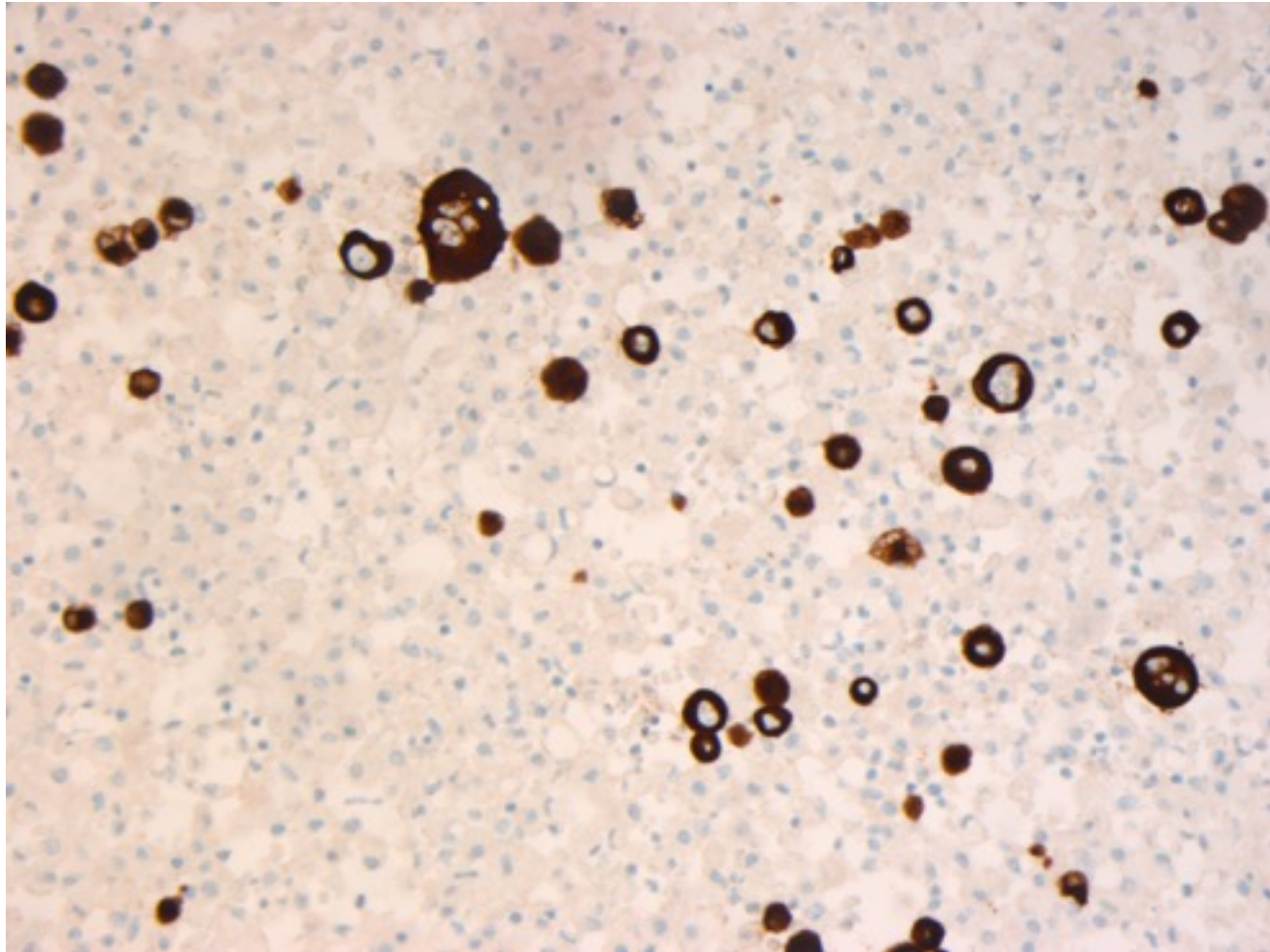
75 årig mand. Pleural effusion. Malign ?



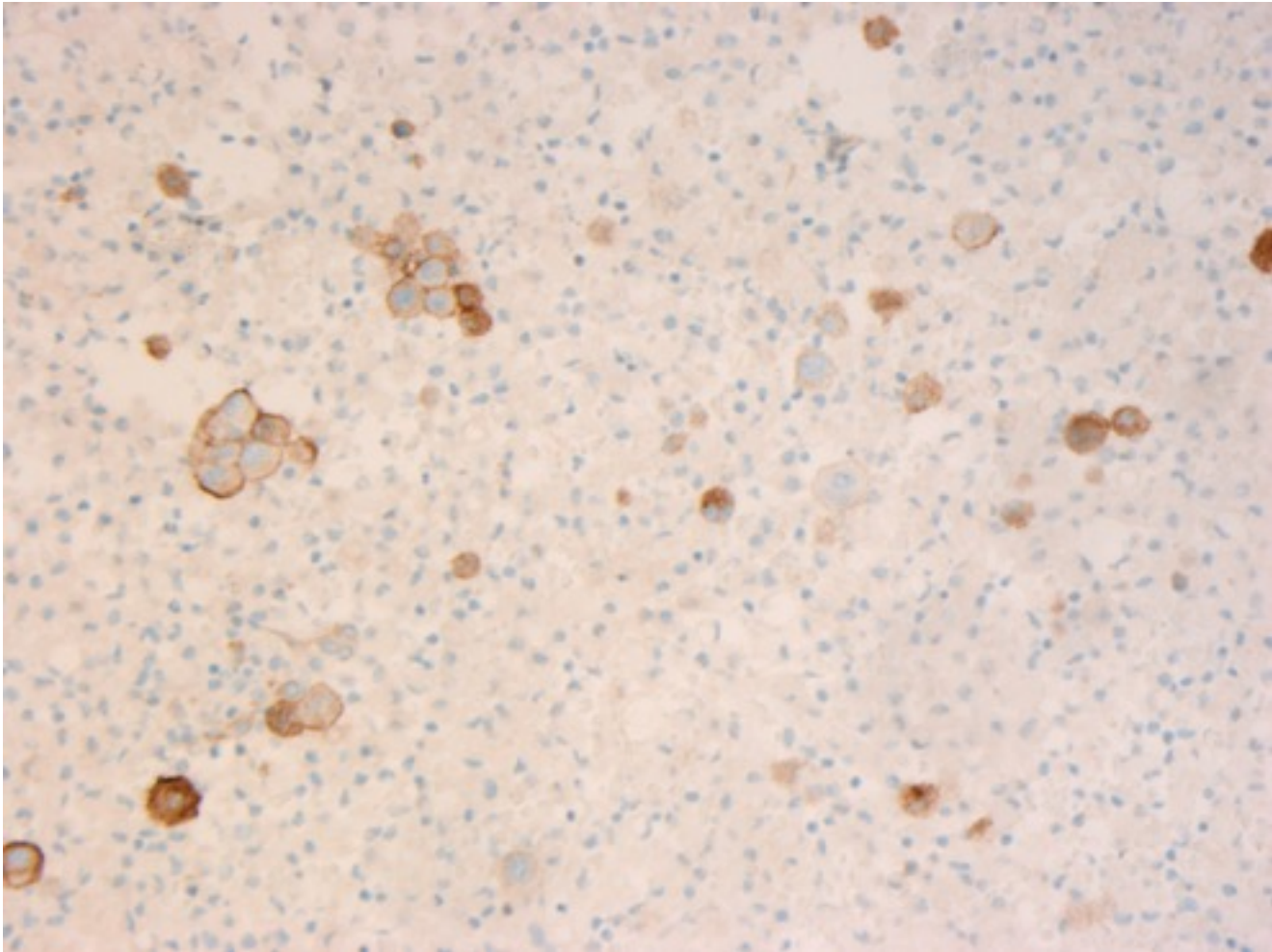
Udstrygning, giemsa x 40



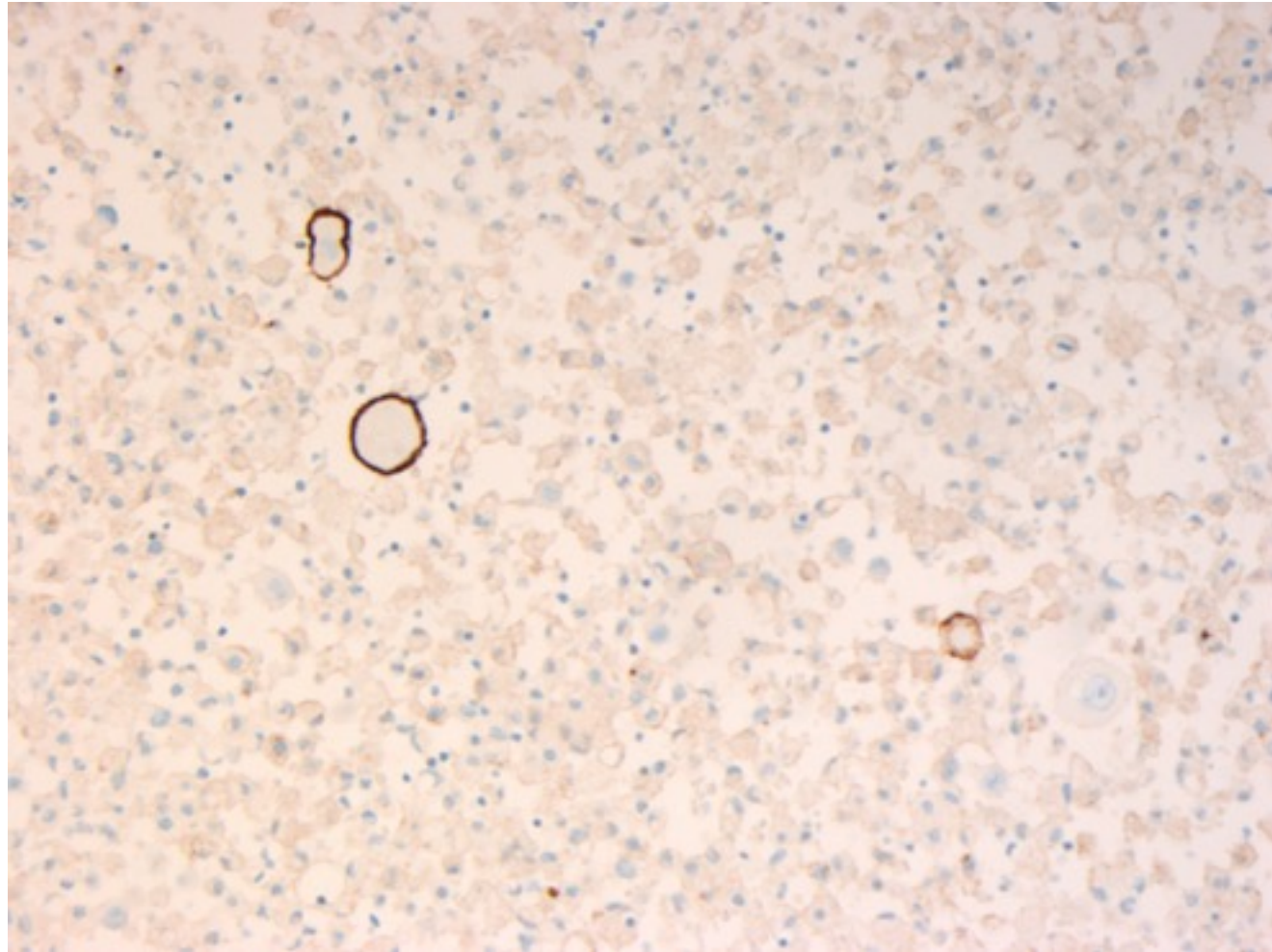
Koagel, HE x 40



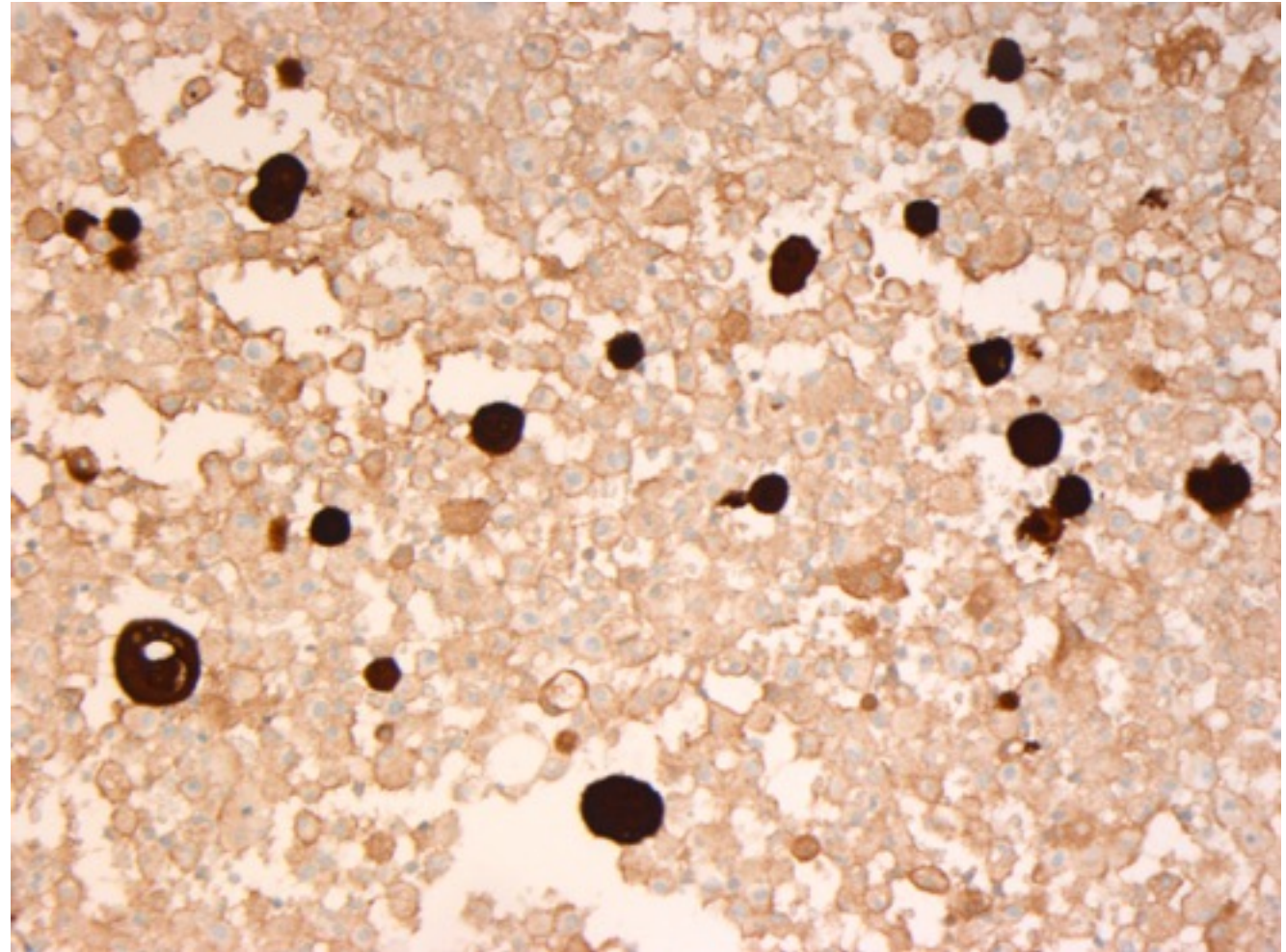
Koagel, cytokeratin x 40



Koagel, EMA x 40



Koagel, EP4 x 40



Koagel, Calretinin x 40