

**LBC**

# **Glandular Lesions: Diagnostic Pitfalls and Look a Likes 2**

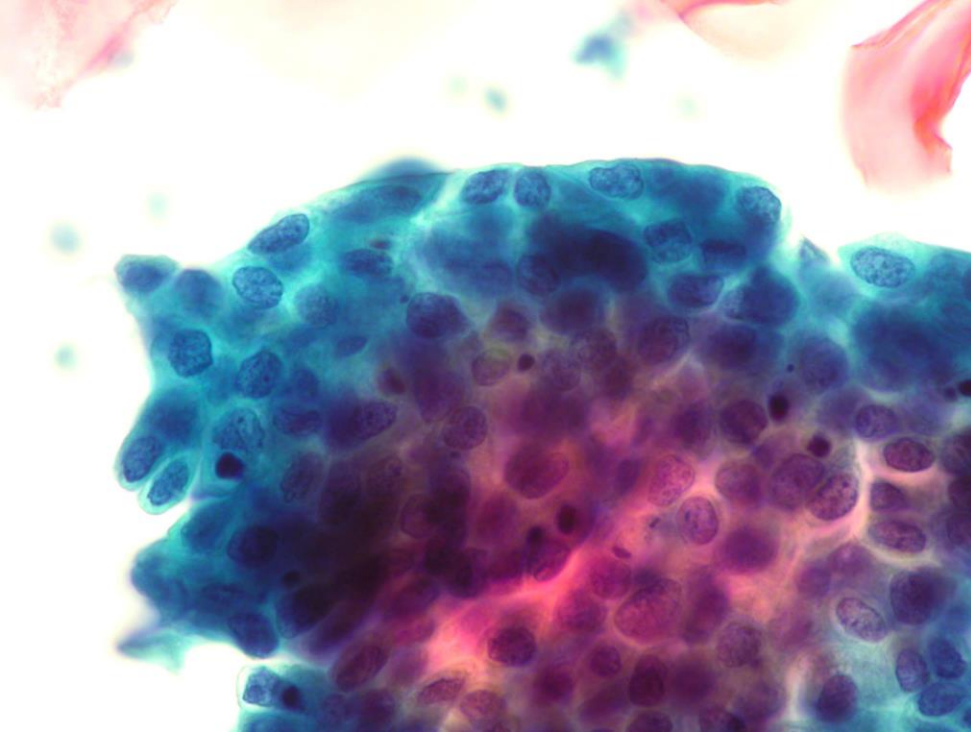
**Dr. Mina Desai**

**M.B.B.S;FRCPath; CBE**

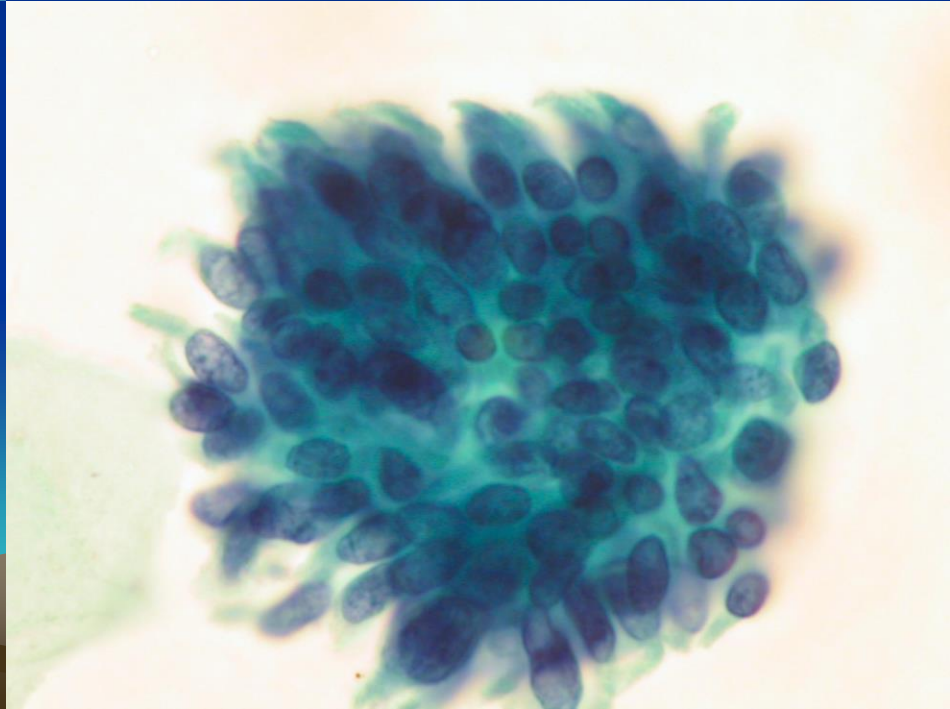
**Head of the Service/ Manchester Cytology Centre (2002-2013)**

**Director/ Manchester & Northwest Cytology Training Centre (2001-2013)**

**Past Chairman and President/ British Society For Clinical Cytology U.K.**

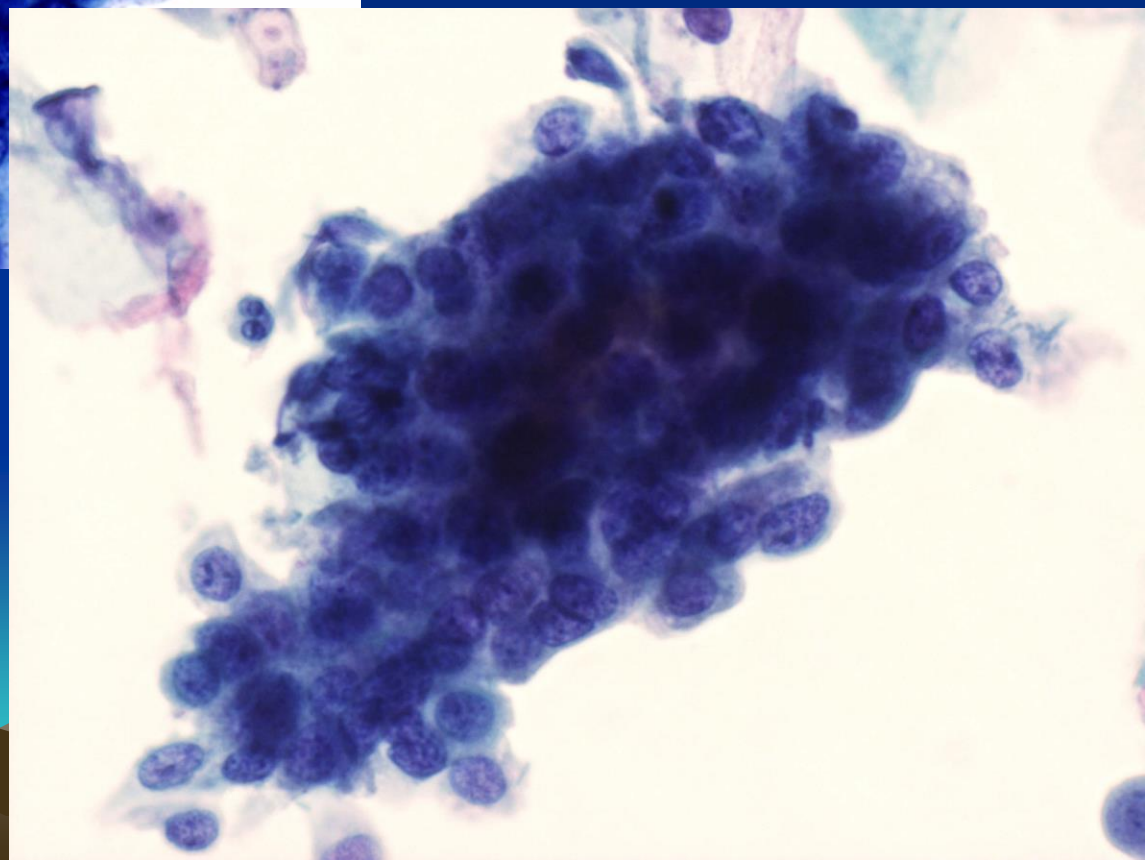


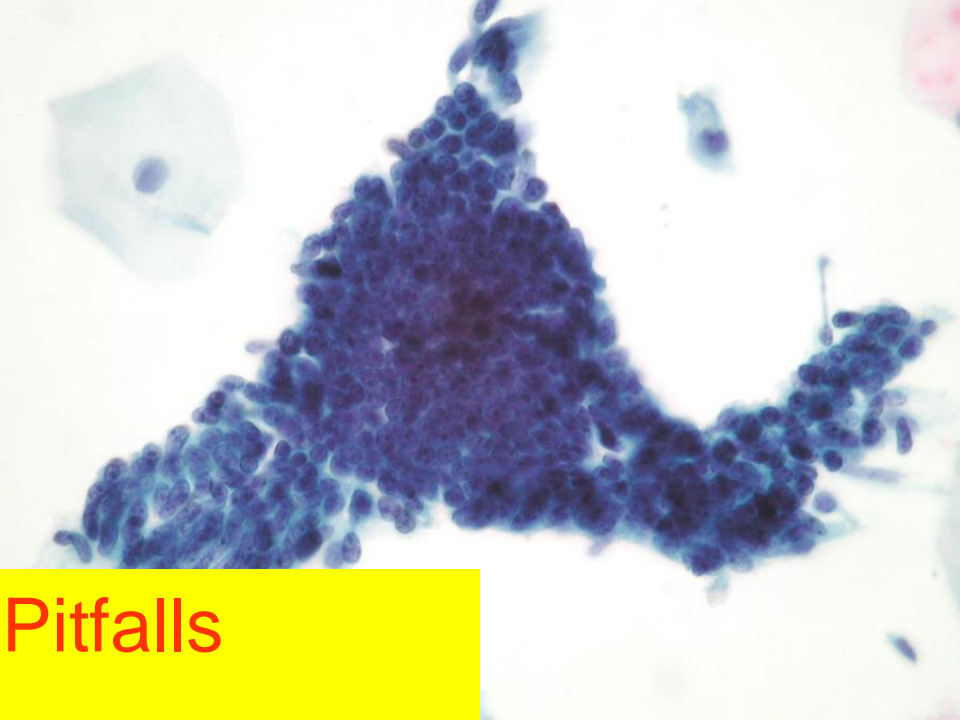
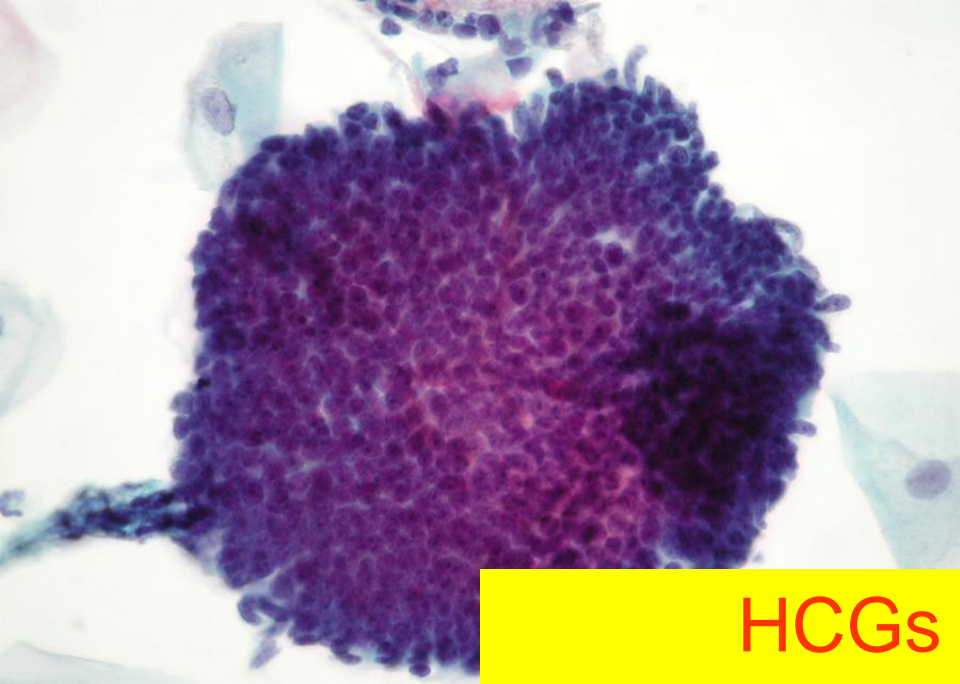
Spot the difference:  
Endocervical or  
squamous cells  
Normal or HSIL or AIS?





HCG Pitfalls  
Glandular or squamous  
Neg, HSIL or AIS?





HCGs Pitfalls  
Neg, HSIL or AIS?

