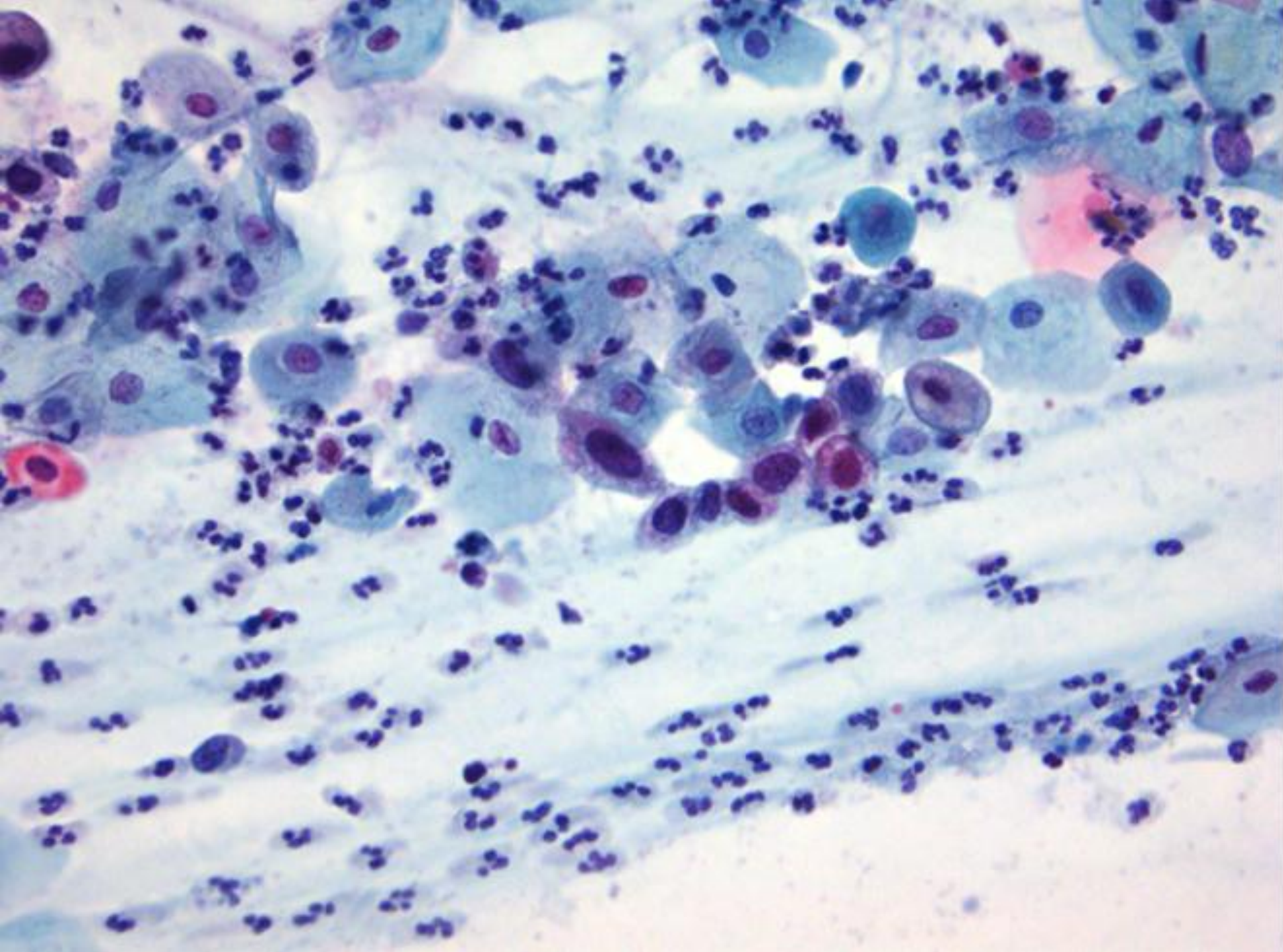
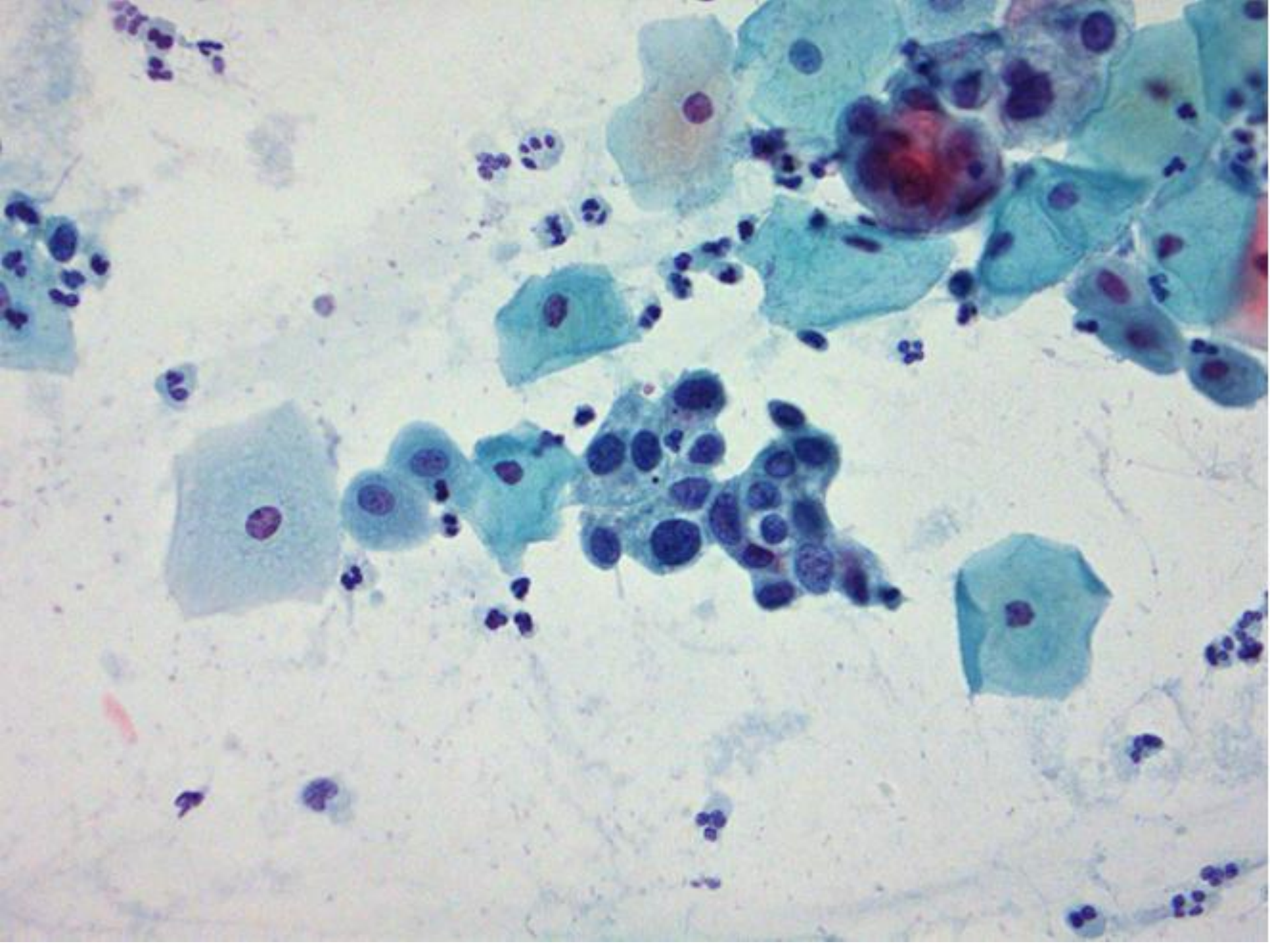
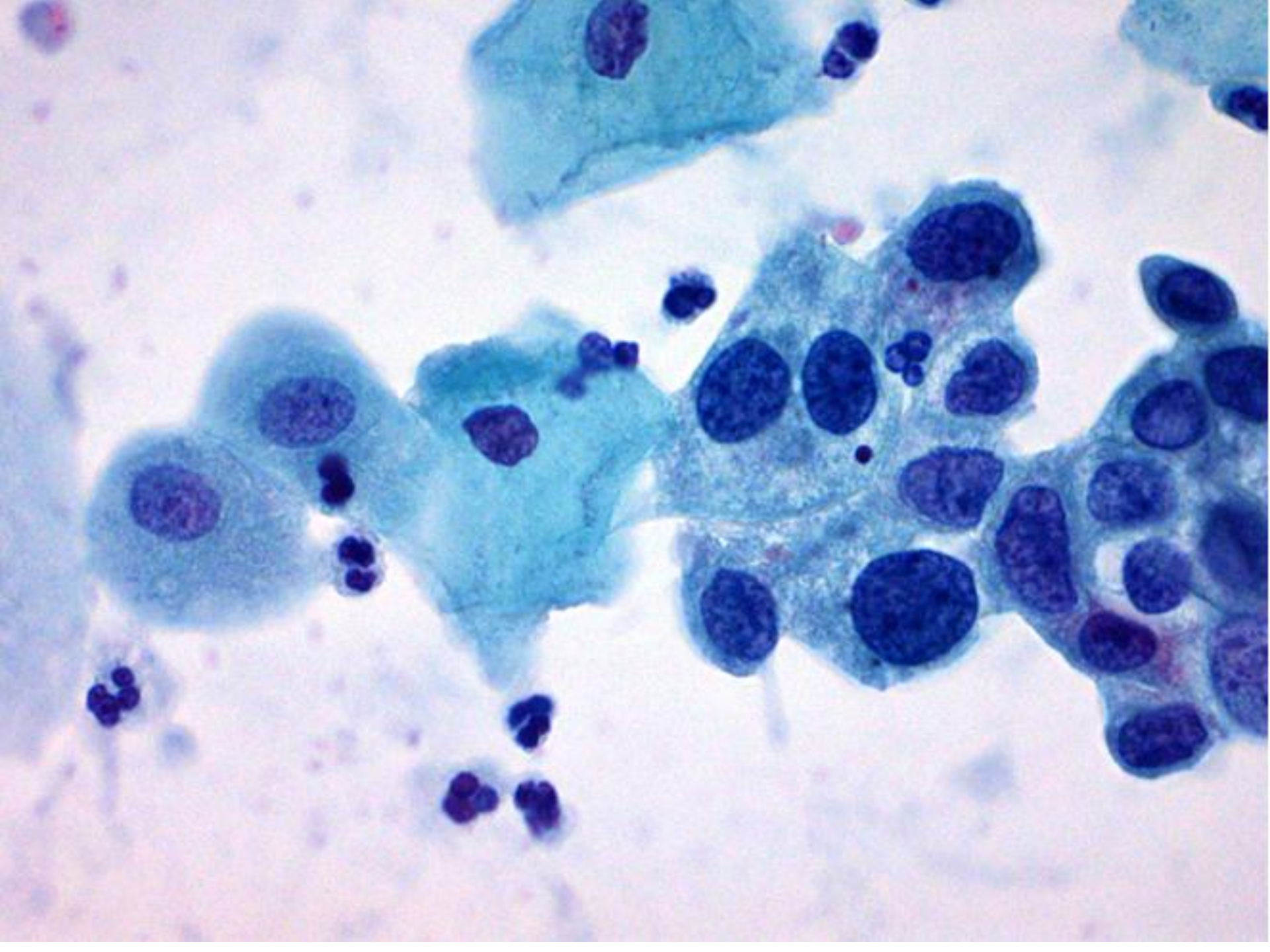


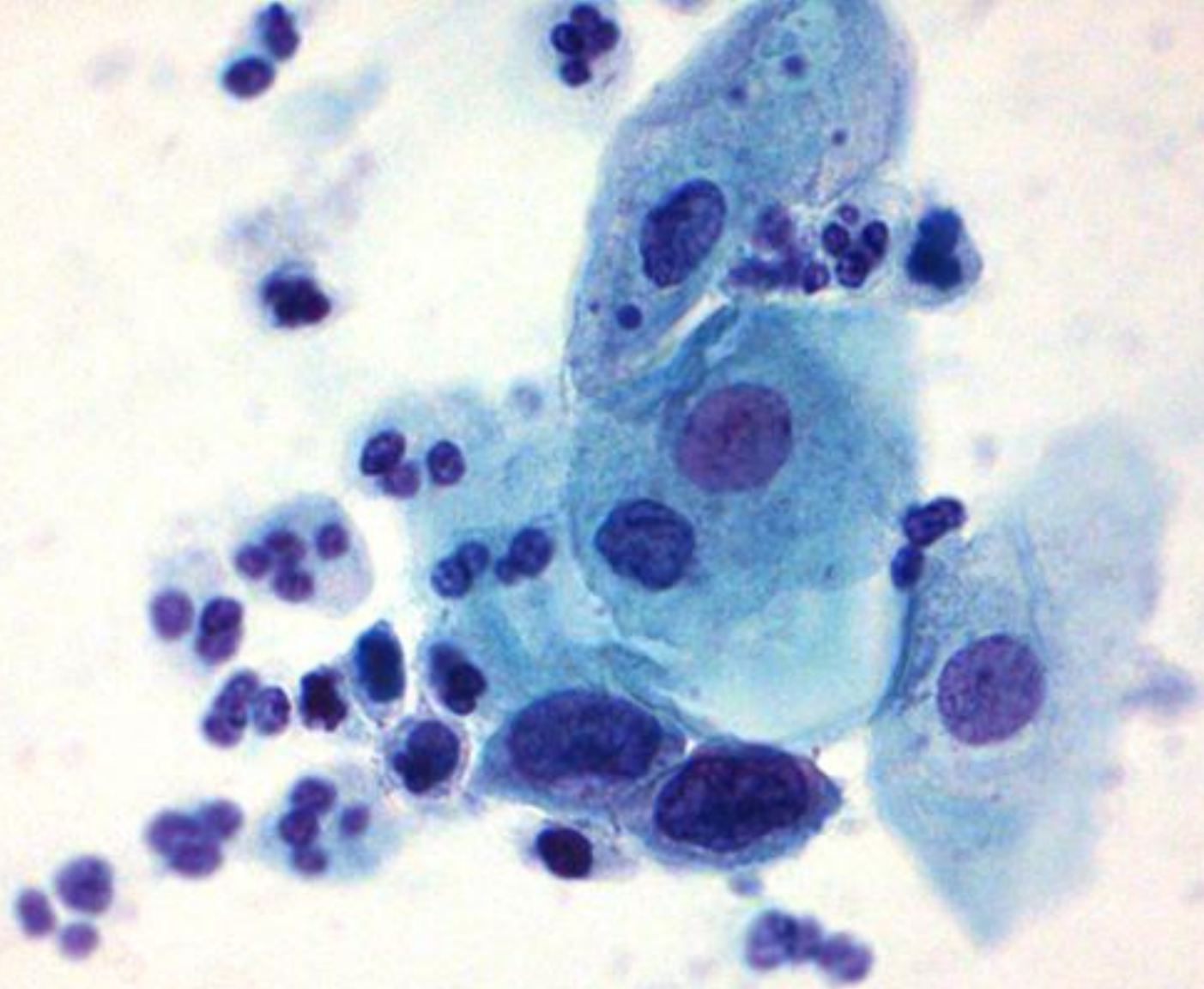
Case 4

24 år









Case 4, 24 årig Q, konushistologi: svær dysplasi

